

GUIDELINES ON PAEDIATRIC UROLOGY

S. Tekgül (co-chairman), H. Riedmiller (co-chairman),
E. Gerharz, P. Hoebeke, R. Kocvara, J.M. Nijman,
Chr. Radmayr, R. Stein

Introduction

The information provided presents a selection of the extended Guidelines on Paediatric Urology. The scope of the guidelines is such that no attempt has been made to include all the different topics, but rather to provide a selection based on practical considerations.

PHIMOSIS Background

At the end of the first year of life, retraction of the foreskin behind the glanular sulcus is possible in only about 50% of boys. The phimosis is either primary (physiological) with no sign of scarring, or secondary (pathological), resulting from scarring due to conditions such as balanitis xerotica obliterans.

Phimosis must be distinguished from normal agglutination of the foreskin to the glans, which is a physiological phenomenon. If the tip remains narrow and glanular adhesions were separated, then the space is filled with urine during voiding, causing the foreskin to balloon outward.

Treatment

Treatment of phimosis in children is dependent on the parents' preferences, and can be plastic or radical circumcision after completion of the second year of life. Plastic circumcision (dorsal incision, partial circumcision) carries the potential for recurrence of the phimosis. Associated frenulum breve is corrected by frenulotomy. Meatoplasty is added if necessary. Childhood circumcision should not be recommended without a medical reason.

Circumcision: indication and contraindication

An absolute indication for circumcision is secondary phimosis. The indications for early surgery in primary phimosis are recurrent balanoposthitis, and recurrent urinary tract infections in patients with urinary tract abnormalities. Routine neonatal circumcision to prevent penile carcinoma is not indicated.

Contraindications for circumcision are coagulopathy, an acute local infection and congenital anomalies of the penis, particularly hypospadias or buried penis, because the foreskin may be required for a reconstructive procedure.

Conservative treatment

As a conservative treatment option of the primary phimosis, a corticoid ointment or cream (0.05-0.10%) can be administered twice a day over a period of 20-30 days. This treatment has no side-effects. Agglutination of the foreskin does not respond to steroid treatment.

Paraphimosis

Paraphimosis must be regarded as an emergency situation. It is characterised by retracted foreskin with the constrictive ring localised at the level of the sulcus. Treatment of paraphimosis consists of manual compression of the oedematous tissue with a subsequent attempt to retract the tightened foreskin over the glans penis. A dorsal incision of the constrictive ring may be required, or circumcision is carried out immediately or in a second session.

CRYPTORCHIDISM

Background

Almost 1% of all full-term male infants are affected at the age of one year. Categorisation into palpable and non-palpable testis seems to be most the appropriate method.

In cases of bilateral non-palpable testes and any suggestion of sexual differentiation problems, urgent endocrinological and genetic evaluation is mandatory.

Assessment

A physical examination is the only method of differentiating between palpable or non-palpable testes. There is no additional benefit in performing any imaging.

There is no reliable examination to confirm or rule out an intra-abdominal, inguinal and absent/vanishing testis (non-palpable testis), except for diagnostic laparoscopy.

Treatment

To prevent histological deterioration, treatment should be undertaken and completed before the age of 12-18 months.

Medical therapy

Medical therapy using human chorionic gonadotrophin (hCG) or gonadotrophin-releasing hormone (GnRH) is based on the hormonal dependence of testicular descent, with success rates of a maximum of 20%.

However, medical treatment can be beneficial before or after surgical orchidolysis and orchidopexy to increase the fertility index, although long-term follow-up data are lacking.

Surgery

Palpable testis: Surgery for the palpable testis includes orchidofuniculolysis and orchidopexy, with success rates of up to 92%.

Non-palpable testis: Inguinal surgical exploration with the possibility of performing laparoscopy should be attempted. In rare cases, it is necessary to search into the abdomen if there are no vessels or vas deferens in the groin. Laparoscopy is the most appropriate way of examining the abdomen for a testis.

An intra-abdominal testis in a boy aged 10 years or older with a normal contralateral testis should be removed. In bilateral intra-abdominal testes, or in a boy younger than 10 years, a one-stage or two-stage Fowler-Stephens procedure can be executed. Microvascular autotransplantation is also an option, with 90% testicular survival rate.

Prognosis

Boys with one undescended testis have a lower fertility rate, but the same paternity rate. Boys with bilateral undescended testes have a lower fertility and paternity rate.

Boys with an undescended testis have a higher chance of

developing testicular cancer, but recent studies concluded that early orchiopexy may indeed reduce the risk of developing testicular cancer.

It is recommended that surgical orchidolysis and orchidopexy be performed by the age of 12-18 months, at the latest. To date, it seems that pre- or post-operative hormonal treatment may have a beneficial effect on fertility in later life.

HYDROCELE

Background

Incomplete obliteration of the processus vaginalis peritonei results in formation of various types of communicating hydrocele, alone or connected with other intrascrotal pathology (hernia). It persists in approximately 80-94% of newborns and in 20% of adults.

Non-communicating hydroceles are found secondary to minor trauma, testicular torsion, epididymitis, or varicocele operation, or may appear as a recurrence after primary repair of a communicating hydrocele.

A communicating hydrocele vacillates in size, usually relative to activity. It may be diagnosed by history and physical investigation, the swelling is translucent, and transillumination of the scrotum makes the diagnosis. If there are any doubts about the intrascrotal mass, ultrasound should be performed. The question of contralateral disease should be addressed.

Treatment - Surgery

Surgical treatment of hydrocele is not indicated within the

first 12-24 months because of the tendency for spontaneous resolution. Early surgery is indicated if there is suspicion of a concomitant inguinal hernia or underlying testicular pathology. There is no evidence that this type of hydrocele risks testicular damage.

In the paediatric age group, the operation consists of ligation of the patent processus vaginalis via an inguinal incision, leaving the distal stump open, whereas in hydrocele of the cord, the cystic mass is excised or unroofed. Sclerosing agents should not be used because of the risk of chemical peritonitis in the communicating processus vaginalis peritonei.

The scrotal approach (Lord or Jaboulay technique) is used in the treatment of a secondary non-communicating hydrocele.

HYPOSPADIAS

Background

Hypospadias are usually classified according to the anatomical location of the proximally displaced urethral orifice:

- distal - anterior hypospadias (glanular, coronal or distal penile)
- intermediate - middle (penile)
- proximal - posterior (penoscrotal, scrotal, perineal).

The pathology may be much more severe after skin release.

Assessment

Patients with hypospadias should be diagnosed at birth. The diagnostic evaluation also includes an assessment of associated anomalies, which are cryptorchidism and open processus vaginalis or inguinal hernia. The incidence of anomalies of the upper urinary tract does not differ from the general population, except in very severe forms of hypospadias.

Severe hypospadias with unilaterally or bilaterally impalpable testis, or with ambiguous genitalia, require a complete genetic and endocrine work-up immediately after birth to exclude intersexuality, especially congenital adrenal hyperplasia.

Trickling urine and ballooning of the urethra require exclusion of meatal stenosis.

The length of the hypospadiac penis may be distorted by penile curvature, by penoscrotal transposition, or may be smaller due to hypogonadism. Micropenis is defined as a small but otherwise normally formed penis with a stretched length of less than 2.5 cm \pm SD below the mean (Table 1).

Table 1: Length of the penis in boys
(according to Feldmann and Smith)

Age	Mean \pm SD (cm)
Newborns	3.5 \pm 0.4
0-5 months	3.9 \pm 0.8
6-12 months	4.3 \pm 0.8
1-2 y	4.7 \pm 0.8
2-3 y	5.1 \pm 0.9
3-4 y	5.5 \pm 0.9
4-5 y	5.7 \pm 0.9
5-6 y	6.0 \pm 0.9
6-7 y	6.1 \pm 0.9
7-8 y	6.2 \pm 1.0
8-9 y	6.3 \pm 1.0
9-10 y	6.3 \pm 1.0
10-11 y	6.4 \pm 1.1
Adults	13.3 \pm 1.6

Differentiation between functionally necessary and aesthetically feasible operative procedures is important for therapeutic decision-making. As all surgical procedures carry the risk of complications, thorough pre-operative counselling of the parents is crucial. The therapeutic objectives are to correct the penile curvature, to form a neo-urethra of an adequate size, to bring the neomeatus to the tip of the glans, if possible, and to achieve an overall acceptable cosmetic appearance. This goal is achieved by using different surgical techniques according to the individual findings.

Surgery

The age at surgery for primary hypospadias repair is usually 6-18 months. For repeat hypospadias repairs, no definitive guidelines can be given.

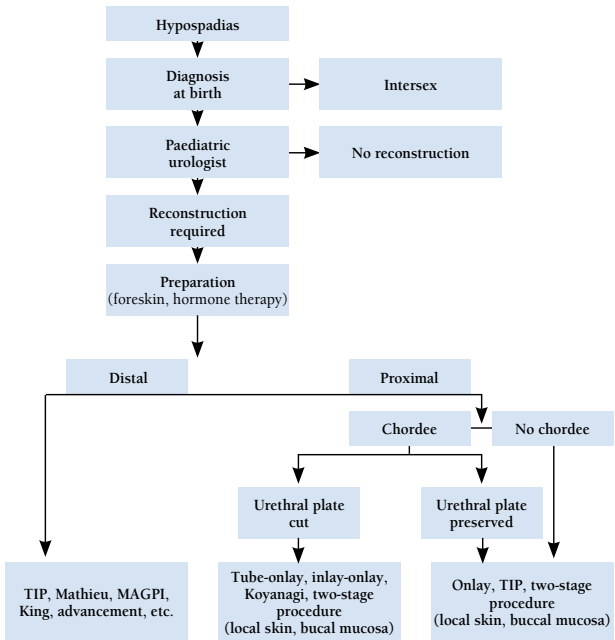
Outcome

Excellent long-term functional and cosmetic results can be achieved after repair of anterior penile hypospadias. The complication rate in proximal hypospadias repair is higher.

Adolescents who underwent hypospadias repair in childhood have a slightly higher rate of dissatisfaction with penile size, but their sexual behaviour is no different from that of controls.

Figure 1 gives an algorithm for the management of hypospadias.

Figure 1: Algorithm for the management of hypospadias



TIP = tubularised incised plate; MAGPI = meatal advancement and glanuloplasty technique.

VARICOCELE IN CHILDREN AND ADOLESCENTS

Background

This is unusual in boys under 10 years of age, but becomes more frequent at the beginning of puberty. Fertility problems will arise in about 20% of adolescents with varicocele.

The adverse influence of varicocele increases with time.

Testicular catch-up growth and improvement in sperm parameters after varicocelectomy has been reported in adolescents. Varicocele is mostly asymptomatic, rarely causing pain at this age. It may be noticed by the patient or parents, or discovered by the paediatrician at a routine visit. The diagnosis and classification depends upon the clinical finding and ultrasound investigation.

Treatment

Surgery

Surgical intervention is based on ligation or occlusion of the internal spermatic veins. Microsurgical lymphatic-sparing repair (microscopic or laparoscopic) are associated with the lowest recurrence and complication rate. There is no evidence that the treatment of varicocele at paediatric age will offer a better andrological outcome than an operation performed later. The limited indication criteria for varicocelectomy at this age should therefore be adhered to.

Follow-up

During adolescence, testicular size should be checked annually. After adolescence, repeated sperm analysis is to be recommended.

Figure 2 shows an algorithm for the diagnosis of varicocele in children and adolescents, and Figure 3 shows an algorithm for its treatment.

Figure 2: Algorithm for the diagnosis of varicocele in children and adolescents

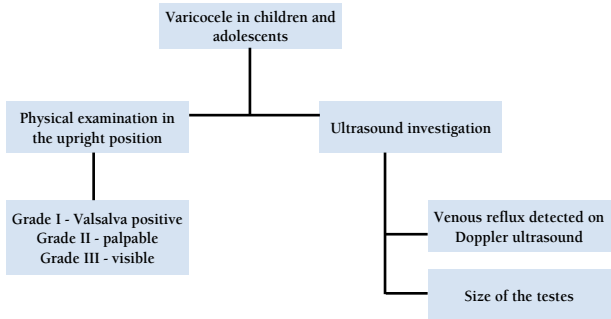
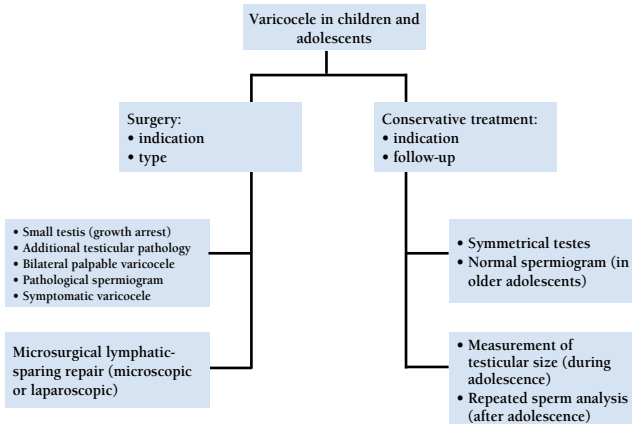


Figure 3: Algorithm for the treatment of varicocele in children and adolescents



MONOSYMPOMATIC NOCTURNAL ENURESIS

Background

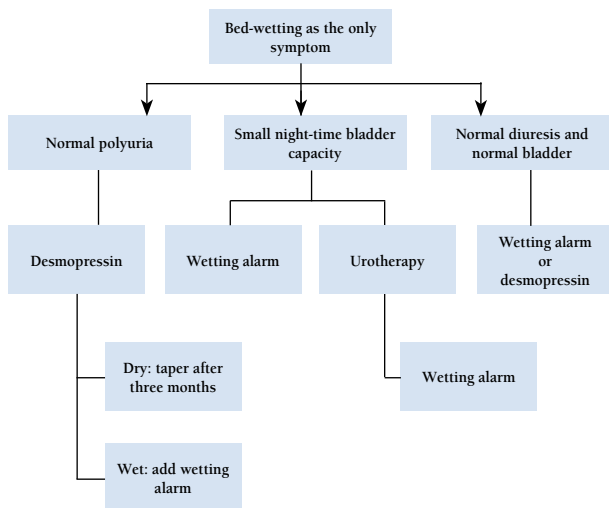
Enuresis is incontinence during the night. Any wetting during sleep above the age of five years is enuresis. It is important to note that there is a single symptom only. Due to an imbalance between night-time urine output and night-time bladder capacity, the bladder can easily become full at night, and the child will either wake up to empty the bladder or will void during sleep if there is a lack of arousal from sleep.

Assessment

A voiding diary, registering the daytime bladder function and the night-time urine output will help to guide the treatment. Weighing nappies (diapers) in the morning and adding the volume of the morning void gives an estimate of night-time urine production. Measuring the daytime bladder capacity gives an estimate of bladder capacity to compare with normal values for age.

Figure 4 gives an algorithm for the diagnosis and treatment of monosymptomatic nocturnal enuresis.

Figure 4: Algorithm for the diagnosis and treatment of monosymptomatic nocturnal enuresis



This short text is based on the more comprehensive EAU/ESPU Paediatric Urology Guidelines (ISBN 978-90-79754-09-0), available at their website: www.uroweb.org