

# Guidelines on **Testicular Cancer**

P. Albers (chairman), W. Albrecht, F. Algaba,  
C. Bokemeyer, G. Cohn-Cedermark, K. Fizazi,  
A. Horwich, M.P. Laguna

# TABLE OF CONTENTS

# PAGE

1	BACKGROUND	4
	1.1 Methods	4
2	PATHOLOGICAL CLASSIFICATION	5
3	DIAGNOSIS	5
	3.1 Clinical examination	5
	3.2 Imaging of the testis	5
	3.3 Serum tumour markers at diagnosis	6
	3.4 Inguinal exploration and orchidectomy	6
	3.5 Organ-sparing surgery	6
	3.6 Pathological examination of the testis	6
	3.7 Diagnosis and treatment of carcinoma in situ (Tin)	7
	3.8 Screening	7
4	STAGING	7
	4.1 Diagnostic tools	7
	4.2 Serum tumour markers: post-orchidectomy half-life kinetics	8
	4.3 Retroperitoneal, mediastinal and supraclavicular lymph nodes and viscera	8
	4.4 Staging and prognostic classifications	9
	4.5 Prognostic risk factors	11
5	IMPACT ON FERTILITY AND FERTILITY-ASSOCIATED ISSUES	11
6	GUIDELINES ON DIAGNOSIS AND STAGING OF TESTICULAR CANCER	12
7	TREATMENT: STAGE I GERM CELL TUMOURS	12
	7.1 Stage I seminoma	12
	7.1.1 Surveillance	12
	7.1.2 Adjuvant chemotherapy	12
	7.1.3 Adjuvant radiotherapy	12
	7.1.4 Retroperitoneal lymph node dissection (RPLND)	13
	7.1.5 Risk-adapted treatment	13
	7.2 Guidelines for the treatment of seminoma stage I	13
	7.3 NSGCT stage I	13
	7.3.1 Surveillance	13
	7.3.2 Primary chemotherapy	14
	7.3.3 Risk-adapted treatment	14
	7.3.4 Retroperitoneal lymph node dissection	14
	7.4 CS1S with (persistently) elevated serum tumour markers	15
	7.5 Guidelines for the treatment of NSGCT stage I	15
8	TREATMENT: METASTATIC GERM CELL TUMOURS	17
	8.1 Low-volume metastatic disease (stage IIA/B)	17
	8.1.1 Stage IIA/B seminoma	17
	8.1.2 Stage IIA/B non-seminoma	17
	8.2 Advanced metastatic disease	18
	8.2.1 Primary chemotherapy	18
	8.3 Restaging and further treatment	19
	8.3.1 Restaging	19
	8.3.2 Residual tumour resection	19
	8.3.3 Consolidation chemotherapy after secondary surgery	19
	8.4 Systemic salvage treatment for relapse or refractory disease	20
	8.4.1 Seminoma	20
	8.4.2 Non-seminoma	20
	8.4.3 Late relapse ( $\geq$ 2 years after end of first-line treatment)	21
	8.5 Salvage surgery	21
	8.6 Treatment of brain metastases	21

8.7	Guidelines for the treatment of metastatic germ cell tumours	21
9	FOLLOW-UP AFTER CURATIVE THERAPY	22
9.1	General considerations	22
9.2	Follow-up: stage I non-seminoma	22
9.2.1	Follow-up investigations during surveillance	22
9.2.2	Follow-up after nerve-sparing RPLND	23
9.2.3	Follow-up after adjuvant chemotherapy	23
9.3	Follow-up: stage I seminoma	23
9.3.1	Follow-up after radiotherapy	24
9.3.2	Follow-up during surveillance	24
9.3.3	Follow-up after adjuvant chemotherapy	24
9.4	Follow-up: stage II and advanced (metastatic) disease	24
10	TESTICULAR STROMAL TUMOURS	25
10.1	Background	25
10.2	Methods	25
10.3	Classification	25
10.4	Leydig cell tumours	26
10.4.1	Epidemiology	26
10.4.2	Pathology of Leydig cell tumours	26
10.4.3	Diagnosis	26
10.4.4	Treatment	26
10.4.5	Follow-up	27
10.5	Sertoli cell tumour	27
10.5.1	Epidemiology	27
10.5.2	Pathology of Sertoli cell tumours	27
10.5.2.1	Classification	27
10.5.3	Diagnosis	27
10.5.4	Treatment	28
10.5.5	Follow-up	28
10.6	Granulosa cell tumour	28
10.7	Thecoma/fibroma group of tumours	28
10.8	Other sex cord/gonadal stromal tumours	28
10.9	Tumours containing germ cell and sex cord/gonadal stromal (gonadoblastoma)	28
10.10	Miscellaneous tumours of the testis	28
10.10.1	Tumours of ovarian epithelial types	28
10.10.2	Tumours of the collecting ducts and rete testis	28
10.10.3	Tumours (benign and malignant) of non-specific stroma	29
11.	REFERENCES	29
11.1	Germ cell tumours	29
11.2	Non-germ cell tumours	48
12.	ABBREVIATIONS USED IN THE TEXT	50

# 1. BACKGROUND

Testicular cancer represents between 1% and 1.5% of male neoplasms and 5% of urological tumours in general, with 3-6 new cases occurring per 100,000 males/per year in Western society (1, 2). An increase in the incidence of testicular cancer was detected during the 1970s and 1980s, particularly in Northern European countries, and there is a clear trend towards an increased testicular cancer incidence in the last 30 years in the majority of the industrialised countries in North America, Europe and Oceania, although surprising differences in incidence rates are seen between neighbouring countries (3). Data from the Surveillance Epidemiology and End Results Program during the years 1973 to 1998 show a continuing increased risk among Caucasian men in the USA only for seminoma (4).

Only 1-2% of cases are bilateral at diagnosis. The histological type varies, although there is a clear predominance (90-95%) of germ cell tumours (1). Peak incidence is in the third decade of life for non-seminoma, and in the fourth decade for pure seminoma. Familial clustering has been observed, particularly among siblings (5).

Genetic changes have been described in patients with testicular cancer. A specific genetic marker (an isochromosome of the short arm of chromosome 12 – i(12p) – has been described in all histological types of germ cell tumours (5). Intratubular germ cell neoplasia (testicular intraepithelial neoplasia, Tin) shows the same chromosomal changes, and alterations in the p53 locus have been found in 66% of cases of testicular Tin (6). A deregulation in the pluripotent programme of fetal germ cells (identified by specific markers such as M2A, C-KIT and OCT4/NANOG) is probably responsible for the development of Tin and germ cell neoplasia. There is overlap in the development to seminoma and embryonal carcinoma as shown by genome-wide expression analysis and detection of alpha-fetoprotein (AFP) mRNA in some atypical seminoma (7, 8).

Epidemiological risk factors for the development of testicular tumours are: a history of cryptorchidism or undescended testis, Klinefelter's syndrome, familial history of testicular tumours among first-grade relatives (father/brothers), the presence of a contralateral tumour or Tin, and infertility (9-14). Tallness was associated with a risk of germ cell cancer, although further confirmation is needed (15).

Testicular tumours show excellent cure rates. The main factors contributing to this are: careful staging at the time of diagnosis; adequate early treatment based on chemotherapeutic combinations, with or without radiotherapy and surgery; and very strict follow-up and salvage therapies. In the past decade, a decrease in the mean time delay to diagnosis and treatment has been observed (16). In the treatment of testicular cancer, the choice of centre where this treatment is going to be administered is of utmost importance. Although early stages can be successfully treated in a non-reference centre, the relapse rate is higher (17). In poor prognosis non-seminomatous germ cell tumours, it has been shown that overall survival within a clinical trial depended on the number of patients treated at the participating centre (worse < 5 patients enrolled) (18).

## 1.1 Methods

These guidelines represent implementation of previously published texts: the latest EAU guidelines were formally published as a review paper in 2005 (19) and as an EAU guideline, which was distributed among EAU members, in March 2006. As in 2006, this edition contains a separate chapter on testicular stromal tumours. A multidisciplinary team of urologists, medical oncologists, radiotherapists and a pathologist were involved in producing this text, which is based on a non-structured review of the literature through to October 2007 in the case of both the germ cell tumour and non-germ cell parts. Also, data from meta-analysis studies, Cochrane evidence, and the recommendations of the European Germ Cell Cancer Collaborative Group Meeting in Amsterdam in November 2006, as well as other available guidelines, have been included (20-27).

Whenever possible, references have been labelled according to the principles of evidence-based medicine (EBM) (28). The nature of the recommendations in these guidelines is labelled according to the level of evidence (28).

## 2. PATHOLOGICAL CLASSIFICATION

The recommended pathological classification (modified from the 2004 version of the World Health Organization [WHO] guidance) is shown below (29).

### 1. Germ cell tumours

- Intratubular germ cell neoplasia
- Seminoma (including cases with syncytiotrophoblastic cells)
- Spermatocytic seminoma (mention if there is sarcomatous component)
- Embryonal carcinoma
- Yolk sac tumour
- Choriocarcinoma
- Teratoma (mature, immature, with malignant component)
- Tumours with more than one histological type (specify percentage of individual components).

### 2. Sex cord/gonadal stromal tumours

- Leydig cell tumour
- Malignant Leydig cell tumour
- Sertoli cell tumour
  - lipid-rich variant
  - sclerosing
  - large cell calcifying
- Malignant Sertoli cell tumour
- Granulosa cell tumour
  - adult type
  - juvenile type
- Thecoma/fibroma group of tumours
- Other sex cord/gonadal stromal tumours
  - incompletely differentiated
  - mixed
- Tumours containing germ cell and sex cord/gonadal stromal (gonadoblastoma).

### 3. Miscellaneous non-specific stromal tumours

- Ovarian epithelial tumours
- Tumours of the collecting ducts and rete testis
- Tumours (benign and malignant) of non-specific stroma

## 3. DIAGNOSIS

### 3.1 Clinical examination

Testicular cancer generally affects young men in the third or fourth decade of life. It normally appears as a painless, unilateral mass in the scrotum or the casual finding of an intrascrotal mass (30). In approximately 20% of cases, the first symptom is scrotal pain, and up to 27% of patients with testicular cancer may have local pain (1).

Occasionally, trauma to the scrotum may reveal the presence of a testicular mass. Gynaecomastia appears in 7% of cases and is more common in non-seminomatous tumours. Back and flank pain are present in about 11% of cases (16). Reduction in testis size can precede a testicular tumour (31).

In about 10% of cases, a testicular tumour can mimic an orchioepididymitis, with consequent delay of the correct diagnosis (1, 2). Ultrasound must be performed in any doubtful case. Physical examination reveals the features of the mass and must always be carried out in conjunction with a general examination in order to find possible (supraclavicular) distant metastases, a palpable abdominal mass or gynaecomastia. A correct diagnosis must be established in all patients with an intrascrotal mass (32).

### 3.2 Imaging of the testis

Currently, diagnostic ultrasound serves to confirm the presence of a testicular mass and to explore the

contralateral testis. Its sensitivity in detecting a testicular tumour is almost 100%, and it has an important role in determining whether a mass is intra- or extratesticular (33). Ultrasound is an inexpensive test, but it is unnecessary when the presence of a testicular tumour is clinically evident (34). Ultrasound of the testis has to be performed in young men without a palpable testicular mass who have retroperitoneal or visceral masses or elevated serum human chorionic gonadotrophin (hCG) or AFP (35-38). Ultrasound is recommended in the follow-up of the contralateral testis in the follow-up of patients at risk (39).

Magnetic resonance imaging (MRI) offers higher sensitivity and specificity than ultrasound for diagnosing tumours (40-42) and may be able to differentiate seminomatous from non-seminomatous tumours.

MRI of the scrotum offers a sensitivity of 100% and a specificity of 95-100% (43), but its high cost does not justify its use for diagnosis.

### **3.3 Serum tumour markers at diagnosis**

Serum tumour markers are prognostic factors and contribute to diagnosis and staging (44). The following markers should be determined:

- AFP (produced by yolk sac cells)
- hCG (expression of trophoblasts).

Lactate dehydrogenase (LDH) (marker of tissue destruction) is recommended for patients with metastatic disease. Globally, there is an increase in these markers in 51% of cases of testicular cancer (16, 30). Alpha-fetoprotein increases in 50-70% of patients with non-seminomatous germ cell tumour (NSGCT), and a rise in hCG is seen in 40-60% of patients with NSGCT. About 90% of non-seminomatous tumours present with a rise in one or two of the markers. Up to 30% of seminomas can present or develop an elevated hCG level during the course of the disease (45, 46).

LDH is a less specific marker, and its concentration is proportional to tumour volume. Its level may be elevated in 80% of patients with advanced testicular cancer (45). It should be noted that negative marker levels do not exclude the diagnosis of a germ cell tumour. Other markers studied include placental alkaline phosphatase (PLAP), which may be of value in monitoring patients with pure seminoma. Cytogenetic and molecular markers are available in specific centres, but at present only contribute to research studies. Measurement of serum AFP, hCG and LDH (in advanced tumours) is mandatory, while that of PLAP is optional.

### **3.4 Inguinal exploration and orchidectomy**

Every patient with a suspected testicular mass must undergo inguinal exploration with exteriorisation of the testis within its tunics. Immediate orchidectomy with division of the spermatic cord at the internal inguinal ring must be performed if a tumour is found. If the diagnosis is not clear, a testicular biopsy is taken for frozen section histological examination.

In cases of disseminated disease and life-threatening metastases, it is current practice to start with up-front chemotherapy, and orchidectomy may be delayed until clinical stabilisation has occurred.

### **3.5 Organ-sparing surgery**

Although organ-sparing surgery is not indicated in the presence of non-tumoural contralateral testis, it can be attempted in special cases with all the necessary precautions.

In synchronous bilateral testicular tumours, metachronous contralateral tumours, or in a tumour in a solitary testis with normal pre-operative testosterone levels, organ preserving surgery can be performed when the tumour volume is less than 30% of the testicular volume and surgical rules are respected. In those cases, the rate of associated Tin is high (at least up to 82%), and all patients must be treated with adjuvant radiotherapy (20 Gy) at some point (47).

Infertility will result after radiotherapy and the risk of long-term Leydig cell insufficiency after radiotherapy of a solitary testis is increased (48). Radiation treatment may be delayed in fertile patients who wish to father children. The option must be carefully discussed with the patient and surgery performed in a centre with experience (49, 50).

### **3.6 Pathological examination of the testis**

Mandatory pathological requirements:

- Macroscopic features: side, testis size, maximum tumour size and macroscopic features of epididymis, spermatic cord and tunica vaginalis.

- Sampling: a 1 cm<sup>2</sup> section for every centimetre of maximum tumour diameter, including normal macroscopic parenchyma (if present), albuginea and epididymis, with selection of suspected areas. At least one proximal and one distal section of spermatic cord plus any suspected area.
- Microscopic features and diagnosis: histological type (specify individual components and estimate amount as percentage) according to WHO 2004 (29):
  - presence or absence of peri-tumoural venous and/or lymphatic invasion
  - presence or absence of albuginea, tunica vaginalis, rete testis, epididymis or spermatic cord invasion
  - presence or absence of intratubular germ cell neoplasia (Tin) in non-tumour parenchyma intratubular germ cell neoplasia
- pT category according to Tumour Node Metastasis (TNM) 2002
- Immunohistochemical studies: in seminoma and mixed germ cell tumour, AFP and hCG.

Advisable immunohistochemical markers, in cases of doubt, are:

- in seminoma: cytokeratins (CAM 5.2), PLAP, c-kit
- in intratubular germ cell neoplasia: PLAP, c-kit
- other advisable markers: chromogranine A (Cg A), Ki-1 (MIB-1).

### 3.7 Diagnosis and treatment of carcinoma in situ (Tin)

Contralateral biopsy has been advocated to rule out the presence of Tin (51). Although this is routine policy in some countries, the low incidence of Tin and contralateral metachronous testicular tumours (up to 9% and approximately 2.5%, respectively) (52, 53), the morbidity of Tin treatment, and the fact that most of these metachronous tumours are at a low stage at presentation make it controversial to recommend a systematic contralateral biopsy in all patients (54–56). It is still difficult to reach a consensus on whether the existence of contralateral Tin must be identified in all cases. However, biopsy of the contralateral testis should be offered to high-risk patients for contralateral Tin with a testicular volume of less than 12 mL, a history of cryptorchidism, or poor spermatogenesis (Johnson Score 1–3). A contralateral biopsy is not necessary for patients older than 40 years (57–62). A double biopsy is preferred to increase sensitivity.

Once Tin is diagnosed, local radiotherapy (20 Gy in single fractions of 2 Gy) is the treatment of choice. Because this may produce infertility, the patient must be carefully counselled before treatment commences (54, 63). In addition to infertility, Leydig cell function and testosterone production may be impaired long-term following radiotherapy for Tin (49). Radiation treatment may be delayed in fertile patients who wish to father children (59).

### 3.8 Screening

Although there are no surveys proving the advantages of screening programmes, it has been demonstrated that stage and prognosis are directly related to early diagnosis. In the presence of clinical risk factors, self-physical examination by the affected individual is advisable.

## 4. STAGING

To determine the presence of metastatic or occult disease, the half-life kinetics of serum tumour markers must be assessed, the nodal pathway must be screened, and the presence of visceral metastases ruled out.

Consequently, it is mandatory to assess:

- the post-orchidectomy half-life kinetics of serum tumour markers
- the status of retroperitoneal and supraclavicular lymph nodes, and the liver
- the presence or absence of mediastinal nodal involvement and lung metastases
- the status of brain and bone, if any suspicious symptoms are present.

### 4.1 Diagnostic tools

The currently available tests include:

- serial blood sampling
- chest X-ray
- abdominopelvic and thoracic computed tomography (CT) scan
- abdominal and retroperitoneal ultrasound
- MRI

- positron emission tomography (PET) scan
- other specific examinations, depending on clinical suspicion.

#### 4.2 Serum tumour markers: post-orchidectomy half-life kinetics

The mean serum half-life of AFP and hCG is 5-7 days and 2-3 days, respectively (45). Tumour markers have to be re-evaluated after orchidectomy to determine half-life kinetics. Marker decline in patients with clinical stage I disease should be assessed until normalisation has occurred. Post-orchidectomy markers are important to classify the patient according to the International Germ Cell Cancer Collaborative Group (IGCCCG) risk classification. The persistence of elevated serum tumour markers after orchidectomy might indicate the presence of metastatic disease (macro- or microscopically), while the normalisation of marker levels after orchidectomy does not rule out the presence of tumour metastases. During chemotherapy, the markers should decline; persistence has an adverse prognostic value.

#### 4.3 Retroperitoneal, mediastinal and supraclavicular lymph nodes and viscera

Retroperitoneal and mediastinal lymph nodes are best assessed by means of a CT scan. The supraclavicular nodes are best assessed by physical examination.

Abdominopelvic CT scanning offers a sensitivity of 70-80% in determining the state of the retroperitoneal nodes. Its accuracy depends on the size of the nodes; sensitivity and the negative predictive value increase using a 3 mm threshold to define metastatic nodes in the landing zones (62). Those figures decrease slightly in stages I and II (63, 64), with a rate of understaging of 25-30% (65). New generations of CT scans do not seem to improve the sensitivity.

Magnetic resonance imaging produces similar results to CT scanning in the detection of retroperitoneal nodal enlargement (66). Again, the main objections to its routine use are its high cost and limited access to it. Nevertheless, MRI can be helpful when abdominopelvic CT or ultrasound are inconclusive (66), when CT scan is contraindicated because of allergy to contrast media, or when the physician or the patient are concerned about radiation dose. MRI is an optional test, and there are currently no indications for its systematic use in the staging of testicular cancer.

Chest X-ray is the routine thorax examination. An anteroposterior and lateral chest X-ray could be considered as the only thoracic examination in seminoma when retroperitoneal and pelvic CT scans are negative (67). A chest CT scan is the most sensitive way to evaluate the thorax and mediastinal nodes. This exploration has to be recommended in patients with NSGCT because up to 10% of cases can present with small subpleural nodes that are not visible radiologically (1). The CT scan has high sensitivity but low specificity (66). A chest CT is mandatory in all patients with NSGCT, and in those patients with seminoma and a positive abdominopelvic CT scan (67).

There is not enough evidence to support the use of the fluorodeoxyglucose-PET (FDG-PET) scan in the staging of testis cancer. It is recommended in the follow-up of patients with seminoma with any residual mass at least 4 weeks after chemotherapy in order to decide on watchful waiting or active treatment (68-71).

Other examinations, such as brain or spinal CT, bone scan or liver ultrasound, should be performed if there is suspicion of metastases to these organs. A CT or MRI scan of the skull is advisable in patients with NSGCT and widespread lung metastases. Table I shows the recommended test at staging.

**Table 1: Recommended tests for staging at diagnosis**

Test	Recommendation grade B	Recommendation grade C
Serum tumour markers	Alpha-fetoprotein hCG LDH (for advanced tumours)	
Abdominopelvic CT scan	All patients	Slim adolescent
Chest X-ray	Seminoma*	
Chest CT scan	NSGCT	
Testis ultrasound	Clinical suspicion and normal scrotum at palpation	
MRI	When abdominal CT is inconclusive	All cases
PET scan <sup>†</sup>	Follow-up residual masses in seminoma	
Other	If clinical suspicion	

**Recommended further investigations**

Fertility investigations (should be offered)	Total testosterone, LH, FSH, semen analysis, sperm banking
---	---

*hCG = human chorionic gonadotrophin; LDH = lactate dehydrogenase; CT = computed tomography; NSGCT = non-seminomatous germ cell tumour; MRI = magnetic resonance imaging; PET = positron emission tomography; LH = luteinising hormone; FSH = follicle-stimulating hormone.*

*\*If negative, abdominopelvic CT scan.*

*†There is currently no indication for PET scan at diagnosis.*

**4.4 Staging and prognostic classifications**

The staging system recommended in these guidelines is the 2002 TNM of the International Union Against Cancer (UICC) (Table 2) (72). This includes:

- determination of the anatomical extent of disease
- assessment of serum tumour markers, including nadir values of hCG, AFP and LDH after orchidectomy (S category)
- clear definition of regional nodes
- some N-category modifications related to node size.

**Table 2: TNM classification for testicular cancer (UICC, 2002, 6th edn [72])**

**pT Primary tumour<sup>1</sup>**

pTX	Primary tumour cannot be assessed (see note 1)
pT0	No evidence of primary tumour (e.g. histological scar in testis)
pTis	Intratubular germ cell neoplasia (carcinoma in situ)
pT1	Tumour limited to testis and epididymis without vascular/lymphatic invasion: tumour may invade tunica albuginea but not tunica vaginalis
pT2	Tumour limited to testis and epididymis with vascular/lymphatic invasion, or tumour extending through tunica albuginea with involvement of tunica vaginalis
pT3	Tumour invades spermatic cord with or without vascular/lymphatic invasion
pT4	Tumour invades scrotum with or without vascular/lymphatic invasion

**N Regional lymph nodes clinical**

NX	Regional lymph nodes cannot be assessed
N0	No regional lymph node metastasis
N1	Metastasis with a lymph node mass 2 cm or less in greatest dimension or multiple lymph nodes, none more than 2 cm in greatest dimension
N2	Metastasis with a lymph node mass more than 2 cm but not more than 5 cm in greatest dimension, or multiple lymph nodes, any one mass more than 2 cm but not more than 5 cm in greatest dimension
N3	Metastasis with a lymph node mass more than 5 cm in greatest dimension

**pN Pathological**

pNX	Regional lymph nodes cannot be assessed
pN0	No regional lymph node metastasis
pN1	Metastasis with a lymph node mass 2 cm or less in greatest dimension and 5 or fewer positive nodes, none more than 2 cm in greatest dimension
pN2	Metastasis with a lymph node mass more than 2 cm but not more than 5 cm in greatest dimension; or more than 5 nodes positive, none more than 5 cm; or evidence of extranodal extension of tumour
pN3	Metastasis with a lymph node mass more than 5 cm in greatest dimension

**M Distant metastasis**

MX	Distant metastasis cannot be assessed
M0	No distant metastasis
M1	Distant metastasis
M1a	Non-regional lymph node(s) or lung
M1b	Other sites

**S Serum tumour markers**

Sx	Serum marker studies not available or not performed
S0	Serum marker study levels within normal limits

	<b>LDH (U/l)</b>	<b>hCG (mIU/ml)</b>	<b>AFP (ng/ml)</b>
S1	< 1.5 x N and	< 5,000 and	< 1,000
S2	1.5-10 x N or	5,000-50,000 or	1,000-10,000
S3	> 10 x N or	> 50,000 or	> 10,000

N indicates the upper limit of normal for the LDH assay.

LDH, lactate dehydrogenase; hCG = human chorionic gonadotrophin; AFP = alpha-fetoprotein.

<sup>1</sup>Except for pT1s and pT4, where radical orchidectomy is not always necessary for classification purposes, the extent of the primary tumour is classified after radical orchidectomy; see pT. In other circumstances, TX is used if no radical orchidectomy has been performed.

According to the 2002 TNM classification, stage I testicular cancer includes the following substages:

Stage IA	pT1	N0	M0	S0
Stage IB	pT2, pT3 or pT4	N0	M0	S0
Stage IS	Any patient/TX	N0	M0	S1-3

Stage IA patients have primary tumours limited to the testis and epididymis, with no evidence of microscopic vascular or lymphatic invasion by tumour cells on microscopy, no sign of metastases on clinical examination or imaging, and post-orchidectomy serum tumour marker levels within normal limits. Marker decline in patients with clinical stage I disease should be assessed until normalisation. Stage IB patients have a more locally invasive primary tumour, but no sign of metastatic disease. Stage IS patients have persistently elevated (and usually increasing) serum tumour marker levels after orchidectomy, which is evidence of subclinical metastatic disease (or possibly a second germ cell tumour in the remaining testis). If serum tumour marker levels are declining according to the expected half-life decay after orchidectomy, the patient is usually followed up until normalisation.

In large population-based patient series, 75-80% of seminoma patients, and about 55% of patients with NSGCT cancer have stage I disease at diagnosis (73, 74). True stage IS (persistently elevated or increasing serum marker levels after orchidectomy) is found in about 5% of non-seminoma patients. If a staging retroperitoneal lymph node dissection (RPLND) was to be performed in stage IS patients, nearly all patients would be found to have pathological stage II disease (pN+) (1, 2, 5, 73).

In 1997, the IGCCCG defined a prognostic factor-based staging system for metastatic testis tumour based on identification of some clinical independent adverse factors. This staging system has been incorporated into the TNM Classification and uses histology, location of the primary tumour, location of metastases and pre-chemotherapy marker levels in serum as prognostic factors to categorise patients into 'good', 'intermediate' or 'poor' prognosis (Table 3) (75).

**Table 3: Prognostic-based staging system for metastatic germ cell cancer (International Germ Cell Cancer Collaborative Group).**

<b>Good-prognosis group</b>	
<i>Non-seminoma (56% of cases)</i>	<i>All of the following criteria:</i>
5-year PFS 89%	• Testis/retroperitoneal primary
5-year survival 92%	• No non-pulmonary visceral metastases
	• AFP < 1,000 ng/mL
	• hCG < 5,000 IU/L (1,000 ng/mL)
	• LDH < 1.5 x ULN
<hr/>	
<i>Seminoma (90% of cases)</i>	<i>All of the following criteria:</i>
5-year PFS 82%	• Any primary site
5-year survival 86%	• No non-pulmonary visceral metastases
	• Normal AFP
	• Any hCG
	• Any LDH
<hr/>	
<b>Intermediate prognosis group</b>	
<i>Non-seminoma (28% of cases)</i>	<i>All of the following criteria:</i>
5 years PFS 75%	• Testis/retroperitoneal primary
5-year survival 80%	• No non-pulmonary visceral metastases
	• AFP > 1,000 and < 10,000 ng/mL or

<p><i>Seminoma (10% of cases)</i></p> <p>5-year PFS 67%</p> <p>5-year survival 72%</p>	<ul style="list-style-type: none"> <li>• hCG &gt; 5,000 and &lt; 50,000 IU/L or</li> <li>• LDH &gt; 1.5 and &lt; 10 x ULN</li> </ul> <p><i>Any of the following criteria:</i></p> <ul style="list-style-type: none"> <li>• Any primary site</li> <li>• Non-pulmonary visceral metastases</li> <li>• Normal AFP</li> <li>• Any hCG</li> <li>• Any LDH</li> </ul>
<p><b>Poor prognosis group</b></p> <p><i>Non-seminoma (16% of cases)</i></p> <p>5-year PFS 41%</p> <p>5-year survival 48%</p>	<p><i>Any of the following criteria:</i></p> <ul style="list-style-type: none"> <li>• Mediastinal primary</li> <li>• Non-pulmonary visceral metastases</li> <li>• AFP &gt; 10,000 ng/mL or</li> <li>• hCG &gt; 50,000 IU/L (10,000 ng/mL) or</li> <li>• LDH &gt; 10 x ULN</li> </ul>
<p><i>Seminoma</i></p> <p>No patients classified as poor prognosis</p> <p><i>PFS = progression-free survival; AFP = alpha-fetoprotein; hCG = human chorionic gonadotrophin; LDH = lactate dehydrogenase.</i></p>	

#### 4.5 Prognostic risk factors

For seminoma stage I, tumour size (> 4 cm) and invasion of the rete testis have been identified as the most important predictors for relapse in multivariate analysis (20).

For non-seminoma stage I, vascular invasion of the primary tumour in blood or lymphatic vessels is the most important predictor of occult metastatic disease. The proliferation rate, as well as the percentage of embryonal carcinoma, are additional predictors that improve upon the positive and negative predictive value of vascular invasion (76, 77).

The significant prognostic pathological risk factors for stage I and clinical risk factors for metastatic disease are listed in Table 4.

**Table 4: Prognostic factors for occult metastatic disease in testicular cancer**

	For seminoma	For non-seminoma
<b>Pathological (for stage I)</b>		
Histopathological type	<ul style="list-style-type: none"> <li>• Tumour size (&gt; 4 cm)</li> <li>• Invasion of the rete testis</li> </ul>	<ul style="list-style-type: none"> <li>• Vascular/lymphatic in or peri-tumoural invasion</li> <li>• Proliferation rate &gt; 70%</li> <li>• Percentage of embryonal carcinoma &gt; 50%</li> </ul>
<b>Clinical (for metastatic disease)</b>		
	<ul style="list-style-type: none"> <li>• Primary location</li> <li>• Elevation of tumour marker levels</li> <li>• Presence of non-pulmonary visceral metastasis</li> </ul>	

## 5. IMPACT ON FERTILITY AND FERTILITY- ASSOCIATED ISSUES

Sperm abnormalities are frequently found in patients with testis tumours. Furthermore, chemotherapy and radiation treatment can also impair fertility. In patients in the reproductive age group, pre-treatment fertility assessment (testosterone, luteinising hormone [LH] and FSH levels) should be performed, and semen analysis and cryopreservation should be offered. If cryopreservation is desired, it should be performed before or after orchidectomy, but in any case prior to chemotherapy treatment (48, 78-84).

In cases of bilateral orchidectomy or low testosterone levels after treatment of Tin, life-long testosterone supplementation is necessary (85). For more detailed information, the reader is referred to the EAU Male Infertility Guidelines.

## 6. GUIDELINES ON DIAGNOSIS AND STAGING OF TESTICULAR CANCER

1. Testicular ultrasound is mandatory (grade of recommendation: B).
2. Orchidectomy and pathological examination of the testis are necessary to confirm the diagnosis and to define the local extension (pT category) (grade of recommendation: B). In a life-threatening situation due to extensive metastasis, chemotherapy must be started before orchidectomy.
3. Serum determination of tumour markers (AFP, hCG, and LDH in metastatic disease) must be performed before and after orchidectomy for staging and prognostic reasons (grade of recommendation: B).
4. The state of the retroperitoneal, mediastinal and supraclavicular nodes and viscera must be assessed in testicular cancer. In seminoma, a chest CT scan is not necessary if the abdominal nodes are negative (grade of recommendation: B).

## 7. TREATMENT: STAGE I GERM CELL TUMOURS

### 7.1 Stage I seminoma

After modern staging procedures, about 15-20% of stage I seminoma patients have subclinical metastatic disease, usually in the retroperitoneum, and will relapse after orchidectomy alone (86).

#### 7.1.1 Surveillance

Several prospective non-randomised studies of surveillance have been conducted during the past decade, the largest study coming from Canada with > 1500 patients (87). Previous meta-analysis from four studies showed an actuarial 5 years' relapse-free rate of 82.3%. The Princess Margaret Hospital series (n = 1559) showed an overall relapse rate in unselected patients of 16.8%. The actuarial relapse rate is in the order of 15-20% at 5 years, and most of the relapses are first detected in infra-diaphragmatic lymph nodes (86, 88-90).

Chemotherapy with dosing according to IGCCCG classification is a possible treatment for seminoma relapse under surveillance. However, 70% of patients with relapse are suitable for treatment with radiotherapy alone because of small volume disease at the time of recurrence. Only about 20% of these patients relapse again after salvage radiotherapy and then need salvage chemotherapy.

The overall cancer-specific survival rate reported with surveillance performed by experienced centres is 97-100% for seminoma stage I (89, 90). The main drawback of surveillance is the need for more intensive follow-up, especially with repeated imaging examinations of the retroperitoneal lymph nodes, for at least 5 years after orchidectomy. This compares with the very low risk of subdiaphragmatic relapse after adjuvant radiotherapy.

There is a small but clinically significant risk of relapse more than 5 years after orchidectomy for stage I seminoma which supports the need for long term surveillance (88). Cost analyses of surveillance compared with radiotherapy indicate that it is more expensive (91), but estimates vary, mainly depending on the follow-up schedules (92, 93).

#### 7.1.2 Adjuvant chemotherapy

A joint trial by the Medical Research Council (MRC) and the European Organisation for Research and Treatment of Cancer (EORTC) (MRC TE 19 trial), which compared one cycle of carboplatin (area under curve [AUC] 7) with adjuvant radiotherapy, did not show a significant difference with regard to recurrence rate, time to recurrence and survival after a median follow-up of 4 years (94). Therefore, adjuvant carboplatin therapy is an alternative to radiotherapy or surveillance in stage I seminoma (89, 90, 94). Two courses of adjuvant carboplatin seem to further reduce the relapse rate to the order of 1-3% (95, 96), but further experience and long-term observations are needed.

#### 7.1.3 Adjuvant radiotherapy

Seminoma cells are extremely radiosensitive. Adjuvant radiotherapy to a para-aortic (PA) field or to a hockey-stick field (para-aortic and ipsilateral iliac nodes), with moderate doses (total 20-24 Gy), will reduce the relapse rate to only 1-3% (97-100). After modern radiotherapy, nearly all relapses will first occur outside the irradiated

field (supradiaphragmatic lymph nodes or in the lungs) (97, 100). Based on the results of a large randomised MRC trial, Fossa et al. (97, 98) recommended radiotherapy to a PA field as standard treatment for patients with testicular seminoma stage I, T1-T3 and with undisturbed lymphatic drainage. Acute toxicity was reduced and the sperm count within the first 18 months was significantly higher after PA irradiation than after irradiation of the traditional dog-leg field. On the other hand, the relapse rate in the iliac lymph nodes was about 2% (all of them on the right side) after PA and 0% after dog-leg irradiation. Another possible site of failure is in the left renal hilum. PA irradiation should be tailored according to the site of the primary tumour. Adjuvant irradiation of supradiaphragmatic lymph nodes is not indicated in seminoma stage I.

With regard to the irradiation dose, the MRC recently finished a large randomised trial of 20 Gy versus 30 Gy PA radiation in stage I seminoma that showed equivalence for both doses in terms of recurrence rates (98). The rate of severe radiation-induced long-term toxicity is less than 2%. Moderate chronic gastrointestinal (GI) side-effects are seen in about 5% of patients, and moderate acute GI toxicity in about 60% (97). The main concern surrounding adjuvant radiotherapy is the potentially increased risk of radiation-induced secondary non-germ-cell malignancies (101-104). A scrotal shield can be of benefit during adjuvant radiotherapy in order to prevent scattered radiation toxicity in the contralateral testis (104). It is currently difficult to evaluate the long-term risks after adjuvant radiotherapy for stage I seminoma because former treatment procedures included larger fields, higher doses of radiotherapy and/or the use of alkylating chemotherapy.

#### 7.1.4 Retroperitoneal lymph node dissection (RPLND)

In a prospective, non-randomised study comparing radiotherapy and RPLND in stage I seminoma, there was a trend towards a higher incidence of retroperitoneal relapses (9.5%) after RPLND as primary treatment. Therefore this policy should not be recommended in stage I seminoma (105).

#### 7.1.5 Risk-adapted treatment

Using tumour size > 4 cm and rete testis invasion, patients with seminoma stage I may be subdivided into a low- and high-risk group of occult metastatic disease. Patients with and without both risk factors have a risk of occult disease of 32% and 12%, respectively. These risk factors were introduced by a meta-analysis of retrospective trials (20). A prospective trial based on these risk factors (no risk factors: surveillance; both risk factors: two courses of carboplatin AUC 7) showed the feasibility of a risk-adapted approach. Early data with limited follow-up indicate that patients without either risk factor have a 6.0% risk of relapse at 5 years. Patients at high risk treated with carboplatin experienced a 3.3% relapse rate (106).

## 7.2 Guidelines for the treatment of seminoma stage I

1. Surveillance (if facilities available and patient compliant) (grade of recommendation: B).
2. Carboplatin-based chemotherapy (one course at AUC 7) can be recommended as an alternative to radiotherapy and surveillance (grade of recommendation: A).
3. Adjuvant radiotherapy to a PA or hockey-stick field, to a total dose of 20 Gy (grade of recommendation: A).

## 7.3 NSGCT stage I

Up to 30% of NSGCT patients with clinical stage I (CS1) disease have subclinical metastases and will relapse if surveillance alone is applied after orchidectomy.

#### 7.3.1 Surveillance

Improvements in clinical staging and follow-up methods, and the availability of effective salvage treatment with cisplatin-based chemotherapy and post-chemotherapy surgery, have led to studies of only close surveillance after orchidectomy in CS1 NSGCT patients. The largest reports of the surveillance strategy indicate a cumulative relapse rate of about 30%, with 80% of relapses occurring during the first 12 months of follow-up, 12% during the second year and 6% during the third year, decreasing to 1% during the fourth and fifth years, and occasionally even later (107-110). About 35% of relapsing patients have normal levels of serum tumour markers at relapse. About 60% of relapses are in the retroperitoneum. Despite very close follow-up, 11% of relapsing patients presented with large-volume recurrent disease.

The somewhat lower relapse rates reported from surveillance studies compared with some series of patients staged by RPLND (111) can be explained by the fact that some patients (presumably at risk) are excluded once surveillance is advised. Based on the overall cancer-specific survival data, surveillance within an experienced surveillance programme may be offered to patients with non-risk stratified clinical stage I non-seminoma as long as they are compliant and informed about the expected recurrence rate as well as the salvage treatment (112).

### 7.3.2 Primary chemotherapy

Several studies involving two courses of chemotherapy with cisplatin, etoposide and bleomycin (PEB) as primary treatment for high-risk patients (having about 50% risk of relapse) have been reported (113-118). In these series, involving more than 200 patients, some with a median follow-up of nearly 8 years (113), a relapse rate of only 2.7% was reported, with very little long-term toxicity. Two cycles of cisplatin-based adjuvant chemotherapy do not seem to adversely affect fertility or sexual activity (119).

It is important to be aware of the slow-growing retroperitoneal teratomas after primary chemotherapy and of the risk of late chemoresistant cancer relapse (120). The need for repeated and long-term follow-up with imaging of the retroperitoneum after primary chemotherapy is not yet clear.

The results of cost analyses comparing surveillance, RPLND and primary chemotherapy show different results among the reported studies, possibly because of differences in intensity and costs related to follow-up procedures (121). With a low frequency of follow-up CTs (such as has been proven effective for the surveillance strategy in non-seminoma CS1), the costs of follow-up can be considerably reduced (122).

### 7.3.3 Risk-adapted treatment

Risk-adapted treatment is currently based on the risk factor vascular invasion. Stratifying patients with CS1 NSGCT according to their presumed risk of relapse is a rational option, as several studies have reported similar survival rates and a final cure rate close to 100% with all available treatment options using the risk-stratifying approach (113-118, 123-125). Risk-adapted treatment is therefore an equally effective alternative treatment of choice in CS1 NSGCT.

Patients with vascular invasion are recommended to undergo adjuvant chemotherapy with two cycles of PEB, and patients without vascular invasion are recommended to undergo surveillance. Only if patients or doctors are not willing to accept the consequent risk-adapted treatment, or if there are circumstances that militate against the risk-adapted treatment option, should the remaining treatments be considered.

Thus, the decision about treatment should be based on a thorough discussion with the patients, taking into account the described advantages and disadvantages, as well as the individual situation of the patient and/or the treatment centre. The Swedish-Norwegian Testicular Cancer Project (SWENOTECA) recently showed that in a large population-based study with a risk-adapted approach within a management programme and a median follow-up of 4.7 years, the relapse rate was 3.2% for patients with vascular invasion treated with only one adjuvant PEB (126).

### 7.3.4 Retroperitoneal lymph node dissection

If RPLND is performed, about 30% of patients are found to have retroperitoneal lymph node metastases, which corresponds to pathological stage II (PS2) disease (105, 127, 128). If no retroperitoneal metastases are found at RPLND (PS1), approximately 10% of the PS1 patients relapse at distant sites (77, 111, 129-131).

The main predictor of relapse in CS1 NSGCT managed by surveillance, for having PS2 disease and for relapse in PS1 after RPLND, is histopathological evidence of vascular invasion by tumour cells in, or near, the primary tumour in the testis (77, 107, 111, 131, 132). The presence of vascular invasion seems to be a very robust parameter, and is clinically usable even without centralised review by an expert panel (123, 131). Vascular invasion was the most predictive of stage in a multifactorial analysis. The absence of vascular invasion has a negative predictive value of 77%, thus allowing for surveillance in low-risk compliant patients (77).

Patients without vascular invasion constitute about 50-70% of the CS1 population, and these patients have only a 15-20% risk of relapse on surveillance, compared with a 50% relapse rate in patients with vascular invasion. The risk of relapse for PS1 patients is less than 10% for those without vascular invasion and about 30% for those with vascular invasion (123, 131, 133, 134).

If CS1 patients with PS2 are followed up only after RPLND, about 30% relapse, mainly at sites outside the abdomen and pelvis. The risk of relapse depends upon the amount of retroperitoneal disease resected (135-137). If two (or more) courses of cisplatin-based chemotherapy are given adjuvant to RPLND in PS2 cases, the relapse rate is reduced to less than 2%, including teratoma relapse (111, 132, 138). The risk of retroperitoneal relapse after a properly performed nerve-sparing RPLND is very low (less than 2%), as is the risk of ejaculatory disturbance or other significant side-effects (132, 135, 136).

The follow-up after RPLND is much simpler and less costly than that carried out during post-orchidectomy surveillance because of the reduced need for abdominal CT scans (132). A laparoscopic RPLND may become

a good alternative to an open staging RPLND, but cannot currently be recommended as a standard diagnostic tool (139-142). In a randomised comparison of RPLND with one course of PEB chemotherapy, adjuvant chemotherapy significantly increased the 2-year recurrence-free survival to 99.41% (confidence interval [CI] 95.87%, 99.92%) as opposed to surgery, which had a 2-year recurrence-free survival of 92.37% (CI 87.21%, 95.50%). The difference was 7.04%, CI 2.52%, 11.56%. The hazard ratio to experience a tumour recurrence with surgery as opposed to chemotherapy was 7.937, CI 1.808, 34.48. Therefore, one course of adjuvant PEB is superior to RPLND with regard to recurrence rates in patients unstratified for risk factors (143). In the SWENOTECA data mentioned in section 7.3.3 it was also found that one adjuvant PEB reduced the number of recurrences for 90% for patients, whether vascular invasion was present or not (126).

#### 7.4 CS1S with (persistently) elevated serum tumour markers

Serum tumour markers should be followed closely until levels fall into the reference values according to the expected half-life values for AFP and hCG. If the marker level increases after orchidectomy, the patient has residual disease. If RPLND is performed, up to 87% of these patients have pathologically documented nodes in the retroperitoneum (144). An ultrasound examination of the contralateral testicle must be performed, if this was not done initially.

The treatment of true CS1S patients is still controversial. They may be treated with three courses of primary PEB chemotherapy and with follow-up as for CS1B patients (high risk, see below) after primary chemotherapy (145), or by RPLND (121). The presence of vascular invasion may strengthen the indication for primary chemotherapy as most CS1S with vascular invasion will need chemotherapy sooner or later anyway.

#### 7.5 Guidelines for the treatment of NSGCT stage I

CS1 risk-adapted treatments based on vascular invasion or surveillance are recommended treatment options (grade of recommendation: B) (Table 5).

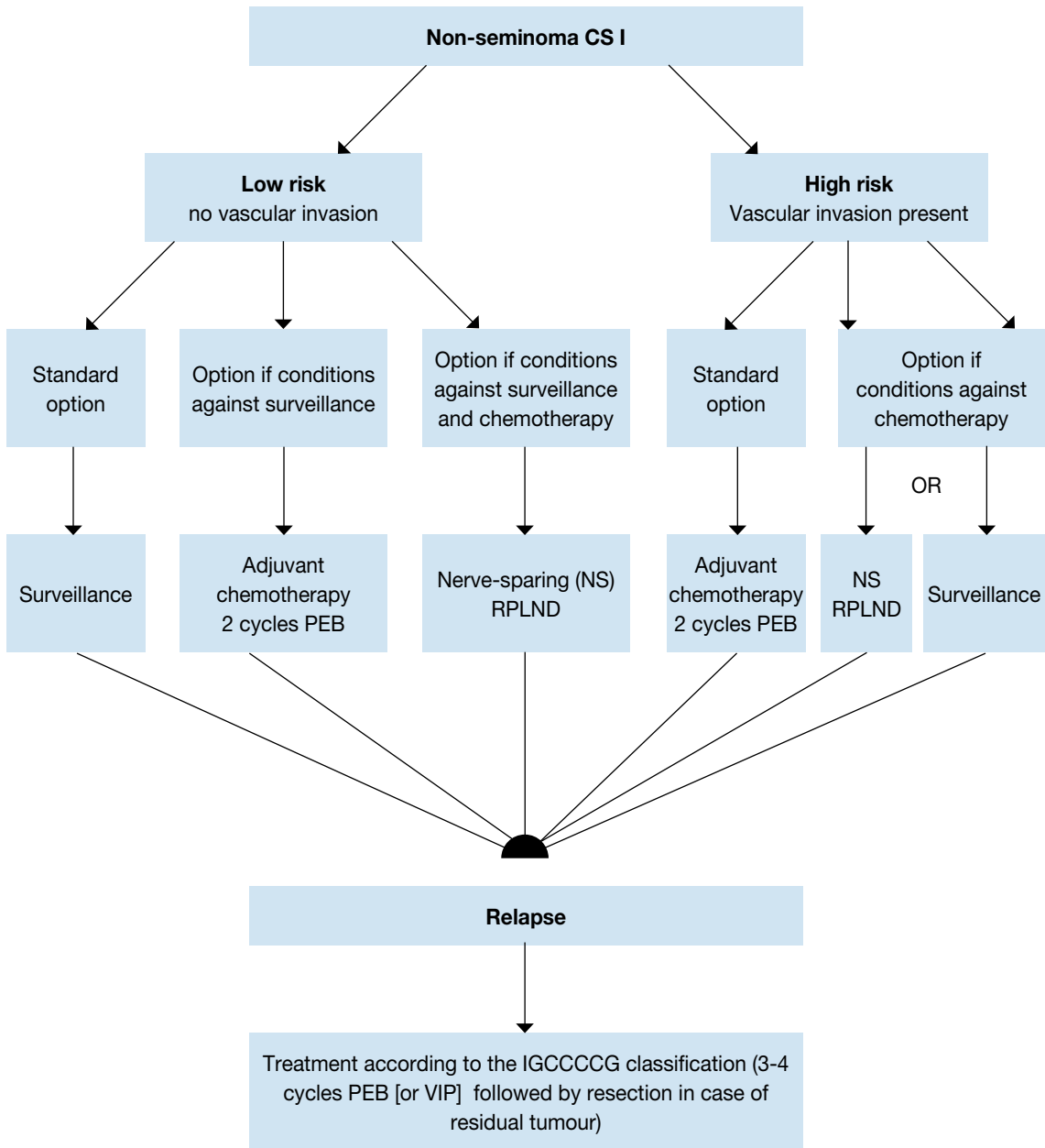
**Table 5: Risk-adapted treatments for CS1 based on vascular invasion or surveillance**

		GR
<b>CS1A (pT1, no vascular invasion): low risk</b>		
1.	If the patient is willing and able to comply with a surveillance policy, long-term (at least 5 years) close follow-up should be recommended.	<b>B</b>
2.	Adjuvant chemotherapy or nerve-sparing RPLND in low-risk patients remain options for those not willing to undergo surveillance. If RPLND reveals PN+ (nodal involvement) disease, chemotherapy with two courses of PEB should be considered.	<b>A</b>
<b>CS1B (pT2-pT4): high risk</b>		
1.	Primary chemotherapy with two courses of PEB should be recommended.	<b>B</b>
2.	Surveillance or nerve-sparing RPLND in high-risk patients remain options for those not willing to undergo adjuvant chemotherapy. If pathological stage II is revealed at RPLND, further chemotherapy should be considered.	<b>A</b>

GR = grade of recommendation.

Figure 1 provides a treatment algorithm for patients with NSGCT stage I.

**Figure 1: Treatment algorithm after orchidectomy according to individual risk factors in patients with non-seminoma NSGCT CS1 (22)**



PEB = cisplatin, etoposide, bleomycin; CS = clinical stage; IGCCCG = International Germ Cell Cancer Collaborative Group; RLND = retroperitoneal lymph node dissection; VIP = etoposide, cisplatin, ifosfamide

## 8. TREATMENT: METASTATIC GERM CELL TUMOURS

The treatment of metastatic germ cell tumours depends on:

- the histology of the primary tumour
- prognostic groups as defined by the IGCCCG based on 5202 non-seminoma and 660 seminoma cases (Table 3) (146).

### 8.1 Low-volume metastatic disease (stage IIA/B)

#### 8.1.1 Stage IIA/B seminoma

So far, the standard treatment for stage IIA/B seminoma has been radiotherapy. The radiation dose delivered in stage IIA and IIB is **approximately** 30 Gy and 36 Gy, respectively. The standard radiation field compared with stage I will be extended from the PA region to the ipsilateral iliac field (the hockey-stick field). In stage IIB, the lateral borders should include the metastatic lymph nodes with a safety margin of 1.0-1.5 cm. This technique yields a relapse-free survival after 6 years for stage IIA and IIB of 95% and 89%, respectively. Overall survival is almost 100% (61, 89).

In stage IIB chemotherapy (4 x etoposide and cisplatin [EP] or 3 x PEB in good prognosis) is an alternative to radiotherapy. Although more toxic in the short term, it appears that 4 x EP or 3 x PEB achieve a similar level of disease control (147). Single-agent carboplatin is not an alternative to standard PEB chemotherapy (148).

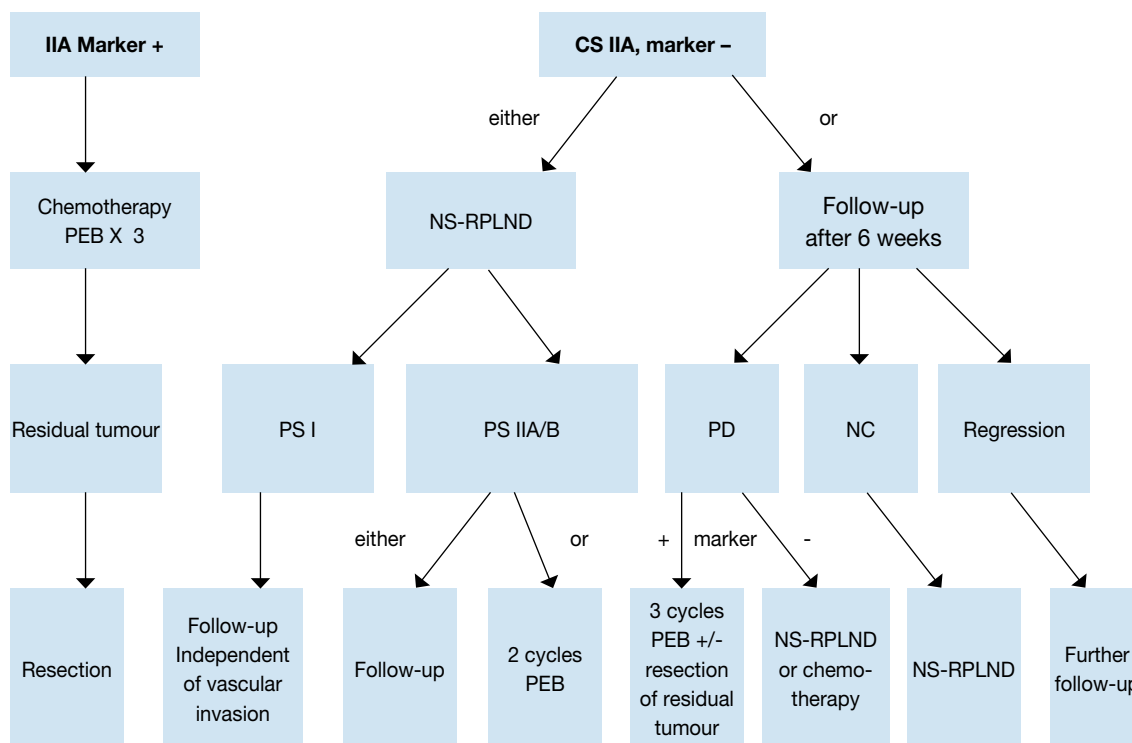
#### 8.1.2 Stage IIA/B non-seminoma

There is a general consensus that treatment should start with initial chemotherapy in all advanced cases of NSGCT except for stage II NSGCT disease without elevated tumour markers, which alternatively can be treated with primary RPLND or surveillance (149, 150).

If surveillance is chosen, one follow-up after 6 weeks is indicated to document whether the lesion is growing, remaining stable or shrinking. A shrinking lesion is likely to be of non-malignant origin and should be observed further. A stable or growing lesion indicates either teratoma or an undifferentiated malignant tumour. If the lesion is growing without a corresponding increase in the tumour markers AFP or beta-hCG, RPLND should be performed by an experienced surgeon because of suspected teratoma. Patients with a growing lesion and a concomitant increase in the tumour markers AFP or beta-hCG should not undergo surgery; they require chemotherapy with PEB according to the treatment algorithm for patients with metastatic disease and IGCCCG recommendations (151-153) (Figure 2). There is no proven role for PET scans in this situation.

Patients not willing to undergo primary chemotherapy have the option of primary nerve-sparing RPLND with adjuvant chemotherapy (two cycles of PEB) in case of metastatic disease (pII A/B). Primary chemotherapy and primary RPLND are comparable options in terms of outcome but side-effects and toxicity are different, allowing for involvement of the patient in selecting the treatment of choice (154). The cure rate with either approach will be close to 98% (138, 155-160).

**Figure 2: Treatment options in patients with non-seminoma clinical stage IIA (23)**



PEB = cisplatin, etoposide, bleomycin; NS = nerve-sparing; RPLND = retroperitoneal lymph node dissection; PS = pathological stage; PD = progressive disease; NC = no change.

## 8.2 Advanced metastatic disease

### 8.2.1 Primary chemotherapy

The primary treatment of choice for advanced disease is three or four cycles of PEB combination chemotherapy (Table 6), depending on the IGCCCG risk classification (see Table 3). This regimen has proven superiority to cisplatin, vinblastine and bleomycin (PVB) in patients with advanced disease (161-163). Data support a 3-day regimen of administering combination chemotherapy to be equally effective as a 5-day regimen, but associated with increased toxicity (164).

**Table 6: PEB regimen (interval 21 days).**

Drug	Dosage	Duration of cycles
Cisplatin	20 mg/m <sup>2</sup>	Days 1-5*
Etoposide	100 mg/m <sup>2</sup>	Days 1-5
Bleomycin	30 mg (bolus)	Days 1, 8, 15

\*Plus hydration.

PEB = cisplatin, etoposide, bleomycin

For patients with a 'good prognosis', according to the IGCCCG Classification (146), standard treatment consists of three cycles of PEB or, in cases where bleomycin is contraindicated, four cycles of EP (146,163-167). Therapy should be given without reduction of the doses at 21-day intervals; delaying the following chemotherapy cycle is justified only in cases of fever with granulocytopenia < 1000/mm<sup>3</sup> or thrombocytopenia < 100,000/IU. There is no indication for prophylactic application of haematopoietic growth factors such as, for example, granulocyte colony-stimulating factor (G-CSF). However, if infectious complications have occurred during chemotherapy, prophylactic administration of G-CSF is recommended for the following cycles (165, 168).

The 'intermediate prognosis' group in the IGCCCG has been defined as patients with a 5- year survival rate of about 80%. The available data support four cycles of PEB as standard treatment (146, 169). Due to the generally less favourable prognosis of patients in this group compared with those with a 'good prognosis', they may be treated in prospective trials such as, for example, the EORTC Genitourinary Tract Cancer Cooperative Group trial with PEB vs PEB + paclitaxel (169).

For patients with a 'poor prognosis', standard treatment consists of four cycles of PEB. Four cycles of cisplatin, etoposide and ifosfamide (PEI) have the same effect, but are more toxic (170, 171). The 5-year progression-free survival is between 45% and 50%. A randomised study has shown no advantage in high-dose chemotherapy for the overall group of 'poor prognosis' patients. However, patients with a slow marker decline may represent a prognostically inferior subgroup (172). Since a matched-pair analysis resulted in a better survival rate (173-175), poor prognosis patients should still be treated in ongoing prospective randomised trials, investigating the value of high-dose chemotherapy. Patients meeting 'poor-prognosis' criteria should therefore be transferred to a reference centre. There are no general recommendations for treatment modifications for patients with a poor general condition (Karnofsky < 50%), extended liver infiltration (> 50%), or extended pulmonary infiltration.

### **8.3 Restaging and further treatment**

#### *8.3.1 Restaging*

Restaging is performed by imaging investigations and re-evaluation of tumour markers. At marker decline and stable or regressive tumour manifestation, chemotherapy will be completed (three or four cycles, depending on the initial stage) (146, 176, 177). In the case of marker decline but growing metastases, resection of the tumour is obligatory after termination of induction therapy, other than in an emergency, according to local tumour growth (178).

Only with documented marker growth after two courses of chemotherapy is an early crossover of therapy indicated. These patients are usually candidates for new drugs trials (173, 179). Patients with a low-level marker plateau post-treatment should be observed to see whether complete normalisation occurs. Salvage chemotherapy is indicated for documented marker rise only (180, 181).

#### *8.3.2 Residual tumour resection*

A residual mass of seminoma should not be resected, irrespective of the size, but controlled by imaging investigations and tumour markers (182-188).

FDG-PET has a high prognostic value in patients with residual masses after treatment of seminoma. In patients with residuals of > 3 cm, FDG-PET should be performed in order to gain more information on the viability of these residuals. In patients with residuals of < 3 cm, the use of FDG-PET is optional (189).

On progression, salvage therapy is indicated (chemotherapy, salvage surgery, radiotherapy) (190-194). In the case of non-seminoma and complete remission after chemotherapy (no tumour visible), residual tumour resection is not indicated (195-200). In the case of any visible residual mass and marker normalisation, surgical resection is indicated. In patients with lesions < 1 cm, there still is an increased risk of residual cancer or teratoma (201). In persistent retroperitoneal disease, all areas of primary metastatic sites must be completely resected within 4-6 weeks of completion of chemotherapy. If technically feasible, a nerve-sparing procedure should be performed (195, 202-209).

Overall, following PEB induction chemotherapy, only 10% of residual masses contain viable cancer, 50% contain mature teratoma, and 40% contain necrotic-fibrotic tissue. As yet, no imaging investigations, including PET or a prognosis model, are able to predict histological differentiation of the non-seminomatous residual tumour. Thus, residual tumour resection is mandatory (196-198, 208-218).

The extent of surgery should be based on the risk of relapse of an individual patient and quality of life issues (203). If possible, all the masses should be resected, because a complete resection, in the setting of viable malignant cells, is more critical than recourse to post-operative chemotherapy (219). The histology may diverge in different organ sites (211). Resection of contralateral pulmonary lesions is not mandatory in case pathologic examination of the lesions from the first lung shows complete necrosis (220).

#### *8.3.3 Consolidation chemotherapy after secondary surgery*

After resection of necrosis or mature teratoma, no further treatment is required. In the case of incomplete resection of vital carcinoma or immature teratoma, two adjuvant cycles of conventionally dosed cisplatin-based chemotherapy may be given in certain subgroups (e.g. 'poor prognosis' patients) (219, 221) (caution: cumulative doses of bleomycin). After complete resection of vital tumour < 10% of the total volume, adjuvant chemotherapy is not beneficial for preventing further relapse. The prognosis will definitely deteriorate if vital carcinoma is found in resection specimens after second- and third-line chemotherapy. In this latter situation, post-operative chemotherapy is not indicated and is unable to improve the prognosis (207, 212).

## 8.4 Systemic salvage treatment for relapse or refractory disease

### 8.4.1 Seminoma

Cisplatin-based combination salvage chemotherapy will result in long-term remissions for about 50% of the patients who relapse after first-line chemotherapy (222). The regimens of choice are four cycles of PEI/VIP (etoposide, ifosfamide, cisplatin), four cycles of TIP (paclitaxel, ifosfamide, cisplatin) or four cycles of VeIP (vinblastine, ifosfamide, cisplatin). At present, it is impossible to determine whether conventionally dosed cisplatin-based combination chemotherapy is sufficient as first-salvage treatment or whether early intensification of first-salvage treatment with high-dose chemotherapy should be attempted (223). It is therefore of the utmost importance that these rare patients are treated within clinical trials and at experienced centres.

### 8.4.2 Non-seminoma

Standard salvage treatment after first-line chemotherapy consists of either four cycles of PEI/VIP, four courses of TIP, or four cycles of VeIP, respectively (Table 7).

**Table 7: Standard PEI/VIP, TIP and VeIP chemotherapy (interval 21 days)**

Chemotherapy agents	Dosage	Duration of cycles
<b>PEI/VIP</b>		
Cisplatin*	20 mg/m <sup>2</sup>	Days 1-5
Etoposide	75-100 mg/m <sup>2</sup>	Days 1-5
Ifosfamide†	1.2 g/m <sup>2</sup>	Days 1-5
<b>TIP</b>		
Paclitaxel	250 mg/m <sup>2</sup>	24 hour continuous infusion day 1
Ifosfamide†	1.5 g/m <sup>2</sup>	Days 2-5
Cisplatin*	25 mg/m <sup>2</sup>	Days 2-5
<b>VeIP</b>		
Vinblastin	0.11 mg/kg	Days 1 + 2
Ifosfamide†	1.2 g/m <sup>2</sup>	Days 1-5
Cisplatin*	20 mg/m <sup>2</sup>	Days 1-5

PEI/VIP = cisplatin, etoposide, ifosfamide; TIP = paclitaxel, ifosfamide, cisplatin; VeIP = vinblastine, ifosfamide, cisplatin.

\*Plus hydration.

†Plus mesna protection.

Conventionally dosed salvage chemotherapy may achieve long-term remissions in 15-40% of patients, depending on individual risk factors (181, 224). Prognostic indicators of response to salvage therapy are (181, 224-226):

- the location and histology of the primary tumour
- the response to first-line treatment
- the duration of remissions
- the level of AFP and hCG at relapse.

Salvage therapy with VeIP is probably not superior to other conventionally dosed cisplatin-based combination regimens (220-222). The use of conventionally dosed combination regimens with more than three agents will increase toxicity without improving the treatment outcome (227).

Depending on the presence of adverse prognostic factors, the results of salvage therapy after first-line cisplatin based treatment are unsatisfactory (181, 228). Although some phase II trials indicate a 10% improvement in survival with early intensification of first-salvage treatment using high-dose chemotherapy, others fail to demonstrate such improvement (229-233).

High dose chemotherapy offered no advantage as first salvage treatment according to the results of the randomised IT 94 trial in good prognosis patients (234). Patients with good prognostic features should therefore be offered conventional-dose first salvage treatment.

Several phase II trials, as well as one retrospectively matched pair-analysis, have shown an improvement in survival in poor-prognosis patients with early intensification of first-salvage treatment using high-dose chemotherapy (225, 235-237) (EBM: 2B).

Recently, paclitaxel and gemcitabine have proved to be active in the treatment of refractory germ cell tumours; both drugs are synergistic with cisplatin (238-240). However, all of these patients should be entered into ongoing multicentre studies to define the optimal approach to salvage treatment, and should be referred to centres experienced in caring for relapse and/or refractory patients (223).

#### 8.4.3 Late relapse ( $\geq 2$ years after end of first-line treatment)

Late relapse is defined as any patient relapsing more than 2 years following chemotherapy for metastatic disease. If technically feasible, all patients with late relapse should undergo immediate radical surgery of all lesions, irrespective of the level of their tumour markers to resect completely all undifferentiated germ-cell tumour, mature teratoma or secondary non-germ cell cancer (120, 241). If the lesions are not completely resectable, biopsies should be obtained for histological assessment, and salvage chemotherapy should be initiated according to the histological results. If the patient responds to salvage chemotherapy, secondary surgery should be conducted whenever possible. In the case of unresectable, but localised, refractory disease, radiotherapy can be considered. To avoid excess mortality, late relapses should be treated only at centres experienced in managing such patients (242).

### 8.5 Salvage surgery

Residual tumours after salvage chemotherapy should be resected within 4-6 weeks after marker normalisation or when a marker plateau is reached. In the case of marker progression after salvage treatment and a lack of other chemotherapeutic options, resection of residual tumours ('desperation surgery') should be considered if complete resection of all tumour seems feasible (about 25% long-term survival may be achieved) (181, 205, 213, 216, 243-252).

### 8.6 Treatment of brain metastases

Brain metastases occur in the frame of a systemic relapse and rarely as an isolated relapse. The long-term survival of patients presenting with brain metastases at initial diagnosis is poor (30-40%), but even poorer is the development of a brain metastasis as a recurrent disease (the 5-year survival-rate is 2-5%) (253, 254). Chemotherapy is the initial treatment in this case, and some data support the use of consolidation radiotherapy, even in the case of a total response after chemotherapy (255). Surgery can be considered in the case of a persistent solitary metastasis, depending on the systemic state, the histology of the primary tumour and the location of the metastasis.

### 8.7 Guidelines for the treatment of metastatic germ cell tumours

	GR
1. Low volume NSGCT stage IIA/B with elevated markers should be treated like 'good or intermediate prognosis' advanced NSGCT, with three or four cycles of PEB. Stage IIA/B without marker elevation can be treated by RPLND or close surveillance.	
2. In metastatic NSGCT ( $\geq$ stage IIC) with a good prognosis, three courses of PEB is the primary treatment of choice	A
3. In metastatic NSGCT with an intermediate or poor prognosis, the primary treatment of choice is four courses of standard PEB	A
4. Surgical resection of residual masses after chemotherapy in NSGCT is indicated in the case of visible residual masses and when serum levels of tumour markers are normal or normalising	B
5. Seminoma CSII A/B can initially be treated with radiotherapy. When necessary, chemotherapy can be used as a salvage treatment with the same schedule as for the corresponding prognostic groups of NSGCT	A
6. In stage CS IIB, chemotherapy (4 x EP or 3 x PEB, in good prognosis) is an alternative to radiotherapy. Although more toxic in the short term, it appears that 4 x EP or 3 x PEB achieve a similar level of disease control.	B
7. Seminoma stage IIC and higher should be treated with primary chemotherapy according to the same principles used for NSGCT	A

GR = grade of recommendation

## 9. FOLLOW-UP AFTER CURATIVE THERAPY

### 9.1 General considerations

The selection of the test to be performed in follow-up should adhere to the following principles (256).

- The interval between examination and duration of testing should be consistent with the time of maximal risk of recurrence and the natural history of the tumour.
- The tests should be directed at the most likely sites of recurrence and should have a high predictive value, both positive and negative.
- Therapy should be available that will result in cure of the recurrence, significant prolongation of life or palliation of symptoms. The initiation of earlier therapy should improve the outcome compared with therapy given when the patient becomes symptomatic from the tumour recurrence.
- The increased risk of second malignancy, both in the primary site and in other tissues that may have been exposed to the same carcinogens, or in which there is epidemiological evidence of increased risk, should also guide the ordering tests. Malignant and non-malignant complications of therapy must also be considered. Such testing should also be performed with a frequency and duration consistent with the nature of the risk, and include only tests with high positive- and negative-predictive values.

The following considerations apply in a general manner for the selection of an appropriate schedule and testing in the follow-up of all stages of testis tumour.

- Most recurrences after curative therapy will occur in the first 2 years; surveillance should therefore be most frequent and intensive during this time.
- Late relapses can occur beyond 5 years, and therefore yearly follow-up for life may be advocated.
- After RPLND, relapse in the retroperitoneum is rare, the most likely site of recurrence being the chest.
- The value of chest X-ray has been recently questioned in the follow-up of patients with disseminated disease after complete remission (257, 258).
- CT of the chest has a higher predictive value than chest X-ray (258).
- The results of therapy are dependent on the bulk of disease; thus an intensive strategy to detect asymptomatic disease may be justifiable.
- After chemotherapy or radiotherapy, there is a long-term risk of the development of secondary malignancies.

### 9.2 Follow-up: stage I non-seminoma

Approximately 5% of patients with CS1 NSGCT present with elevated levels of tumour markers after orchidectomy, and up to 25-30% relapse during the first 2 years (5, 113, 131, 134, 155, 259-262).

The follow-up schedule will differ depending on which of the three possible treatment strategies was chosen:

- surveillance
- nerve-sparing RPLND
- adjuvant chemotherapy.

#### 9.2.1 Follow-up investigations during surveillance

The results of a surveillance policy depend upon a careful pre-operative staging procedure and follow-up management. In a 'wait and see' policy, relapses will occur in 30% of cases. Of these relapses, 80% will occur in the first 12 months after orchidectomy, and approximately 12% during the second year. The median time to relapse is 6 months (range 1-62 months), but relapses after 3-5 years, and even later, can still occur, with an annual rate of 4% (108, 109). Relapse occurs mainly in the retroperitoneum: approximately 20% of patients have evident metastases in the retroperitoneum, and 10% in the mediastinum and lungs (263). Sometimes the only indication is an elevated level of tumour markers.

A randomised trial of two versus five CT scans has been published by the MRC recommending the reduction of imaging during surveillance in this stage to one CT scan at 3 months after orchidectomy, and another at 12 months. The trial, with a cohort of 414 patients, was powered to exclude a 3% probability of detecting a patient during surveillance only, with a relapse presenting already-metastatic disease with 'intermediate' or 'poor' prognosis features. Relapses were detected in 15% with two CTs, and 20% with five CTs; 1.6% of these patients had 'intermediate' or 'poor' prognosis features. Only 10% of patients had high-risk features (vascular invasion). In summary, this first randomised trial yielded level 1 evidence for a minimum follow-up in patients with CS1 non-seminoma (122). The recommended follow-up schedule (Table 8) includes the minimum requirements for imaging, and adds recommendations for other surveillance tests.

**Table 8: Recommended minimum follow-up schedule in a surveillance policy: stage I non-seminoma**

Procedure	Year			
	1	2	3-5	6-10
Physical examination	4 times	4 times	Twice per year	Once per year
Tumour markers	4 times	4 times	Twice per year	Once per year
Chest X-ray	Twice	Twice		
Abdominopelvic CT scan	Twice (at 3 and 12 months)			

*CT= computed tomography scan.*

During the initial post-treatment phase, follow-up consists of regular clinical examinations, the monitoring of serum tumour markers, and imaging investigations. The frequency and type of the examinations depend on the estimated risk of relapse, the chosen treatment strategy, and the time that has elapsed since completion of therapy, and should be modified according to these risks. However, only limited information about the optimal follow-up strategy exists, and currently recommendations can only be given for seminoma (264).

For low-risk stage I non-seminoma, two abdominopelvic CT scans during the first year seem sufficient to detect relapses at an early stage (122). The significance of additional CT scans remains uncertain. No studies are available that address the optimal monitoring of such patients by serum tumour markers (AFP, beta-hCG).

### 9.2.2 Follow-up after nerve-sparing RPLND

Retroperitoneal relapse after a properly performed nerve-sparing RPLND is rare. RPLND should eliminate the retroperitoneal nodes as a site of relapse and thus the need for repeated abdominal CT scans. The US Testicular Cancer Intergroup study data show retroperitoneal relapse in 7/264 patients with pathological stage I disease (and 20 pulmonary relapses); four of these seven had no marker elevation (265). In the Indiana series, only one relapse in 559 cases was reported (266). If a relapse occurs, it is generally in the chest, neck or at the margins of the surgical field.

Pulmonary relapses occur in 10-12% of patients, and more than 90% of those relapses occur within 2 years of RPLND (74, 267). However, the low rate of retroperitoneal relapse after RPLND can only be achieved by surgery in specialised centres, as shown by the high in-field relapse rate (7/13 relapses) in the German randomised trial of RPLND versus one course of PEB (143). The recommended minimum follow-up schedule is shown in Table 9.

**Table 9: Recommended minimum follow-up schedule after retroperitoneal lymphadenectomy or adjuvant chemotherapy: stage I non-seminoma**

Procedure	Year			
	1	2	3-5	6-10
Physical examination	4 times	4 times	Twice/year	Once/year
Tumour markers	4 times	4 times	Twice/year	Once/year
Chest X-ray	Twice	Twice		
Abdominopelvic CT scan	Once	Once		

*CT = computed tomography scan.*

### 9.2.3 Follow-up after adjuvant chemotherapy

Prospective reports with long-term follow-up after adjuvant chemotherapy have shown a low relapse rate (113, 114, 259, 260) of about 3%. In a randomised trial with one course of PEB versus RPLND, the relapse rate with adjuvant chemotherapy was 1% (2/174 patients, one with marker relapse, one with mature teratoma in the retroperitoneum) (143). The need for repeated and long-term assessment of the retroperitoneum is still not clear. Owing to the risk of developing a late, slow-growing teratoma in the retroperitoneum after adjuvant chemotherapy, an abdominal CT should still be performed (see Table 9).

## 9.3 Follow-up: stage I seminoma

The majority of patients with seminoma (70-80%) present with clinical stage I disease at diagnosis (89). In 15-20% of cases, there is nodal radiological involvement at the level of the retroperitoneum, and only 5% of patients present with distant metastasis (89).

The relapse rate varies between 1% and 20%, depending on the post-orchidectomy therapy chosen. Only up to 30% of seminomas present with elevation of hCG at diagnosis or in the course of the disease.

Consequently, in most cases, measurement of blood markers will not be a reliable test for follow-up (268). The treatment options post-orchidectomy in stage I seminoma are retroperitoneal radiotherapy, surveillance and adjuvant chemotherapy. Due to extreme radio- and chemosensitivity, high cure rates of almost 100% are reached with each of the approaches, even in cases of relapse. The costs of the different therapies vary, as do the expected side-effects (91, 269, 270).

### 9.3.1 Follow-up after radiotherapy

Low doses of radiotherapy (20-24 Gy) limited to the retroperitoneal or the hockey-stick field achieve an overall survival rate of approximately 99% at 5-10 years (97-99, 271, 272). The rate of relapse is 1-2% and the most common time of presentation is within 18 months of treatment (97, 100, 270, 273, 274), although late relapses have also been described (275). The site of relapse is mainly at the supradiaphragmatic lymph nodes, mediastinum, lungs or bones. In a small proportion of cases, the tumour will relapse in the inguinal or external iliac nodes (89).

The side-effects of radiotherapy include impaired spermatogenesis, GI symptoms (peptic ulceration), and induction of second malignancies (270, 276, 277). Up to 50% of patients can develop moderate toxicity grade I-II (268). The schedule of follow-up is described in Table 10.

**Table 10: Recommended minimum follow-up schedule for post-orchidectomy surveillance, radiotherapy or chemotherapy: stage I seminoma**

Procedure	Year			
	1	2	3-4	5-10
Physical examination	3 times	3 times	Twice/year	Once/year
Tumour markers	3 times	3 times	Twice/year	Once/year
Chest X-ray	Twice/year	Twice/year	Once/year	Once/year
Abdominopelvic CT scan	Twice/year	Twice/year	Once/year	Once/year

CT = computed tomography scan.

### 9.3.2 Follow-up during surveillance

The actuarial risk of relapse at 5 years ranges between 6% (low risk) and 20% (106, 278-282). There is no increased risk of death. The median time to relapse ranges from 12-18 months, but up to 29% of relapses can develop later than this (87, 283). The sites of relapse are the PA lymph nodes in up to 82% of cases; the pelvic lymph nodes, inguinal nodes and lungs can also be affected (87, 284-288). Due to the high and often late rate of relapse, close and active follow-up is mandatory for at least 5 years (289) (see Table 10).

### 9.3.3 Follow-up after adjuvant chemotherapy

One or two courses of carboplatin-based chemotherapy is an effective alternative treatment in stage I seminoma. The relapse rate is 1.9-4.5%. In general, this treatment is well tolerated, with only mild, acute and intermediate-term toxicity (289, 290). Long-term data on late relapses and survival are missing (see Table 10).

## 9.4 Follow-up: stage II and advanced (metastatic) disease

The more advanced the nodal stage of the disease, the higher the likelihood of recurrence (138). In general, the primary tumour bulk governs the outcome for patients with NSGCT (291). In stage II NSGCT, regardless of the treatment policy adopted, excellent survival rates of 97% are reached provided that relapse is identified as soon as possible (149, 150, 156).

In advanced metastatic germ cell tumours, the extent of the disease is correlated with the response to therapy and with survival. The combination of cisplatin-based chemotherapy and surgery (aggressive multimodality) achieves cure rates of between 65% and 85%, depending on the initial extent of disease (292, 293). Complete response rates to chemotherapy are in the order of 50-60% (292); another 20-30% of patients could be rendered disease-free with post-chemotherapy surgery (294).

The main reasons for failure of therapy in advanced NSGCT are (291, 295, 296):

- the presence of bulky disease not responding completely to chemotherapy
- unresectable residual teratoma after chemotherapy
- the presence or development of chemoresistant non-germ elements, which account for 8.2% of cases.

Table 11 gives the recommended minimum follow-up schedule in advanced NSGCT and seminoma.

**Table 11: Recommended minimum follow-up schedule in advanced NSGCT and seminoma**

Procedure	Year			
	1	2	3-5	Thereafter
Physical examination	4 times	4 times	Twice per year	Once per year
Tumour markers	4 times	4 times	Twice per year	Once per year
Chest X-ray	4 times	4 times	Twice per year	Once per year
Abdominopelvic CT scan*†	Twice	Twice	Once per year	Once per year
Chest CT scan††	As indicated	As indicated	As indicated	As indicated
Brain CT scan§	As indicated	As indicated	As indicated	As indicated

CT = computed tomography scan.

\*Abdominal CT scanning must be performed at least annually if teratoma is found in the retroperitoneum.

†If the post-chemotherapy evaluation in a seminoma patient shows any mass > 3 cm, the appropriate CT scan should be repeated 2 and 4 months later to ensure that the mass is continuing to regress. If available, FDG-PET scanning can be performed.

‡A chest CT scan is indicated if abnormality is detected on chest X-ray and after pulmonary resection.

§In patients with headaches, focal neurological findings, or any central nervous system symptoms.

## 10. TESTICULAR STROMAL TUMOURS

### 10.1 Background

Testicular stromal tumours are rare and account for only 2-4% of adult testicular tumours. However, only Leydig cell and Sertoli cell tumours are of clinical relevance. As no general recommendations have been published to date, the Testicular Cancer Working Group of the European Association of Urology (EAU) has decided to include these tumours in the EAU Germ Cell Tumour Guidelines. Recommendations for diagnosis and treatment are given only for Leydig and Sertoli cell tumours.

### 10.2 Methods

A Medline search for Leydig cell tumours (synonym: interstitial cell tumour) and Sertoli cell tumours (synonym: androblastoma) was performed. Approximately 850 papers were found. After excluding pure laboratory work without clinical data, female and paediatric tumours and animal cases, 371 papers and abstracts were reviewed. Double publications and papers with unclear histology or missing data on clinical course were excluded. The majority of the remaining 285 publications are case reports, with only a few papers reporting series of more than 10 cases, most of them published in the pathology literature. The true incidence of stromal tumours therefore remains uncertain, and the proportion of metastatic tumours can only be given approximately.

Nevertheless, the symptoms for pre-operative suspicion of testicular stromal tumours and the characteristics of tumours at high risk for metastases are sufficiently well established (EBM: IIA and IIB) to enable recommendations to be made regarding diagnosis and surgical approach. However, no recommendations for appropriate follow-up can be given due to the absence of follow-up data in most reported cases, and the fatal outcome of metastatic tumours, irrespective of the therapy chosen.

The individual publications have been rated according to EBM categories (see above).

The literature research for clinical data on Leydig cell tumours resulted in 193 publications dealing with more than 480 tumours in adults, including three publications (1-3) reporting larger series on a total of 90 patients. Follow-up data of more than 2 years are available for about 80 patients.

The literature research for clinical data on Sertoli cell tumours resulted in 93 publications dealing with more than 260 tumours in adults, including three publications (from the same group) (4-6) reporting on a total of 80 patients. Follow-up data of more than 2 years are available in fewer than 40 patients.

### 10.3 Classification

The non-germ cell tumours of the testicle include the sex cord/gonadal stromal tumours and the miscellaneous non-specific stromal tumours. The different histological subtypes of testicular tumours are defined according to the WHO classification 2004 (adapted) (7).

## 10.4 Leydig cell tumours

### 10.4.1 Epidemiology

Leydig cell tumours constitute about 1-3% of adult testicular tumours (2, 8) and 3% of testicular tumours in infants and children (8). The tumour is most common in the third to sixth decade in adults, with a similar incidence observed in every decade. Another peak incidence is seen in children aged between 3 and 9 years. Only 3% of Leydig cell tumours are bilateral (2). Occasionally, they occur in patients with Klinefelter's syndrome (8).

### 10.4.2 Pathology of Leydig cell tumours

Leydig cell tumours are the most common type of sex cord/gonadal stromal tumours. Histopathologically, they are well outlined and usually up to 5 cm in diameter. They are also solid, coloured yellow to tan, with haemorrhage and/or necrosis present in 30% of cases. Microscopically, the cells are polygonal, with eosinophilic cytoplasm with occasional Reinke crystals, regular nucleus, solid arrangement and capillary stroma. The cells express vimentin, inhibin, protein S-100, steroid hormones, calretinin and cytokeratin (focally) (7).

About 10% of Leydig cell tumours are malignant tumours, which present with the following parameters:

- large size (> 5 cm)
- cytological atypia
- increased mitotic activity (> 3 per 10 high-power field [HPF])
- increased MIB-1 expression (18.6% vs 1.2% in benign)
- necrosis
- vascular invasion (9)
- infiltrative margins
- extension beyond the testicular parenchyma
- DNA aneuploidy (1,10).

### 10.4.3 Diagnosis

Patients either present with a painless enlarged testis or the tumour is an incidental ultrasound finding. In up to 80% of cases, hormonal disorders with high oestrogen and oestradiol levels and low testosterone, increased levels of LH and FSH are reported (11, 12), while negative results are always obtained for the testicular germ cell tumour-markers AFP, hCG, LDH and PLAP. Approximately 30% of patients present with gynaecomastia (13, 14). Only 3% of tumours are bilateral (2). Leydig cell tumours must be distinguished from the multinodular tumour-like and often bilaterally occurring lesions of the androgenital syndrome (15).

Diagnostic work-up must include markers, hormones (at least testosterone, LH and FSH; if not conclusive, additionally oestrogen, oestradiol, progesterone and cortisol), ultrasound of both testes, and CT scan of chest and abdomen. On ultrasound, it may be possible to observe well-defined, small, hypoechoic lesions with hypervascularisation, but the appearance is variable and is indistinguishable from germ cell tumours (16, 17). The proportion of metastatic tumours in all published case reports is only 10%. Within three larger series with longer follow-up, 18 metastatic tumours were found in a total of 83 cases (21.7%) (1-3). Histopathological signs of malignancy have been depicted above (see 4.2) (1, 10). In addition, patients of older age have a greater risk of harbouring a tumour of malignant potential.

### 10.4.4 Treatment

Asymptomatic testicular tumours of small volume are often misinterpreted as germ cell tumours, and inguinal orchidectomy is performed. It is highly recommended to perform an organ-sparing procedure in every small intraparenchymal lesion in order to obtain the histological diagnosis. Especially in patients with symptoms of gynaecomastia or hormonal disorders, a non germ-cell tumour should be considered and immediate orchidectomy avoided (18). In cases of germ cell tumour in either frozen section or paraffin histology, orchidectomy is recommended as long as a contralateral normal testicle is present.

In stromal tumours with histological signs of malignancy, especially in patients of older age, orchidectomy and retroperitoneal lymphadenectomy is recommended to prevent metastases (19). Without histological signs of malignancy, an individualised surveillance strategy after orchidectomy is recommended (CT follow-up may be most appropriate since specific tumour markers are not available).

Tumours that have metastasised to lymph nodes, lung, liver or bone respond poorly to chemotherapy or radiation and survival is poor (19).

#### 10.4.5 Follow-up

Recommendations for appropriate follow-up cannot be given because of the lack of follow-up data in most reported cases and the lethal outcome of metastatic tumours, irrespective of the therapy chosen.

### 10.5 Sertoli cell tumour

#### 10.5.1 Epidemiology

Sertoli cell tumours account for fewer than 1% of testicular tumours, and the mean age at diagnosis is around 45 years, with rare cases under 20 years of age (4, 20). On rare occasions, these tumours may develop in patients with androgen insensitivity syndrome and Peutz-Jeghers syndrome.

#### 10.5.2 Pathology of Sertoli cell tumours

The tumour is well circumscribed, yellow, tan or white, with an average diameter of 3.5 cm (4). Microscopically, the cells are eosinophilic to pale with vacuolated cytoplasm. The nuclei are regular with grooves and there may be inclusions. The arrangement of the cells is tubular or solid; a cord-like or retiform pattern is possible. The stroma is fine and capillary, but in some cases a sclerosing aspect predominates. The cells express vimentin, cytokeratins, inhibin (40%) and protein S-100 (30%) (4).

The rate of malignant tumours ranges between 10% and 22%, and fewer than 50 cases have been reported (21-23). Signs of a malignant Sertoli tumour are:

- large size (> 5 cm)
- pleomorphic nuclei with nucleoli
- increased mitotic activity (> 5 per 10 HPF)
- necrosis
- vascular invasion.

#### 10.5.2.1 Classification

Three subtypes have been described (20):

- the classic Sertoli cell tumour (4)
- the large cell calcifying form with characteristic calcifications (5, 24)
- the rare sclerosing form (6, 25).

#### 10.5.3 Diagnosis

Patients present either with an enlarged testis or the tumour is an incidental ultrasound finding (26). Most classic Sertoli tumours are unilateral and unifocal. Hormonal disorders are infrequent, although gynecomastia is sometimes seen (4). The testicular tumour-markers AFP, hCG, LDH and PLAP are always negative.

Diagnostic work-up must include tumour markers, hormones (at least testosterone, LH and FSH; if not conclusive, additionally oestrogen, oestradiol, progesterone and cortisol), ultrasound of both testes and CT scan of chest and abdomen.

Sertoli cell tumours are generally hypoechoic on ultrasound, but they can be of variant appearance and therefore cannot be safely distinguished from germ cell tumours (20). Only the large cell calcifying form has a characteristic image with brightly echogenic foci due to calcification (27, 28).

The large cell calcifying form is diagnosed in younger men and is associated with genetic syndromes (Carney's complex [29] and Peutz-Jeghers syndrome [30]) or, in about 40% of cases, endocrine disorders. A total of 44% of cases are bilateral, either synchronous or metachronous, and 28% show multifocality (24).

The characteristics of metastatic tumours have been depicted above (24, 25). However, among patients whose tumours have been histopathologically classified as 'malignant' using these or similar characteristics (i.e. 18.8% of tumours in all reported cases), only 7% showed metastatic disease during follow-up.

In the largest series with the longest follow-up, 7.5% of patients had been classified as 'malignant' at primary diagnosis and 11.7% showed metastatic disease long-term (4). In general, affected patients are of higher age, tumours are nearly always palpable, and show more than one sign of malignancy (4).

Up to 20% of the large cell sclerosing form are malignant. There are some hints that discrimination between an early and late onset type may define a different risk for metastatic disease (5.5% compared with 23%) (20). Metastases in the infrequent sclerosing subtype are rare.

#### 10.5.4 Treatment

Testicular tumours of small volume, otherwise asymptomatic, are often misinterpreted as germ cell tumours and inguinal orchidectomy is performed. It is highly recommended to proceed with an organ-sparing approach in small intraparenchymal testicular lesions until final histology is available. Especially in patients with symptoms of gynecomastia or hormonal disorders or typical imaging on ultrasound (calcifications, small circumscribed tumours), organ-sparing surgery should be considered. Secondary orchidectomy can be performed if final pathology reveals a non-stromal (e.g. germ cell) tumour. Organ-sparing surgical approaches are justified as long as the remaining testicular parenchyma is sufficient for endocrine (and in stromal tumours also exocrine) function.

In tumours with histological signs of malignancy, especially in patients of older age, orchidectomy and retroperitoneal lymphadenectomy are recommended to prevent metastases (19). Without signs of malignancy, an individualised surveillance strategy after orchidectomy is recommended (CT scans may be most appropriate since specific tumour-markers are not available). Tumours metastasising to lymph nodes, lung or bone respond poorly to chemotherapy or radiation, and survival is poor.

#### 10.5.5 Follow-up

Recommendations for appropriate follow-up cannot be given because of the lack of follow-up data in most reported cases and the lethal outcome of metastatic tumours, irrespective of the therapy chosen.

### 10.6 Granulosa cell tumour

This is a rare tumour, with two variants: juvenile and adult.

- The juvenile type is benign. It is the most frequent congenital testicle tumour and represents 6.6% of all prepubertal testicular neoplasms. The cystic appearance is characteristic of this tumour type (31).
- With the adult type, the average age at presentation is 44 years. The typical morphology is of a homogeneous, yellow-grey tumour, with elongated cells with grooves in microfollicular and Call-Exner body arrangements.

Malignant tumours represent around 20% of cases. They are usually > 7 cm diameter. Vascular invasion and necrosis are features suggestive of malignant biology (32).

### 10.7 Thecoma/fibroma group of tumours

These tumours are very rare and benign (7).

### 10.8 Other sex cord/gonadal stromal tumours

Sex cord/gonadal stromal tumours may be incompletely differentiated or mixed forms.

There is limited experience with incompletely differentiated sex cord/gonadal stromal tumours and no cases of reported metastasis (7). In mixed tumour forms, all the histological components should be reported. However, the clinical behaviour is most likely to reflect the predominant pattern or the most aggressive component of the tumour (33)

### 10.9 Tumours containing germ cell and sex cord/gonadal stromal (gonadoblastoma)

If the arrangement of the germ cells are in a nested pattern and the rest of the tumour is composed of sex cord/gonadal stroma, the term gonadoblastoma is used. It is most frequent in gonadal dysgenesis with ambiguous genitalia. Bilateral tumours are present in 40% of cases. The prognosis is correlated with the invasive growth of the germinal component (34).

In the case of a diffuse arrangement of the different components, there are some doubts about the neoplastic nature of the germinal cells and some authors consider them to be entrapped rather than neoplastic (35).

### 10.10 Miscellaneous tumours of the testis

#### 10.10.1 Tumours of ovarian epithelial types

These tumours resemble the epithelial tumours of the ovary. A cystic appearance with occasional mucinous material can be observed. Microscopically, the aspect is identical to their ovarian counterparts, and their evolution is similar to that of the different epithelial ovarian subtypes. Some Brenner types can be malignant (7).

#### 10.10.2 Tumours of the collecting ducts and rete testis

These tumours are very rare. Benign (adenoma) and malignant (adenocarcinoma) have been reported, with malignant tumours showing local growth with a mortality rate of 56% (18).

### 10.10.3 Tumours (benign and malignant) of non-specific stroma

These are very uncommon and have a similar criteria, prognosis and treatment as do the soft tissue sarcomas.

## 11 REFERENCES

### 11.1 Germ cell tumours

1. Richie JP. Neoplasms of the testis, in Walsh PC et al. (eds). *Campbell's Urology*. 7th ed. Philadelphia: Saunders, 1997: pp. 2411-2452.
2. Schottenfeld D, Warshauer ME, Sherlock S, Zauber AG, Leder M, Payne R. The epidemiology of testicular cancer in young adults. *Am J Epidemiol* 1980;112(2):232-46.  
<http://www.ncbi.nlm.nih.gov/pubmed/6106385>
3. Huyghe E, Matsuda T, Thonneau P. Increasing incidence of testicular cancer worldwide: a review. *J Urol* 2003;170(1):5-11.  
<http://www.ncbi.nlm.nih.gov/pubmed/12796635>
4. McGlynn KA, Devesa SS, Sigurdson AJ, Brown LM, Tsao L, Tarone RE. Trends in the incidence of testicular germ cell tumours in the United States. *Cancer* 2003;97(1):63-70.  
<http://www.ncbi.nlm.nih.gov/pubmed/12491506>
5. Bosl GJ, Motzer RJ. Testicular germ-cell cancer. *N Engl J Med* 1997;337(4):242-53.  
<http://www.ncbi.nlm.nih.gov/pubmed/9227931>
6. Kuczyk MA, Serth J, Bokemeyer C, Jonassen J, Machtens S, Werner M, Jonas U. Alterations of the p53 tumour suppressor gene in carcinoma in situ of the testis. *Cancer* 1996;78(9):1958-66.  
<http://www.ncbi.nlm.nih.gov/pubmed/8909317>
7. Looijenga LH, Gillis AJ, Stoop H, Hersmus R, Oosterhuis JW. Relevance of microRNAs in normal and malignant development, including human testicular germ cell tumours. *Int J Androl* 2007;30(4):304-14; discussion 314-15.  
<http://www.ncbi.nlm.nih.gov/pubmed/17573854>
8. Reuter VE. Origins and molecular biology of testicular germ cell tumors. *Mod Pathol* 2005;18(Suppl 2):S51-S60.  
<http://www.ncbi.nlm.nih.gov/pubmed/15761466>
9. Osterlind A, Berthelsen JG, Abildgaard N, Hansen SO, Hjalgrim H, Johansen B, Munck-Hansen J, Rasmussen LH. Risk of bilateral testicular germ cell tumours in Denmark: 1960-1984. *J Natl Cancer Inst* 1991;83(19):1391-5.  
<http://www.ncbi.nlm.nih.gov/pubmed/1656057>
10. Moller H, Prener A, Skakkebaek NE. Testicular cancer, cryptorchidism, inguinal hernia, testicular atrophy and genital malformations: case-control studies in Denmark. *Cancer Causes Control* 1996;7(2):264-74.  
<http://www.ncbi.nlm.nih.gov/pubmed/8740739>
11. Dieckmann KP, Pichlmeier U. The prevalence of familial testicular cancer. *Cancer* 1997;80(10):1954-60.  
<http://www.ncbi.nlm.nih.gov/pubmed/9366298>
12. Forman D, Oliver RT, Brett AR, Marsh SG, Moses JH, Bodmer JG, Chilvers CE, Pike MC. Familial testicular cancer: a report of the UK family register, estimation of risk and a HLA class 1 sib-pair analysis. *Br J Cancer* 1992;65(2):255-62.  
<http://www.ncbi.nlm.nih.gov/pubmed/1739626>
13. Weestergaard T, Olsen JH, Frisch M, Kroman N, Nielsen JW, Melbye M. Cancer risk in fathers and brothers of testicular cancer patients in Denmark. A population based study. *Int J Cancer* 1996;66(5):627-31.  
<http://www.ncbi.nlm.nih.gov/pubmed/8647624>
14. Dieckmann KP, Loy V, Buttner P. Prevalence of bilateral germ cell tumours and early detection based on contralateral testicular intra-epithelial neoplasia. *Br J Urol* 1993;71(3):340-5.  
<http://www.ncbi.nlm.nih.gov/pubmed/8386582>
15. Dieckmann KP, Pichlmeier U. Is risk of testicular cancer related to the body size? *Eur Urol* 2002;42(6):564-9.  
<http://www.ncbi.nlm.nih.gov/pubmed/12477651>
16. Wanderas EH, Tretli S, Fossa SD. Trends in incidence of testicular cancer in Norway 1955-1992. *Eur J Cancer* 1995;31A(12):2044-8.  
<http://www.ncbi.nlm.nih.gov/pubmed/8562163>

17. Jones A, Fergus JN, Chapman J, Houghton L. Is surveillance for stage I germ cell tumours of the testis appropriate outside a specialist centre? *BJU Int* 1999;84(1):79-84.  
<http://www.ncbi.nlm.nih.gov/pubmed/10444129>
18. Collette L, Sylvester RJ, Stenning SP, Fossa SD, Mead GM, de Wit R, de Mulder PH, Ney Lallemand E, Kaye SB. Impact of the treating institution on survival of patients with poor-prognosis non-seminoma. European Organization for Research and Treatment of Cancer Genitourinary Tract Cancer Collaborative Group and the Medical Research Council Testicular Working Party. *J Natl Cancer Inst* 1999;91(10):839-46.  
<http://www.ncbi.nlm.nih.gov/pubmed/10340903>
19. Albers P, Albrecht W, Algaba F, Bokemeyer C, Cohn-Cedermark G, Horwich A, Klepp O, Laguna MP, Pizzocaro G. Guidelines on testicular cancer. *Eur Urol* 2005;48(6):885-94.  
<http://www.ncbi.nlm.nih.gov/pubmed/16126333>
20. Warde P, Specht L, Horwich A, Oliver T, Panzarella T, Gospodarowicz M, von der Maase H. Prognostic factors for relapse in stage I seminoma managed by surveillance: a pooled analysis. *J Clin Oncol* 2002;20(22):4448-52.  
<http://www.ncbi.nlm.nih.gov/pubmed/12431967>
21. Shelley MD, Burgon K, Mason MD. Treatment of testicular germ-cell cancer: a cochrane evidence-based systematic review. *Cancer Treat Rev* 2002;28(5):237-53.  
<http://www.ncbi.nlm.nih.gov/pubmed/12435371>
22. Krege S, Beyer J, Souchon R, Albers P, Albrecht W, Algaba F, Bamberg M, Bodrogi I, Bokemeyer C, Cavallin-Ståhl E, Classen J, Clemm C, Cohn-Cedermark G, Culine S, Daugaard G, De Mulder PH, De Santis M, de Wit M, de Wit R, Derigs HG, Dieckmann KP, Dieing A, Droz JP, Fenner M, Fizazi K, Flechon A, Fosså SD, del Muro XG, Gauler T, Geczi L, Gerl A, Germa-Lluch JR, Gillessen S, Hartmann JT, Hartmann M, Heidenreich A, Hoeltl W, Horwich A, Huddart R, Jewett M, Joffe J, Jones WG, Kisbenedek L, Klepp O, Kliesch S, Koehrmann KU, Kollmannsberger C, Kuczyk M, Laguna P, Galvis OL, Loy V, Mason MD, Mead GM, Mueller R, Nichols C, Nicolai N, Oliver T, Ondrus D, Oosterhof GO, Ares LP, Pizzocaro G, Pont J, Pottek T, Powles T, Rick O, Rosti G, Salvioni R, Scheiderbauer J, Schmelz HU, Schmidberger H, Schmoll HJ, Schrader M, Sedlmayer F, Skakkebaek NE, Sohaib A, Tjulandin S, Warde P, Weinknecht S, Weissbach L, Wittekind C, Winter E, Wood L, von der Maase H. European consensus conference on diagnosis and treatment of germ cell cancer: a report of the second meeting of the European Germ Cell Cancer Consensus group (EGCCCG): part I. *Eur Urol*. 2008 Mar;53(3):478-96.  
<http://www.ncbi.nlm.nih.gov/pubmed/18191324>
23. Krege S, Beyer J, Souchon R, Albers P, Albrecht W, Algaba F, Bamberg M, Bodrogi I, Bokemeyer C, Cavallin-Ståhl E, Classen J, Clemm C, Cohn-Cedermark G, Culine S, Daugaard G, De Mulder PH, De Santis M, de Wit M, de Wit R, Derigs HG, Dieckmann KP, Dieing A, Droz JP, Fenner M, Fizazi K, Flechon A, Fosså SD, del Muro XG, Gauler T, Geczi L, Gerl A, Germa-Lluch JR, Gillessen S, Hartmann JT, Hartmann M, Heidenreich A, Hoeltl W, Horwich A, Huddart R, Jewett M, Joffe J, Jones WG, Kisbenedek L, Klepp O, Kliesch S, Koehrmann KU, Kollmannsberger C, Kuczyk M, Laguna P, Galvis OL, Loy V, Mason MD, Mead GM, Mueller R, Nichols C, Nicolai N, Oliver T, Ondrus D, Oosterhof GO, Paz-Ares L, Pizzocaro G, Pont J, Pottek T, Powles T, Rick O, Rosti G, Salvioni R, Scheiderbauer J, Schmelz HU, Schmidberger H, Schmoll HJ, Schrader M, Sedlmayer F, Skakkebaek NE, Sohaib A, Tjulandin S, Warde P, Weinknecht S, Weissbach L, Wittekind C, Winter E, Wood L, von der Maase H. European consensus conference on diagnosis and treatment of germ cell cancer: a report of the second meeting of the European Germ Cell Cancer Consensus Group (EGCCCG): part II. *Eur Urol* 2008 Mar;53(3):497-513.  
<http://www.ncbi.nlm.nih.gov/pubmed/18191015>
24. Deutsche Krebsgesellschaft: Leitlinie zur Diagnostik und Therapie von Hodentumouren auf Grundlage evidenzbasierter Medizin (EBM). Souchon R, Schmoll HJ, Krege S, for the German Testicular Cancer Study Group (eds). *Qualitätsicherung in der Onkologie*. 1st edn. München-Bern-Wien-New York-Zuckschwerdt, 2002. [German Cancer Society: Evidence-based guideline for the assessment and treatment of testicular tumours] [article in German]
25. The Royal College of Radiologists' Clinical Oncology Network in partnership with Scottish Intercollegiate Network 2000. Guidelines on the management of adult testicular germ cell tumours. *Clin Oncol (R Coll Radiol)* 2000;12(5):S173-S210.  
<http://www.ncbi.nlm.nih.gov/pubmed/11315727>
26. Diagnostiek en behandeling van kiemceltumouren van de testis. Richtlijnen Nederlandse Vereniging voor urologie. No 14. [Diagnosis and treatment of testicular germ cell tumours. Dutch Urological Society guidelines] [article in Dutch]

27. Segal R, Lukka H, Klotz LH, Eady A, Bestic N, Johnston M; Cancer Care Ontario Practice Guidelines Initiative Genitourinary Cancer Disease Site Group. Surveillance programs for early stage nonseminomatous testicular cancer: a practice guideline. *Can J Urol* 2001;8(1):1184-92.  
<http://www.ncbi.nlm.nih.gov/pubmed/11268306>
28. Oxford Centre for Evidence-based Medicine Levels of Evidence (May 2001). Produced by Bob Phillips, Chris Ball, Dave Sackett, Doug Badenoch, Sharon Straus, Brian Haynes, Martin Dawes since November 1998.  
<http://www.cebm.net/index.aspx?o=1025> [accessed February 2009].
29. WHO histological classification of testis tumours, In: Eble JN, Sauter G, Epstein JI, Sesterhenn IA, eds. *Pathology & Genetics. Tumours of the urinary system and male genital organs*. Lyons: IARC Press, 2004: 218, pp. 250-262.
30. Germa-Lluch JR, Garcia del Muro X, Maroto P, Paz-Ares L, Arranz JA, Guma J, Alba E, Satre J, Aparicio J, Fernandez A, Barnadas A, Terrassa J, Saenz A, Almenar D, Lopez-Brea M, Climent MA, Sanchez MA, Lasso de la Vega R, Berenguer G, Perez X; Spanish Germ-Cell Cancer Group (GG). Clinical pattern and therapeutic results achieved in 1490 patients with germ-cell tumours of the testis: the experience of the Spanish Germ-Cell Cancer Group (GG). *Eur Urol* 2002;42(6):553-62.  
<http://www.ncbi.nlm.nih.gov/pubmed/12477650>
31. Skakkebaek NE. Possible carcinoma-in-situ of the testis. *Lancet* 1972;2(7776):516-7.  
<http://www.ncbi.nlm.nih.gov/pubmed/4115573>
32. Richie JP, Birnholz J, Garnick MB. Ultrasonography as a diagnostic adjunct for the evaluation of masses in the scrotum. *Surg Gynecol Obstet* 1982;154(5):695-8.  
<http://www.ncbi.nlm.nih.gov/pubmed/7071705>
33. Doherty FJ. Ultrasound of the nonacute scrotum, in Raymond HW et al. (eds). *Seminars in Ultrasound, CT and MRI*. New York: WB Saunders, 1991, pp. 131-156.
34. Comiter CU, Benson CJ, Capelouto CC, Kantoff P, Shulman L, Richie JP, Loughlin KR. Nonpalpable intratesticular masses detected sonographically. *J Urol* 1995;154(4):1367-9.  
<http://www.ncbi.nlm.nih.gov/pubmed/7658540>
35. Friedrich M, Claussen CD, Felix R. Immersion ultrasound of testicular pathology. *Radiology* 1981;141(1):235-7.  
<http://www.ncbi.nlm.nih.gov/pubmed/7291531>
36. Glazer HS, Lee JKT, Melson GL, McClennan BL. Sonographic detection of occult testicular neoplasm. *ARJ Am J Roentgenol* 1982;138(4):673-5.  
<http://www.ncbi.nlm.nih.gov/pubmed/6978030>
37. Bockrath JM, Schaeffer AJ, Kiess MS, Nieman HL. Ultrasound Identification of impalpable testicle tumour. *J Urol* 1983;130(2):355-6.  
<http://www.ncbi.nlm.nih.gov/pubmed/6876291>
38. Shawker TH, Javadpour N, O'Leary T, Shapiro E, Krudy AG. Ultrasonographic detection of 'burned-out' primary testicular germ cell tumours in clinically normal testes. *J Ultrasound Med* 1983;2(10):477-9.  
<http://www.ncbi.nlm.nih.gov/pubmed/6313958>
39. Lenz S, Giwercman A, Skakkebaek NE, Bruun E, Frimodt-Moller C. Ultrasound in detection of early neoplasia of the testis. *Int J Androl* 1987;10(1):187-90.  
<http://www.ncbi.nlm.nih.gov/pubmed/2884185>
40. Thurnher S, Hricak H, Carroll PR, Pobielski RS, Filly RA. Imaging the testis: comparison between MR imaging and US. *Radiology* 1988;167(3):631-6.  
<http://www.ncbi.nlm.nih.gov/pubmed/3283834>
41. Mattrey RF. Magnetic resonance imaging of the scrotum. *Semin Ultrasound CT MR* 1991;12(2):95-108.  
<http://www.ncbi.nlm.nih.gov/pubmed/1863480>
42. Rholl KS, Lee JKT, Ling D, Heiken JP, Glazer HS. MR imaging of the scrotum with a high resolution surface coil. *Radiology* 1987;163(1):99-103.  
<http://www.ncbi.nlm.nih.gov/pubmed/3547497>
43. Johnson JO, Mattrey RF, Phillipson J. Differentiation of seminomatous from nonseminomatous testicular tumours by MRI. *AJR Am J Roentgenol* 1990;154(3):539-43.  
<http://www.ncbi.nlm.nih.gov/pubmed/2106218>
44. Klein EA. Tumour markers in testis cancer. *Urol Clin North Am* 1993;20(1):67-73.  
<http://www.ncbi.nlm.nih.gov/pubmed/7679533>
45. Peyret C. Tumeurs du testicule. Synthèse et recommandations en onco-urologie. *Prog Urol* 1993;2:60-4. [Testicular tumours. Summary of onco-urological recommendations] [article in French]

46. Javadpour N. The role of biologic markers in testicular cancer. *Cancer* 1980;45(7 Suppl):1755-61.  
<http://www.ncbi.nlm.nih.gov/pubmed/6154517>
47. Heidenreich A, Weissbach L, Holth W, Albers P, Kliesch S, Kohrmann KU, Dieckmann KP. German Testicular Cancer Study Group. Organ sparing surgery for malignant germ cell tumour of the testis. *J Urol* 2001;166(6):2161-5.  
<http://www.ncbi.nlm.nih.gov/pubmed/11696727>
48. Petersen PM, Giwercman A, Daugaard G, Rorth M, Petersen JH, Skakkebaek NE, Hansen SW, von der Maase H. Effect of graded testicular doses of radiotherapy in patients treated for carcinoma-in-situ in the testis. *J Clin Oncol* 2002;20(6):1537-43.  
<http://www.ncbi.nlm.nih.gov/pubmed/11896102>
49. Heidenreich A, Holtl W, Albrecht W, Pont J, Engelmann UH. Testis-preserving surgery in bilateral testicular germ cell tumours. *Br J Urol* 1997;79(2):253-7.  
<http://www.ncbi.nlm.nih.gov/pubmed/9052478>
50. Weissbach L. Organ preserving surgery of malignant germ cell tumours. *J Urol* 1995;153(1):90-3.  
<http://www.ncbi.nlm.nih.gov/pubmed/7966800>
51. Dieckmann KP, Loy V. Prevalence of contralateral testicular intraepithelial neoplasia in patients with testicular germ cell neoplasms. *J Clin Oncol* 1996;14(12):3126-32.  
<http://www.ncbi.nlm.nih.gov/pubmed/8955658>
52. Von der Maase H, Rorth M, Walbom-Jorgensen S, Sorensen BL, Christophersen IS, Hald T, Jacobsen GK, Berthelsen JG, Skakkebaek NE. Carcinoma-in-situ of contralateral testis in patients with testicular germ cell cancer: study of 27 cases in 500 patients. *Br Med J (Clin Res Ed)* 1986; 293(6559):1398-401.  
<http://www.ncbi.nlm.nih.gov/pubmed/3026550>
53. Harland SJ, Cook PA, Fossa SD, Horwich A, Mead GM, Parkinson MC, Roberts JT, Stenning SP. Intratubular germ cell neoplasia of contralateral testis in testicular cancer: defining a high risk group. *J Urol* 1998;160(4):1353-7.  
<http://www.ncbi.nlm.nih.gov/pubmed/9751353>
54. Taberner J, Paz-Ares L, Salazar R, Lianes P, Guerra J, Borrás J, Villavicencio H, Leiva O, Cortes-Funes H. Incidence of contralateral germ cell testicular tumours in South Europe: report of the experience at 2 Spanish university hospitals and review of the literature. *J Urol* 2004;171(1):164-7.  
<http://www.ncbi.nlm.nih.gov/pubmed/14665868>
55. Herr HW, Sheinfeld J. Is biopsy of the contralateral testis necessary in patients with germ cell tumors? *J Urol* 1997;158(4):1331-4.  
<http://www.ncbi.nlm.nih.gov/pubmed/9302113>
56. Albers P, Goll A, Bierhoff E, Schoeneich G, Muller SC. Clinical course and histopathologic risk factor assessment in patients with bilateral testicular germ cell tumours. *Urology* 1999;54(4):714-8.  
<http://www.ncbi.nlm.nih.gov/pubmed/10510934>
57. Giwercman A, Bruun E, Frimotd-Muller C, Skakkebaek NE. Prevalence of carcinoma in situ and other histopathological abnormalities in testes of men with a history of cryptorchidism. *J Urol* 1989;142(4):998-1001.  
<http://www.ncbi.nlm.nih.gov/pubmed/2571738>
58. Heidenreich A, Moul JW. Contralateral testicular biopsy procedure in patients with unilateral testis cancer: is it indicated? *Sem Urol Oncol* 2002;20(4):234-8.  
<http://www.ncbi.nlm.nih.gov/pubmed/12489055>
59. Dieckmann KP, Kulejewski M, Pichlmeier U, Loy V. Diagnosis of contralateral testicular intraepithelial neoplasia (TIN) in patients with testicular germ cell cancer: systematic two-site biopsies are more sensitive than a single random biopsy. *Eur Urol* 2007;51(1):175-83; discussion 183-5.  
<http://www.ncbi.nlm.nih.gov/pubmed/16814456>
60. Kliesch S, Thomaidis T, Schütte B, Puhse G, Kater B, Roth S, Bergmann M. Update on the diagnostic safety for detection of testicular intraepithelial neoplasia (TIN). *APMIS* 2003;111(1):70-4.  
<http://www.ncbi.nlm.nih.gov/pubmed/12752238>
61. Classen J, Dieckmann K, Bamberg M, Souchon R, Kliesch S, Kuehn M, Loy V; German Testicular Cancer Study Group. Radiotherapy with 16 Gy may fail to eradicate testicular intraepithelial neoplasia: preliminary communication of a dose-reduction trial of the German Testicular Cancer Study Group. *Br J Cancer* 2003;88(6):828-31.  
<http://www.ncbi.nlm.nih.gov/pubmed/12644817>
62. Leibovitch I, Foster RS, Kopecky KK, Donohue JP. Improved accuracy of computerized tomography based clinical staging in low stage nonseminomatous germ cell cancer using size criteria of retroperitoneal lymph nodes. *J Urol* 1995;154(5):1759-63.  
<http://www.ncbi.nlm.nih.gov/pubmed/7563341>

63. Jing B, Wallace S, Zornoza J. Metastases to retroperitoneal and pelvic lymph nodes: computed tomography and lymphangiography. *Radiol Clin North Am* 1982;20(3):511-30.  
<http://www.ncbi.nlm.nih.gov/pubmed/7051132>
64. Husband JE, Barrett A, Peckham MJ. Evaluation of computed tomography in the management of testicular teratoma. *Br J Urol* 1981;53(2):179-83.  
<http://www.ncbi.nlm.nih.gov/pubmed/7237052>
65. Swanson DA. Role of retroperitoneal lymphadenectomy (RLDN) when patients with nonseminomatous germ cell testicular tumours are at high risk of needing lymph node surgery plus chemotherapy, in Donohue JP (ed.). *Lymph Node Surgery in Urology*. International Society of Urology Reports. Oxford: Isis Medical Media, 1995, pp. 133-140.
66. Ellis JH, Blies JR, Kopecky KK, Klatte EC, Rowland RG, Donohue JP. Comparison of NMR and CT imaging in the evaluation of metastatic retroperitoneal lymphadenopathy from testicular carcinoma. *J Comput Assist Tomogr* 1984;8(4):709-9.  
<http://www.ncbi.nlm.nih.gov/pubmed/6539790>
67. See WA, Hoxie L. Chest staging in testis cancer patients: imaging modality selection based upon risk assessment as determined by abdominal computerized tomography scan results. *J Urol* 1993;150(3):874-8.  
<http://www.ncbi.nlm.nih.gov/pubmed/8345604>
68. Cremerius U, Wildberger JE, Borchers H, Zimny M, Jakse G, Gunther RW, Buell U. Does positron emission tomography using 18-fluoro-2-deoxyglucose improve clinical staging of testicular cancer?—Results of a study in 50 patients. *Urology* 1999;54(5):900-4.  
<http://www.ncbi.nlm.nih.gov/pubmed/10565755>
69. Albers P, Bender H, Yilmaz H, Schoeneich G, Biersack HJ, Mueller SC. Positron emission tomography in the clinical staging of patients with Stage I and II testicular germ cell tumours. *Urology* 1999;53(4):808-11.  
<http://www.ncbi.nlm.nih.gov/pubmed/10197862>
70. De Santis M, Becherer A, Bokemeyer C, Stoiber F, Oechsle K, Sellner F, Lang A, Kletter K, Dohmen BM, Dittrich C, Pont J. 2-18fluoro-deoxy-D-glucose positron emission tomography is a reliable predictor for viable tumor in postchemotherapy seminoma: an update of the prospective multicentric SEMPET trial. *J Clin Oncol* 2004;22(6):1034-9.  
<http://www.ncbi.nlm.nih.gov/pubmed/15020605>
71. Spermon JR, De Geus-Oei LF, Kiemeney LA, Witjes JA, Oyen WJ. The role of (18)fluoro-2-deoxyglucose positron emission tomography in initial staging and re-staging after chemotherapy for testicular germ cell tumours. *BJU Int*, 2002;89(6):549-56.  
<http://www.ncbi.nlm.nih.gov/pubmed/11942962>
72. Sobin LH, Wittekind C (eds). *TNM classification of malignant tumours*. 6th edn. UICC/Wiley, 2002.  
<http://www.wiley.com/>
73. Zagars GK. Management of stage I seminoma: radiotherapy, in Horwich A (ed.). *Testicular Cancer: Investigation and Management*. London: Chapman & Hall Medical, 1999, p. 99.
74. Klepp O, Flodgren P, Maartman-Moe H, Lindholm CE, Unsgaard B, Teigum H, Fossa SD, Paus E. Early clinical stages (CS1, CS1Mk+ and CS2A) of non-seminomatous testis cancer. Value of pre- and postorchidectomy serum tumour marker information in prediction of retroperitoneal lymph node metastases. Swedish-Norwegian Testicular Cancer Project (SWENOTECA). *Ann Oncol* 1990;1(4): 281-8.  
<http://www.ncbi.nlm.nih.gov/pubmed/1702312>
75. International Germ Cell Cancer Collaborative Group. International Germ Cell Consensus Classification: a prognostic factor-based staging system for metastatic germ cell cancers. *J Clin Oncol* 1997;15(2):594-603.  
<http://www.ncbi.nlm.nih.gov/pubmed/9053482>
76. Bokemeyer C, Schmoll HJ. Treatment of clinical stage I testicular cancer and a possible role for new biological prognostic parameters. *J Cancer Res Clin Oncol* 1996;122:575-84.
77. Albers P, Siener R, Kliesch S, Weissbach L, Kregel S, Sparwasser C, Schulze H, Heidenreich A, de Riese W, Loy V, Bierhoff E, Wittekind C, Fimmers R, Hartmann M; German Testicular Cancer Study Group. Risk factors for relapse in clinical stage I nonseminomatous testicular germ cell tumours: results of the German Testicular Cancer Study Group Trial. *J Clin Oncol* 2003;21(8):1505-12.  
<http://www.ncbi.nlm.nih.gov/pubmed/12697874>
78. Petersen PM, Giwercman A, Skakkebaek NE, Rorth M. Gonadal function in men with testicular cancer. *Semin Oncol* 1998;25(2):224-33.  
<http://www.ncbi.nlm.nih.gov/pubmed/9562456>

79. De Santis M, Albrecht W, Holtl W, Pont J. Impact of cytotoxic treatment on long-term fertility in patients with germ-cell cancer. *Int J Cancer* 1999;83(6):864-5.  
<http://www.ncbi.nlm.nih.gov/pubmed/10597213>
80. Jacobsen KD, Fossa SD, Bjoro TP, Aass N, Heilo A, Stenwig AE. Gonadal function and fertility in patients with bilateral testicular germ cell malignancy. *Eur Urol* 2002;42(3):229-38.  
<http://www.ncbi.nlm.nih.gov/pubmed/12234507>
81. Kliesch S, Behre HM, Jurgens H, Nieschlag E. Cryopreservation of semen from adolescent patients with malignancies. *Med Pediatr Oncol* 1996;26(1):20-7.  
<http://www.ncbi.nlm.nih.gov/pubmed/7494508>
82. Giwercman A, von der Maase H, Rorth M, Skakkebaek NE. Semen quality in testicular tumour and CIS in the contralateral testis. *Lancet* 1993;341(8841):384-5.  
<http://www.ncbi.nlm.nih.gov/pubmed/8094162>
83. Kliesch S, Bergmann M, Hertle L, Nieschlag E, Behre HM. Semen parameters and testicular pathology in men with testicular cancer and contralateral carcinoma in situ or bilateral testicular malignancies. *Hum Reprod* 1997;12(12):2830-35.  
<http://www.ncbi.nlm.nih.gov/pubmed/9455863>
84. Spermon JR, Kiemeny LA, Meuleman EJ, Ramos L, Wetzels AM, Witjes JA. Fertility in men with testicular germ cell tumours. *Fertil Steril* 2003;79(Suppl 3):1543-9.  
<http://www.ncbi.nlm.nih.gov/pubmed/12801557>
85. Nieschlag E, Behre HM. Pharmacology and clinical use of testosterone, in Nieschlag E, Behre HM (eds). *Testosterone-Action, Deficiency, Substitution*. Berlin-Heidelberg-New York: Springer, 1999, pp. 92-114.
86. Sternberg CN. The management of stage I testis cancer. *Urol Clin North Am* 1998 Aug;25(3):435-49.  
<http://www.ncbi.nlm.nih.gov/pubmed/9728213>
87. Groll RJ, Warde P, Jewett MA. A comprehensive systematic review of testicular germ cell tumor surveillance. *Crit Rev Oncol Hematol* 2007;64(3):182-97.  
<http://www.ncbi.nlm.nih.gov/pubmed/17644403>
88. Chung P, Parker C, Panzarella T, Gospodarowicz MK, Jewett S, Milosevic MF, Catton CN, Bayley AJ, Tew-George B, Moore M, Sturgeon JF, Warde P. Surveillance in stage I testicular seminoma-risk of late relapse. *Can J Urol* 2002;9(5):1637-40.  
<http://www.ncbi.nlm.nih.gov/pubmed/12431325>
89. Warde P, Jewett MAS. Surveillance for stage I testicular seminoma. Is it a good option? *Urol Clin North Am* 1998;25(3):425-33.  
<http://www.ncbi.nlm.nih.gov/pubmed/9728212>
90. Aparicio J, Garcia del Muro X, Maroto P, Paz-Ares L, Alba E, Saenz A, Terrasa J, Barnadas A, Almenar D, Arranz JA, Sanchez M, Fernandez A, Sastre J, Carles J, Dorca J, Guma J, Yuste AL, Germa JR; Spanish Germ Cell Cancer Cooperative Group (GG). Multicenter study evaluating a dual policy of postorchidectomy surveillance and selective adjuvant single-agent carboplatin for patients with clinical stage I seminoma. *Ann Oncol* 2003;14(6):867-72.  
<http://www.ncbi.nlm.nih.gov/pubmed/12796024>
91. Sharda N, Kinsella T, Ritter M. Adjuvant radiation versus observation: a cost analysis of alternate management schemes in earlystage testicular seminoma. *J Clin Oncol* 1996;14(11):2933-9.  
<http://www.ncbi.nlm.nih.gov/pubmed/8918490>
92. Francis R, Bower M, Brunstrom G, Holden L, Newlands ES, Rustin GJS, Seckl MJ. Surveillance for stage I testicular germ cell tumours: results and cost benefit analysis of management options. *Eur J Cancer* 2000;36(15):1925-32.  
<http://www.ncbi.nlm.nih.gov/pubmed/11000572>
93. Warde P, Gospodarowicz M, Panzarella T, Catton C, Sturgeon J, Moore M, Jewett M. Issues in the management of stage I testicular seminoma. *Int J Radiat Oncol Biol Phys* 1997;39:S156.
94. Oliver RT, Mason MD, Mead GM, von der Maase H, Rustin GJ, Joffe JK, de Wit R, Aass N, Graham JD, Coleman R, Kirk SJ, Stenning SP; MRC TE19 collaborators and the EORTC 30982 collaborators. Radiotherapy versus single-dose carboplatin in adjuvant treatment of stage I seminoma: a randomised trial. *Lancet* 2005;23-29;366(9482):293-300.  
<http://www.ncbi.nlm.nih.gov/pubmed/16039331>
95. Aparicio J, Germà JR, García del Muro X, Maroto P, Arranz JA, Sáenz A, Barnadas A, Dorca J, Gumà J, Olmos D, Bastús R, Carles J, Almenar D, Sánchez M, Paz-Ares L, Satrustegui JJ, Mellado B, Balil A, López-Brea M, Sánchez A; The Second Spanish Germ Cell Cancer Cooperative Group. Risk-adapted management for patients with clinical stage I seminoma: the Second Spanish Germ Cell Cancer Cooperative Group study. *J Clin Oncol* 2005;23(34):8717-23.  
<http://www.ncbi.nlm.nih.gov/pubmed/16260698>

96. Schoffski P, Höhn N, Kowalski R, Classen J, Meisner C, Fechner G, Dieckmann K, Winkler C, Bamberg M. Health-related quality of life (QoL) in patients with seminoma stage I treated with either adjuvant radiotherapy (RT) or two cycles of carboplatinum chemotherapy (CT): Results of a randomized phase III trial of the German Interdisciplinary Working Party on Testicular Cancer. ASCO Annual Meeting Proceedings. Part 1. J Clin Oncol 2007;25(Suppl 18S):5050.  
[http://www.asco.org/portal/site/ASCO/menuitem.34d60f5624ba07fd506fe310ee37a01d/?vgnnextoid=76f8201eb61a7010VgnVCM100000ed730ad1RCRD&vmview=abst\\_detail\\_view&confID=47&abstractID=32158](http://www.asco.org/portal/site/ASCO/menuitem.34d60f5624ba07fd506fe310ee37a01d/?vgnnextoid=76f8201eb61a7010VgnVCM100000ed730ad1RCRD&vmview=abst_detail_view&confID=47&abstractID=32158)
97. Fossa SD, Horwich A, Russell JM, Roberts JT, Cullen MH, Hodson NJ, Jones WG, Yosef H, Duchesne GM, Owen JR, Grosch EJ, Chetiyawardana AD, Reed NS, Widmer B, Stenning SP. Optimal planning target volume for stage I testicular seminoma: a Medical Research Council randomized trial. J Clin Oncol 1999;17(4):1146.  
<http://www.ncbi.nlm.nih.gov/pubmed/10561173>
98. Jones WG, Fossa SD, Mead GM, Roberts JT, Sokal M, Naylor S, Tenning SP. A randomized trial of two radiotherapy schedules in the adjuvant treatment of stage I seminoma (MRC TE 18). Eur J Cancer 2001;37(Suppl 6):S157, abstr 572.
99. Melchior D, Hammer P, Fimmers R, Schuller H, Albers P. Long term results and morbidity of paraaortic compared with paraaortic and iliac adjuvant radiation in clinical stage I seminoma. Anticancer Res 2001;21(4B):2989-93.  
<http://www.ncbi.nlm.nih.gov/pubmed/11712799>
100. Livsey JE, Taylor B, Mobarek N, Cooper RA, Carrington B, Logue PJ. Patterns of relapse following radiotherapy for stage I seminoma of the testis: implications for followup. Clin Oncol (R Coll Radiol) 2001;13(4):296-300.  
<http://www.ncbi.nlm.nih.gov/pubmed/11554630>
101. Van Leeuwen FE, Stiggelbout AM, van den Belt-Dusebout AW, Noyon R, Eliel MR, van Kerkhoff EH, Delemarre JF, Somers R. Second cancer risk following testicular cancer: a follow-up study of 1909 patients. Clin Oncol 1993;11(3):415-24.  
<http://www.ncbi.nlm.nih.gov/pubmed/8445415>
102. Travis LB, Curtis RE, Storm H, Hall P, Holowaty E, Van Leeuwen FE, Kohler BA, Pukkala E, Lynch CF, Andersson M, Bergfeldt K, Clarke EA, Wiklund T, Stoter G, Gospodarowicz M, Sturgeon J, Fraumeni JF Jr, Boice JD Jr. Risk of second malignant neoplasms among long-term survivors of testicular cancer. J Natl Cancer Inst 1997;89(19):1429-39.  
<http://www.ncbi.nlm.nih.gov/pubmed/9326912>
103. Horwich A, Bell J. Mortality and cancer incidence following treatment for seminoma of the testis. Radiother Oncol 1994;30(3):193-8.  
<http://www.ncbi.nlm.nih.gov/pubmed/8209001>
104. Bieri S, Rouzaud M, Miralbell R. Seminoma of the testis: is scrotal shielding necessary when radiotherapy is limited to the para-aortic nodes? Radiother Oncol 1999;50(3):349-53.  
<http://www.ncbi.nlm.nih.gov/pubmed/10392822>
105. Warszawski N, Schmucking M. Relapses in early-stage testicular seminoma: radiation therapy versus retroperitoneal lymphadenectomy. Scan J Urol Nephrol 1997;31(4):335-9.  
<http://www.ncbi.nlm.nih.gov/pubmed/9290165>
106. Heidenreich A, Albers P, Hartmann M, Kliesch S, Kohrmann KU, Krege S, Lossin P, Weissbach L; German Testicular Cancer Study Group. Complications of primary nerve sparing retroperitoneal lymph node dissection for clinical stage I nonseminomatous germ cell tumours of the testis: experience of the German Testicular Cancer Study Group. J Urol 2003;169(5):1710-4.  
<http://www.ncbi.nlm.nih.gov/pubmed/12686815>
107. Freedman LS, Parkinson MC, Jones WG, Oliver RT, Peckham MJ, Read G, Newlands ES, Williams CJ. Histopathology in the prediction of patients with stage I testicular teratoma treated by orchidectomy alone. Lancet 1987;2(8554):294-8.  
<http://www.ncbi.nlm.nih.gov/pubmed/2886764>
108. Read G, Stenning SP, Cullen MH, Parkinson MC, Horwich A, Kaye SB, Cook PA. Medical Research Council prospective study of surveillance for stage I testicular teratoma. J Clin Oncol 1992;10(11):1762-8.  
<http://www.ncbi.nlm.nih.gov/pubmed/1403057>
109. Colls BM, Harvey VJ, Skelton L, Frampton CM, Thompson PI, Bennett M, Perez DJ, Dady PJ, Forgeson GV, Kennedy IC. Late results of surveillance of clinical stage I nonseminoma germ cell testicular tumours: 17 years' experience in a national study in New Zealand. Br J Urol Int 1999;83(1):76-82.  
<http://www.ncbi.nlm.nih.gov/pubmed/10233456>

110. Oliver RT, Ong J, Shamash J, Ravi R, Nagund V, Harper P, Ostrowski MJ, Sizer B, Levay J, Robinson A, Neal DE, Williams M; Anglian Germ Cell Cancer Group. Long-term follow-up of Anglian Germ Cell Cancer Group surveillance versus patients with Stage 1 nonseminoma treated with adjuvant chemotherapy. *Urology* 2004;63(3):556-61.  
<http://www.ncbi.nlm.nih.gov/pubmed/15028457>
111. Klepp O, Olsson AM, Henrikson H, Aass N, Dahl O, Stenwig AE, Persson BE, Cavallin-Stahl E, Fossa SD, Wahlqvist L. Prognostic factors in clinical stage I nonseminomatous germ cell tumours of the testis: multivariate analysis of a prospective multicenter study. *J Clin Oncol* 1990;8(3):509-18.  
<http://www.ncbi.nlm.nih.gov/pubmed/1689773>
112. Kakiashvili D, Anson-Cartwright L, Sturgeon JF, Warde PR, Chung P, Moore M, Wang L, Azuero J, Jewett MA. Non risk-adapted surveillance management for clinical stage I nonseminomatous testis tumors. *J Urol* 2007;177:278 (abstr 835).
113. Cullen MH, Stenning SP, Parkinson MC, Fossa SD, Kaye SB, Horwich AH, Harland SJ, Williams MV, Jakes R. Short-course adjuvant chemotherapy in high-risk stage I nonseminomatous germ cell tumours of the testis: a Medical Research Council report. *J Clin Oncol* 1996;14(4):1106-13.  
<http://www.ncbi.nlm.nih.gov/pubmed/8648364>
114. Oliver RTD, Raja MA, Ong J, Gallagher CJ. Pilot study to evaluate impact of a policy of adjuvant chemotherapy for high risk stage I malignant teratoma on overall relapse rate of stage I cancer patients. *J Urol* 1992;148(5):1453-6.  
<http://www.ncbi.nlm.nih.gov/pubmed/1279211>
115. Studer UE, Fey MF, Calderoni A. Adjuvant chemotherapy after orchidectomy in high risk patients with clinical stage I nonseminomatous testicular cancer. *Eur Urol* 1993;23(4):444-9.  
<http://www.ncbi.nlm.nih.gov/pubmed/7687549>
116. Bohlen D, Borner M, Sonntag RW, Fey MF, Studer UE. Long-term results following adjuvant chemotherapy in patients with clinical stage I testicular nonseminomatous malignant germ cell tumours with high risk factors. *J Urol* 1999;161(4):1148-52.  
<http://www.ncbi.nlm.nih.gov/pubmed/10081858>
117. Pont J, Albrecht W, Postner G, Sellner F, Angel K, Holtl W. Adjuvant chemotherapy for high risk clinical stage I nonseminomatous testicular germ cell cancer: long-term results of a prospective trial. *J Clin Oncol* 1996;14(2):441-8.  
<http://www.ncbi.nlm.nih.gov/pubmed/8636755>
118. Chevreau C, Mazerolles C, Soulié M, Gaspard MH, Mourey L, Bujan L, Plante P, Rischmann P, Bachaud JM, Malavaud B. Long-term efficacy of two cycles of PEB regimen in high-risk stage I nonseminomatous testicular germ cell tumors with embryonal carcinoma and/or vascular invasion. *Eur Urol* 2004;46(2):209-14.  
<http://www.ncbi.nlm.nih.gov/pubmed/15245815>
119. Bohlen D, Burkhard FC, Mills R, Sonntag RW, Studer UE. Fertility and sexual function following orchidectomy and 2 cycles of chemotherapy for stage I high risk nonseminomatous germ cell cancer. *J Urol* 2001;165(2):441-4.  
<http://www.ncbi.nlm.nih.gov/pubmed/11176393>
120. Baniel J, Foster RS, Gonin R, Messemer JE, Donohue JP, Einhorn LH. Late relapse of testicular cancer. *J Clin Oncol* 1995;13(5):1170-6.  
<http://www.ncbi.nlm.nih.gov/pubmed/7537800>
121. Baniel J, Roth BJ, Foster RS, Donohue JP. Cost and risk benefit considerations in the management of clinical stage I nonseminomatous testicular tumours. *Ann Surg Oncol* 1996;3(1):86-93.  
<http://www.ncbi.nlm.nih.gov/pubmed/8770308>
122. Rustin GJ, Mead GM, Stenning SP, Vasey PA, Aass N, Huddart RA, Sokal MP, Joffe JK, Harland SJ, Kirk SJ; National Cancer Research Institute Testis Cancer Clinical Studies Group. Randomized trial of two or five computed tomography scans in the surveillance of patients with stage I nonseminomatous germ cell tumors of the testis: Medical Research Council Trial TE08, ISRCTN56475197-the National Cancer Research Institute Testis Cancer Clinical Studies Group. *J Clin Oncol* 2007;25(11):1310-5.  
<http://www.ncbi.nlm.nih.gov/pubmed/17416851>
123. Klepp O, Dahl O, Flodgren P, Stierner U, Olsson AM, Oldbring J, Nilsson S, Daehlin L, Tornblom M, Smaland R, Starkhammar H, Abramsson L, Wist E, Raabe N, Edekling T, Cavallin-Stahl E. Risk-adapted treatment of clinical stage 1 non-seminoma testis cancer. *Eur J Cancer* 1997;33(7):1038-44.  
<http://www.ncbi.nlm.nih.gov/pubmed/9376184>
124. Ondrus D, Matoska J, Belan V. Prognostic factors in clinical stage I nonseminomatous germ cell testicular tumours: rationale for different risk-adapted treatment. *Eur Urol* 1998;33(6):562-6.  
<http://www.ncbi.nlm.nih.gov/pubmed/9743698>

125. Maroto P, García del Muro X, Aparicio J, Paz-Ares L, Arranz JA, Guma J, Terrassa J, Barnadas J, Dorta J, Germà-Lluch JR. Multicentre risk-adapted management for stage I non-seminomatous germ cell tumours. *Ann Oncol* 2005;16(12):1915-20.  
<http://www.ncbi.nlm.nih.gov/pubmed/16126737>
126. Tandstad T, Dahl O, Cohn-Cedermark G, Cavallin-Ståhl E, Solberg A, Langberg C, Bremnes R, Lauerell A, Wijkström H, Klepp O: Risk-adapted treatment in clinical stage 1 (CS1), nonseminomatous germ cell testicular cancer (NSGCT), the SWENOTECA management program. *JCO* in press.
127. Spermon JR, Roeleveld TA, van der Poel HG, Hulsbergen-van de Kaa CA, Ten Bokkel-Huinink WW, van de Vijver M, Witjes JA, Horenblas S. Comparison of surveillance and retroperitoneal lymph node dissection in stage I nonseminomatous germ cell tumours. *Urology* 2002;59(6):923-9.  
<http://www.ncbi.nlm.nih.gov/pubmed/12031382>
128. Hendry WF, Norman A, Nicholls J, Dearnaley DP, Peckham MJ, Horwich A. Abdominal relapse in stage 1 nonseminomatous germ cell tumours of the testis managed by surveillance or with adjuvant chemotherapy. *BJU Int* 2000;86(1):89-93.  
<http://www.ncbi.nlm.nih.gov/pubmed/10886090>
129. Pizzocaro G, Salvioni R, Zanoni F. Unilateral lymphadenectomy in intraoperative stage I nonseminomatous testis cancer. *J Urol* 1985;134(3):485-9.  
<http://www.ncbi.nlm.nih.gov/pubmed/2993672>
130. Donohue JP, Thornhill JA, Foster RS, Rowland RG, Bihrl R. Retroperitoneal lymphadenectomy for clinical stage A testis cancer (1965-1989): modifications of technique and impact on ejaculation. *J Urol* 1993;149(2):237-43.  
<http://www.ncbi.nlm.nih.gov/pubmed/8381190>
131. Lashley DB, Lowe BA. A rational approach to managing stage I nonseminomatous germ cell cancer. *Urol Clin North Am* 1998;25(3):405-23.  
<http://www.ncbi.nlm.nih.gov/pubmed/9728211>
132. Foster RS, Roth BJ. Clinical stage I nonseminoma: surgery versus surveillance. *Semin Oncol* 1998;25(2):145-53.  
<http://www.ncbi.nlm.nih.gov/pubmed/9562447>
133. Kratzik C, Holtl W, Albrecht W et al. Risk adapted management for NSGCT stage I: long-term results of a multicenter study. *J Urol* 1996;155:547A.
134. Ondrus D, Goncalves F, Kausitz J, Mat'oska J, Belan V. The value of prognostic factors in the management of stage I nonseminomatous germ cell testicular tumours (NSGCTT). *Neoplasma* 1996;43(3):195-7.  
<http://www.ncbi.nlm.nih.gov/pubmed/8841507>
135. Donohue JP, Thornhill JA, Foster RS, Rowland RG, Bihrl R. Clinical stage B nonseminomatous germ cell testis cancer: the Indiana University experience using routine primary retroperitoneal lymph node dissection. *Eur J Cancer* 1995;31A(10):1599-604.  
<http://www.ncbi.nlm.nih.gov/pubmed/7488408>
136. Richie JP, Kantoff PW. Is adjuvant chemotherapy necessary for patients with stage 1B testicular cancer? *J Clin Oncol* 1991;9(8):1393-8.  
<http://www.ncbi.nlm.nih.gov/pubmed/2072143>
137. Pizzocaro G, Monfardini S. No adjuvant chemotherapy in selected patients with pathological stage II nonseminomatous germ cell tumours of the testis. *J Urol* 1984;131(4):677-80.  
<http://www.ncbi.nlm.nih.gov/pubmed/6200611>
138. Williams SD, Stablein DM, Einhorn LH, Muggia FM, Weiss RB, Donohue JP, Paulson DF, Brunner KW, Jacobs EM, Spaulding JT. Immediate adjuvant chemotherapy versus observation with treatment at relapse in pathological stage II testicular cancer. *N Engl J Med* 1987;317(23):1433-8.  
<http://www.ncbi.nlm.nih.gov/pubmed/2446132>
139. Bianci G, Beltrami P, Giusti G. Unilateral laparoscopic lymph node dissection for clinical stage I nonseminomatous germ cell testicular neoplasm. *Eur Urol* 1998;33(2):190-4.  
<http://www.ncbi.nlm.nih.gov/pubmed/9519363>
140. Rassweiler JJ, Frede T, Lenz E, Seemann O, Alken P. Long-term experience with laparoscopic retroperitoneal lymph node dissection in the management of low-stage testis cancer. *Eur Urol* 2000;37(3):251-60.  
<http://www.ncbi.nlm.nih.gov/pubmed/10720848>
141. Janetschek G, Hobisch A, Peschel R, Hittmair A, Bartsch G. Laparoscopic retroperitoneal lymph node dissection for clinical stage I non-seminomatous testicular carcinoma: long-term outcome. *J Urol* 2000;163(6):1793-6.  
<http://www.ncbi.nlm.nih.gov/pubmed/10799184>

142. LeBlanc E, Caty A, Dargent D, Querleu D, Mazeman E. Extraperitoneal laparoscopic para-aortic lymph node dissection for early stage nonseminomatous germ cell tumours of the testis with introduction of a nerve sparing technique: description and results. *J Urol* 2001;165(1):89-92.  
<http://www.ncbi.nlm.nih.gov/pubmed/11125371>
143. Albers P, Siener R, Krege S, Schmelz HU, Dieckmann KP, Heidenreich A, Kwasny P, Pechoel M, Lehmann J, Kliesch S, Köhrmann KU, Fimmers R, Weissbach L, Loy V, Wittekind C, Hartmann M; German Testicular Cancer Study Group. Randomized phase III trial comparing retroperitoneal lymph node dissection with one course of bleomycin and etoposide plus cisplatin chemotherapy in the adjuvant treatment of clinical stage I Nonseminomatous testicular germ cell tumors: AUO trial AH 01/94 by the German Testicular Cancer Study Group. *J Clin Oncol* 2008 Jun 20;26(18):2966-72.  
<http://www.ncbi.nlm.nih.gov/pubmed/18458040>
144. Pizzocaro G, Nicolai N, Salvioni R. Marker positive clinical stage I non seminomatous germ cell tumours (NSGCT) of the testis: which primary therapy? *J Urol* 1996;155(Suppl):328A.
145. Davis BE, Herr HW, Fair WR, Bosl GJ. The management of patients with nonseminomatous germ cell tumours of the testis with serologic disease only after orchidectomy. *J Urol* 1994;152(1):111-3.  
<http://www.ncbi.nlm.nih.gov/pubmed/7515445>
146. International Germ Cell Collaborative Group. International Germ Cell Consensus Classification: a prognostic factor-based staging system for metastatic germ cell cancers. *J Clin Oncol* 1997;15(2):594-603.  
<http://www.ncbi.nlm.nih.gov/pubmed/9053482>
147. Garcia-del-Muro X, Maroto P, Gumà J, Sastre J, López Brea M, Arranz JA, Lainez N, Soto de Prado D, Aparicio J, Piulats JM, Pérez X, Germá-Lluch JR. Chemotherapy as an alternative to radiotherapy in the treatment of stage IIA and IIB testicular seminoma: a Spanish Germ Cell Cancer Group Study. *J Clin Oncol* 2008 Nov 20;26(33):5416-21.  
<http://www.ncbi.nlm.nih.gov/pubmed/18936476>
148. Krege S, Boergermann C, Baschek R, Hinke A, Pottek T, Kliesch S, Dieckmann KP, Albers P, Knutzen B, Weinknecht S, Schmoll HJ, Beyer J, Ruebben H; German Testicular Cancer Study Group (GTCSG). Single agent carboplatin for CS IIA/B testicular seminoma. A phase II study of the German Testicular Cancer Study Group (GTCSG). *Ann Oncol* 2006;17(2):276-80.  
<http://www.ncbi.nlm.nih.gov/pubmed/16254023>
149. Frohlich MW, Small EJ. Stage II nonseminomatous testis cancer: the roles of primary and adjuvant chemotherapy. *Urol Clin North Am* 1998;25(3):451-9.  
<http://www.ncbi.nlm.nih.gov/pubmed/9728214>
150. Baniel J, Donohue JP. Cost and risk benefit considerations in low stage (I and II) nonseminomatous testicular tumours. *AUA Update Series* 1997;26:50-5.
151. Peckham MJ, Hendry WF. Clinical stage II non-seminatous germ cell testicular tumors. Results of management by primary chemotherapy. *Br J Urol* 1985;57(6):763-8.  
<http://www.ncbi.nlm.nih.gov/pubmed/2417652>
152. Logothetis CJ, Samuels ML, Selig DE, Johnson DE, Swanson DA, von Eschenbach AC. Primary chemotherapy followed by a selective retroperitoneal lymphadenectomy in the management of clinical stage II testicular carcinoma: a preliminary report. *J Urol* 1985;134(6):1127-30.  
<http://www.ncbi.nlm.nih.gov/pubmed/2414470>
153. Horwich A, Stenning S. Initial chemotherapy for stage II testicular nonseminoma. *World J Urol* 1994;12(3):148-50.  
<http://www.ncbi.nlm.nih.gov/pubmed/7951341>
154. Weissbach L, Bussar-Maatz R, Fletchner H, Pichlmeier U, Hartmann M, Keller L. RPLND or primary chemotherapy in clinical stage IIA/B nonseminomatous germ cell tumours. Results of a prospective multicenter trial including quality of life assessment. *Eur Urol* 2000;37(5):582-94.  
<http://www.ncbi.nlm.nih.gov/pubmed/10765098>
155. Sternberg CN. Role of primary chemotherapy in stage I and low-volume stage II nonseminomatous germ-cell testis tumours. *Urol Clin North Am* 1993;20(1):93-109.  
<http://www.ncbi.nlm.nih.gov/pubmed/8382000>
156. Horwich A, Norman A, Fisher C, Hendry WF, Nicholls J, Dearnaley DP. Primary chemotherapy for stage II nonseminomatous germ cell tumours of the testis. *J Urol* 1994;151(1):72-7.  
<http://www.ncbi.nlm.nih.gov/pubmed/8254836>
157. Donohue JP, Thornhill JA, Foster RS, Bihle R, Rowland RG, Einhorn LH. The role of retroperitoneal lymphadenectomy in clinical stage B testis cancer: the Indiana University Experience (1965 to 1989). *J Urol* 1995;153(1):85-9.  
<http://www.ncbi.nlm.nih.gov/pubmed/7966799>

158. Motzer RJ, Sheinfeld J, Mazumdar M, Bajorin DF, Bosl GJ, Herr H, Lyn P, Vlamis V. Etoposide and cisplatin adjuvant therapy for patients with pathological stage II germ cell tumours. *J Clin Oncol* 1995;13(11):2700-4.  
<http://www.ncbi.nlm.nih.gov/pubmed/7595727>
159. Hartlapp JH, Weissbach L, Bussar-Maatz R. Adjuvant chemotherapy in nonseminomatous testicular tumour stage II. *Int J Androl* 1987;10(1):277-84.  
<http://www.ncbi.nlm.nih.gov/pubmed/2438221>
160. Logothetis CJ, Swanson DA, Dexeus F, Chong C, Ogden S, Ayala AG, von Eschenbach AC, Johnson DE, Samuels ML. Primary chemotherapy for clinical stage II nonseminomatous germ cell tumours of the testis: a follow-up of 50 patients. *J Clin Oncol* 1987;5(6):906-11.  
<http://www.ncbi.nlm.nih.gov/pubmed/2438389>
161. Saxman S, Finch D, Gonin R, Einhorn LH. Long-term follow-up of a phase III study of three versus four cycles of bleomycin, etoposide and cisplatin in favorable-prognosis germ-cell tumours: the Indiana University Experience. *J Clin Oncol* 1998;16(2):702-6.  
<http://www.ncbi.nlm.nih.gov/pubmed/9469360>
162. de Wit R, Stoter G, Kaye SB, Sleijfer DT, Jones WG, ten Bokkel Huinink WW, Rea LA, Collette L, Sylvester R. Importance of bleomycin in combination chemotherapy for good-prognosis testicular nonseminoma: a randomized study of the European Organization for Research and Treatment of Cancer Genitourinary Tract Cancer Cooperative Group. *J Clin Oncol* 1997;15(5):1837-43.  
<http://www.ncbi.nlm.nih.gov/pubmed/9164193>
163. Horwich A, Sleijfer DT, Fossa SD, Kaye SB, Oliver RT, Cullen MH, Mead GM, de Wit R, de Mulder PH, Dearnaley DP, Cook PA, Sylvester RJ, Stenning SP. Randomized trial of bleomycin, etoposide and cisplatin compared with bleomycin, etoposide and carboplatin in good-prognosis metastatic nonseminomatous germ cell cancer: a multi-institutional Medical Research Council/European Organization for Research and Treatment of Cancer trial. *J Clin Oncol* 1997;15(5):1844-52.  
<http://www.ncbi.nlm.nih.gov/pubmed/9164194>
164. De Wit R, Roberts JT, Wilkinson PM, de Mulder PH, Mead GM, Fossa SD, Cook P, de Pryck L, Stenning S, Collette L. Equivalence of three or four cycles of bleomycin, etoposide, and cisplatin chemotherapy and of a 3- or 5- day schedule in good-prognosis germ cell cancer: a randomized study of the European Organization for Research and Treatment of Cancer Genitourinary Tract Cancer Cooperative Group and the Medical research Council. *J Clin Oncol* 2001;19(6):1629-40.  
<http://www.ncbi.nlm.nih.gov/pubmed/11250991>
165. Bokemeyer C, Kuczyk MA, Köhne H, Einsele H, Kynast B, Schmoll HJ. Hematopoietic growth factors and treatment of testicular cancer: biological interactions, routine use and dose intensive chemotherapy. *Ann Hematol* 1996;72(1):1-9.  
<http://www.ncbi.nlm.nih.gov/pubmed/8605273>
166. Xiao H, Mazumdar M, Bajorin DF, Sarosdy M, Vlamis V, Spicer J, Ferrara J, Bosl GJ, Motzer RJ. Long-term follow-up of patients with good-risk germ cell tumours treated with etoposide and cisplatin. *J Clin Oncol* 1997;15(7):2553-8.  
<http://www.ncbi.nlm.nih.gov/pubmed/9215824>
167. Culine S, Kerbrat P, Kramar A, Théodore C, Chevreau C, Geoffrois L, Bui NB, Pény J, Caty A, Delva R, Biron P, Fizazi K, Bouzy J, Droz JP; Genito-Urinary Group of the French Federation of Cancer Center (GETUG T93BP). Refining the optimal chemotherapy regimen for good-risk metastatic nonseminomatous germ-cell tumors: a randomized trial of the Genito-Urinary Group of the French Federation of Cancer Centers (GETUG T93BP). *Ann Oncol*. 2007;18(5):917-24.  
<http://www.ncbi.nlm.nih.gov/pubmed/17351252>
168. Fossa SD, Kaye SB, Mead GM, Cullen M, de Wit R, Bodrogi I, van Groeningen CJ, de Mulder PH, Stenning S, Lallemand E, de Pryck L, Collette L. Filgastrim during combination chemotherapy of patients with poor prognosis metastatic germ cell malignancy. European Organization for Research and Treatment of Cancer, Genito-Urinary Group, and the Medical Research Council Testicular Cancer Working Party. *J Clin Oncol* 1998;16(2):716-24.  
<http://www.ncbi.nlm.nih.gov/pubmed/9469362>
169. De Wit R, Stoter G, Sleijfer DT, Neijt JP, ten Bokkel Huinink WW, de Pryck L, Collette L, Sylvester R. Four cycles of PEB vs four cycles of VIP in patients with intermediate-prognosis metastatic testicular non-seminoma: a randomized study of the EORTC Genitourinary Tract Cancer Cooperative Group. European Organization for Research and Treatment of Cancer. *Br J Cancer* 1998;78(6):828-32.  
<http://www.ncbi.nlm.nih.gov/pubmed/9743309>

170. De Witt R, Louwerens M, de Mulder PH, Verweij J, Rodenhuis S, Schornagel J. Management of intermediate-prognosis germ-cell cancer: results of a phase I/II study of Taxol-PEB. *Int J Cancer* 1999;83(6):831-3.  
<http://www.ncbi.nlm.nih.gov/pubmed/10597204>
171. Nichols CR, Catalano PJ, Crawford ED, Vogelzang NJ, Einhorn LH, Loehrer PJ. Randomized comparison of cisplatin and etoposide and either bleomycin or ifosfamide in treatment of advanced disseminated germ cell tumours: and Eastern Cooperative Oncology Group, Southwest Oncology Group, and Cancer and Leukaemia Group B Study. *J Clin Oncol* 1998;16(9):1287-93.  
<http://www.ncbi.nlm.nih.gov/pubmed/10597204>
172. Motzer RJ, Nichols CJ, Margolin KA, Bacik J, Richardson PG, Vogelzang NJ, Bajorin DF, Lara PN Jr, Einhorn L, Mazumdar M, Bosl GJ. Phase III randomized trial of conventional-dose chemotherapy with or without high-dose chemotherapy and autologous hematopoietic stem-cell rescue as first-line treatment for patients with poor-prognosis metastatic germ cell tumors. *J Clin Oncol* 2007;25(3):247-56.  
<http://www.ncbi.nlm.nih.gov/pubmed/17235042>
173. Motzer RJ, Mazumdar M, Bajorin DF, Bosl GJ, Lyn P, Vlamis V. High-dose carboplatin, etoposide, and cyclophosphamide with autologous bone marrow transplantation in first-line therapy for patients with poor-risk germ cell tumours. *J Clin Oncol* 1997;15(7):2546-52.  
<http://www.ncbi.nlm.nih.gov/pubmed/9215823>
174. Bokemeyer C, Kollmannsberger C, Meisner C, Harstrick A, Beyer J, Metzner B, Hartmann JT, Schmoll HJ, Einhorn L, Kanz L, Nichols C. First-line high-dose chemotherapy compared with standard-dose PEB/VIP chemotherapy in patients with advanced germ cell tumours: a multivariate and matched-pair analysis. *J Clin Oncol* 1999;17(11):3450-6.  
<http://www.ncbi.nlm.nih.gov/pubmed/10550141>
175. Fizazi K, Culine S, Kramar A, Amato RJ, Bouzy J, Chen I, Droz JP, Logothetis CJ. Early predicted time to normalization of tumor markers predicts outcome in poor-prognosis nonseminomatous germ cell tumors. *J Clin Oncol* 2004;22(19):3868-76.  
<http://www.ncbi.nlm.nih.gov/pubmed/15302906>
176. Gerl A, Clemm C, Lamerz R, Mann K, Wilmanns W. Prognostic implications of tumour marker analysis in non-seminomatous germ cell tumours with poor prognosis metastatic disease. *Eur J Cancer* 1993;29A(7):961-5.  
<http://www.ncbi.nlm.nih.gov/pubmed/7684597>
177. Murphy BA, Motzer RJ, Mazumdar M, Vlamis V, Nisselbaum J, Bajorin D, Bosl GJ. Serum tumour markers decline is an early predictor of treatment outcome in germ cell tumour patients treated with cisplatin and ifosfamide salvage chemotherapy. *Cancer* 1994;73(10):2520-6.  
<http://www.ncbi.nlm.nih.gov/pubmed/7513603>
178. Andre F, Fizazi K, Culine S, Droz J, Taupin P, Lhomme C, Terrier-Lacombe M, Theodore C. The growing teratoma syndrome: results of therapy and long-term follow-up of 33 patients. *Eur J Cancer* 2000;36(11):1389-94.  
<http://www.ncbi.nlm.nih.gov/pubmed/10899652>
179. De Wit R, Collette L, Sylvester R, de Mulder PH, Sleyfer DT, ten Bokkel Huinink WW, Kaye SB, van Oosterom AT, Boven E, Stoter G. Serum alpha-fetoprotein surge after the initiation of chemotherapy for non-seminomatous testicular cancer has an adverse prognostic significance. *Br J Cancer* 1998;78(10):1350-5.  
<http://www.ncbi.nlm.nih.gov/pubmed/9823978>
180. Zon RT, Nichols C, Einhorn LH. Management strategies and outcomes of germ cell tumour patients with very high human chorionic gonadotropin levels. *J Clin Oncol* 1998;16(4):1294-7.  
<http://www.ncbi.nlm.nih.gov/pubmed/9552028>
181. Fossa AD, Stenning SP, Gerl A, Horwich A, Clark PI, Wilkinson PM, Jones WG, Williams MV, Oliver RT, Newlands ES, Mead GM, Cullen MH, Kaye SB, Rustin GJ, Cook PA. Prognostic factors in patients progressing after cisplatin-based chemotherapy for malignant non-seminomatous germ cell tumours. *Br J Cancer* 1999;80(9):1392-9.  
<http://www.ncbi.nlm.nih.gov/pubmed/10424741>
182. Fossa SD, Borge L, Aass N, Johannessen NB, Stenwig AE, Kaalhus O. The treatment of advanced metastatic seminoma: experience in 55 cases. *J Clin Oncol* 1987;5(7):1071-7.  
<http://www.ncbi.nlm.nih.gov/pubmed/2439660>
183. Herr HW, Bosl G. Residual mass after chemotherapy for seminoma: changing concepts of management. *J Urol* 1987;137(6):1234-5.  
<http://www.ncbi.nlm.nih.gov/pubmed/2438431>

184. Hofmockel G, Gruss A, Theiss M. Chemotherapy in advanced seminoma and the role of postcystostatic retroperitoneal lymph node dissection. *Urol Int* 1996;57(1):38-42.  
<http://www.ncbi.nlm.nih.gov/pubmed/8840489>
185. Kamat MR, Kulkarni JN, Tongoankar HB, Ravi R. Value of retroperitoneal lymph node dissection in advanced testicular seminoma. *J Surg Oncol* 1992;51(1):65-7.  
<http://www.ncbi.nlm.nih.gov/pubmed/1381455>
186. Loehrer PJ Sr, Birch R, Williams SD, Greco FA, Einhorn LH. Chemotherapy of metastatic seminoma: the SouthEastern Cancer Study Group Experience. *J Clin Oncol* 1987;5(8):1212-20.  
<http://www.ncbi.nlm.nih.gov/pubmed/2442317>
187. Motzer R, Bosl G, Heelan R, Fair W, Whitmore W, Sogani P, Herr H, Morse M. Residual mass: an indication for further therapy in patients with advanced seminoma following systemic chemotherapy. *J Clin Oncol* 1987;5(7):1064-70.  
<http://www.ncbi.nlm.nih.gov/pubmed/3598610>
188. Peckham MJ, Horwich A, Hendry WF. Advanced seminoma treatment with cisplatin based combination chemotherapy or carboplatin (JM8). *Br J Cancer* 1985;52(1):7-13.  
<http://www.ncbi.nlm.nih.gov/pubmed/3893507>
189. De Santis M, Becherer A, Bokemeyer C, Stoiber F, Oechsle K, Sellner F, Lang A, Kletter K, Dohmen BM, Dittrich C, Pont J. 2-18fluoro-deoxy-D-glucose positron emission tomography is a reliable predictor for viable tumor in postchemotherapy seminoma: an update of the prospective multicentric SEMPET trial. *J Clin Oncol* 2004;22(6):1034-9.  
<http://www.ncbi.nlm.nih.gov/pubmed/15020605>
190. Duchesne GM, Stenning SP, Aass N, Mead GM, Fossa SD, Oliver RT, Horwich A, Read G, Roberts IT, Rustin G, Cullen MH, Kaye SB, Harland SJ, Cook PA. Radiotherapy after chemotherapy for metastatic seminoma – a diminishing role. *Eur J Cancer* 1997;33(6):829-35.  
<http://www.ncbi.nlm.nih.gov/pubmed/9291801>
191. Bamberg M, Classen J. Stellenwert der Strahlentherapie von Residualtumouren nach Chemotherapie metastasierter Seminome. *Strahlenther Onkol* 1998;174(8):442-443. [Significance of radiotherapy for residual tumours following chemotherapy for metastatic seminoma] [article in German]  
<http://www.ncbi.nlm.nih.gov/pubmed/9739390>
192. Puc H, Heelan R, Mazumdar M, Herr H, Scheinfeld J, Vlamis V, Bajorin DF, Bosl GJ, Mancel P, Motzer RJ. Management of residual mass in advanced seminoma: results and recommendations from Memorial Sloan Kettering Cancer Center. *J Clin Oncol* 1996;14(2):454-60.  
<http://www.ncbi.nlm.nih.gov/pubmed/8636757>
193. Herr HW, Scheinfeld J, Puc HS, Heelan R, Bajorin DF, Mancel P, Bosl GJ, Motzer RJ. Surgery for a postchemotherapy residual mass in seminoma. *J Urol* 1997;157(3):860-2.  
<http://www.ncbi.nlm.nih.gov/pubmed/9072586>
194. Mosharafa AA, Foster RS, Leibovich BC, Bihrlie R, Donahue JP. Is the post-chemotherapy resection of seminomatous elements associated with higher acute morbidity? *J Urol* 2002;167:172, abstract 692.
195. Kuczyk M, Machtens S, Stief C, Jonas U. Management of the post-chemotherapy residual mass in patients with advanced stage non-seminomatous germ cell tumours (GCT). *Int J Cancer* 1999;83(6):852-5.  
<http://www.ncbi.nlm.nih.gov/pubmed/10597210>
196. Fossa SD, Ous S, Lien HH, Stenwig AE. Post-chemotherapy lymph node histology in radiologically normal patients with metastatic nonseminomatous testicular cancer. *J Urol* 1989;141(3):557-9.  
<http://www.ncbi.nlm.nih.gov/pubmed/2918591>
197. Toner GC, Panicek DM, Heelan RT, Geller NL, Lin SY, Bajorin D, Motzer RJ, Scher HI, Herr HW, Morse MJ et al. Adjunctive surgery after chemotherapy for nonseminomatous germ cell tumours: recommendations for patient selection. *J Clin Oncol* 1990;8(10):1683-94.  
<http://www.ncbi.nlm.nih.gov/pubmed/2170590>
198. Donohue JP, Rowland RG, Kopecky K, Steidle CP, Geier G, Ney KG, Einhorn L, Williams S, Loehrer P. Correlation of computerized tomographic changes and histological findings in 80 patients having radical retroperitoneal lymph node dissection after chemotherapy for testis cancer. *J Urol* 1987;137(6):1176-9.  
<http://www.ncbi.nlm.nih.gov/pubmed/3035236>
199. Richie JP. The surgical management of advanced abdominal disease. *Semin Urol* 1984;2(4):238-43.  
<http://www.ncbi.nlm.nih.gov/pubmed/6505446>
200. Stomper PC, Fung CY, Socinski MA, Jochelson MS, Garnick MB, Richie JP. Detection of retroperitoneal metastases in early-stage nonseminomatous testicular cancer: analysis of different CT criteria. *Am J Roentgenol* 1987;149(6):1187-90.  
<http://www.ncbi.nlm.nih.gov/pubmed/2825494>

201. Carver BS, Shayegan B, Serio A, Motzer RJ, Bosl GJ, Sheinfeld J. Long-term clinical outcome after postchemotherapy retroperitoneal lymph node dissection in men with residual teratoma. *J Clin Oncol* 2007;25(9):1033-7.  
<http://www.ncbi.nlm.nih.gov/pubmed/17261854>
202. Aprikian AG, Herr HW, Bajorin DF, Bosl GJ. Resection of post-chemotherapy residual masses and limited retroperitoneal lymphadenectomy in patients with metastatic testicular nonseminomatous germ cell tumours. *Cancer* 1994;74(4):1329-34.  
<http://www.ncbi.nlm.nih.gov/pubmed/8055456>
203. Herr HW. Does necrosis on frozen-section analysis of a mass after chemotherapy justify a limited retroperitoneal resection in patients with advanced testis cancer? *Br J Urol* 1997;80(4):653-7.  
<http://www.ncbi.nlm.nih.gov/pubmed/9352708>
204. Hendry WF, A'Hern RP, Hetherington JW, Peckham MJ, Dearnaley DP, Horwich A. Para-aortic lymphadenectomy after chemotherapy for metastatic non-seminomatous germ cell tumours: prognostic value and therapeutic benefit. *Br J Urol* 1993;71(2):208-13.  
<http://www.ncbi.nlm.nih.gov/pubmed/8384914>
205. Wood DP, Herr HW, Heller G, Vlamis V, Sogani PC, Motzer RJ, Fair WR, Bosl GJ. Distribution of retroperitoneal metastases after chemotherapy in patients with nonseminomatous germ cell tumours. *J Urol* 1992;148(6):1812-5.  
<http://www.ncbi.nlm.nih.gov/pubmed/1331547>
206. Baniel J, Foster RS, Rowland RG, Bihrl R, Donohue JP. Complications of post-chemotherapy retroperitoneal lymph node dissection. *J Urol* 1995;153(3 Pt 2):976-80.  
<http://www.ncbi.nlm.nih.gov/pubmed/7853586>
207. Hartmann JT, Schmoll HJ, Kuczyk MA, Candelaria M, Bokemeyer C. Post-chemotherapy resection of residual masses from metastatic non-seminomatous germ cell tumours. *Ann Oncol* 1997;8(6):531-8.  
<http://www.ncbi.nlm.nih.gov/pubmed/9261521>
208. Rabbani F, Goldenberg SL, Gleave ME, Paterson RF, Murray N, Sullivan LD. Retroperitoneal lymphadenectomy for post-chemotherapy residual masses: is a modified dissection and resection of the residual mass sufficient? *Br J Urol* 1998;81(2):295-300.  
<http://www.ncbi.nlm.nih.gov/pubmed/9488075>
209. Tekgul S, Özen HA, Celebi I, Ozgu I, Ergen A, Demircin M, Remzi D. Postchemotherapeutic surgery for metastatic testicular germ cell tumours: results of extended primary chemotherapy and limited surgery. *Urology* 1994;43(3):349-54.  
<http://www.ncbi.nlm.nih.gov/pubmed/8134989>
210. Steyerberg EW, Keizer HJ, Fossa SD, Sleijfer DT, Toner GC, Schraffordt Koops H, Mulders PF, Messemer JE, Ney K, Donohue JP et al. Prediction of residual retroperitoneal mass histology after chemotherapy for metastatic nonseminomatous germ cell tumour: multivariate analysis of individual patient data from six study groups. *J Clin Oncol* 1995;13(5):1177-87.  
<http://www.ncbi.nlm.nih.gov/pubmed/7537801>
211. Hartmann JT, Candelaria M, Kuczyk MA, Schmoll HJ, Bokemeyer C. Comparison of histological results from the resection of residual masses at different sites after chemotherapy for metastatic nonseminomatous germ cell tumours. *Eur J Cancer* 1997;33(6):843-7.  
<http://www.ncbi.nlm.nih.gov/pubmed/9291803>
212. Stenning SP, Parkinson MC, Fisher C, Mead GN, Cook PA, Fossa SD, Horwich A, Jones WG, Newlands ES, Oliver RT, Stenwig AE, Wilkinson PM. Post-chemotherapy residual masses in germ cell tumour patients: content, clinical features and prognosis. Medical Research Council Testicular Tumour Working Party. *Cancer* 1998;83(7):1409-19.  
<http://www.ncbi.nlm.nih.gov/pubmed/9762943>
213. Weinknecht S, Hartmann M, Weissbach L. [In which marker positive germ-cell tumour patients is residual tumour resection useful?] *Urologe A* 1998;37(6):621-4. [article in German]  
<http://www.ncbi.nlm.nih.gov/pubmed/9887490>
214. Hendry WF, Norman AR, Dearnaley DP, Fisher C, Nicholls J, Huddart RA, Horwich A. Metastatic nonseminomatous germ cell tumours of the testis: results of elective and salvage surgery for patients with residual retroperitoneal masses. *Cancer* 2002;94(6):1668-76.  
<http://www.ncbi.nlm.nih.gov/pubmed/11920527>
215. Sheinfeld J. The role of adjunctive post-chemotherapy surgery for nonseminomatous germ-cell tumours: current concepts and controversies. *Sem Urol Oncol* 2002;20(4):262-71.  
<http://www.ncbi.nlm.nih.gov/pubmed/12489059>
216. Foster RS, Donohue JP. Can retroperitoneal lymphadenectomy be omitted in some patients after chemotherapy? *Urol Clin North Am* 1998;25(3):479-84.  
<http://www.ncbi.nlm.nih.gov/pubmed/9728217>

217. Steyerberg EW, Kaiser HJ, Habbema JD. Prediction models of the histology of residual masses after chemotherapy for metastatic testicular cancer. ReHIT Study Group. *Int J Cancer* 1999;83(6):856-9.  
<http://www.ncbi.nlm.nih.gov/pubmed/10597211>
218. Vergouwe Y, Steyerberg EW, De Wit R, Roberts JT, Keizer HJ, Collette L, Stenning SP, Habbema JD. External validity of a prediction rule for residual mass histology in testicular cancer: an evaluation for good prognosis patients. *Br J Cancer* 2003;88(6):843-7.  
<http://www.ncbi.nlm.nih.gov/pubmed/12644820>
219. Fizazi K, Tjulandin S, Salvioni R, Germa-Lluch JR, Bouzy J, Ragan D, Bokemeyer C, Gerl A, Flechon A, de Bono JS, Stenning S, Horwich A, Pont J, Albers P, De Giorgi U, Bower M, Bulanov A, Pizzocaro G, Aparicio J, Nichols CR, Theodore C, Hartmann JT, Schmoll HJ, Kaye SB, Culine S, Droz JP, Mahe C. Viable malignant cells after primary chemotherapy for disseminated nonseminomatous germ cell tumours: prognostic factors and role of postsurgery chemotherapy-results from an international study group. *J Clin Oncol* 2001;19(10):2647-57.  
<http://www.ncbi.nlm.nih.gov/pubmed/11352956>
220. Besse B, Grunenwald D, Fléchon A, Caty A, Chevreau C, Culine S, Théodore C, Fizazi K. Nonseminomatous germ cell tumors: assessing the need for postchemotherapy contralateral pulmonary resection in patients with ipsilateral complete necrosis. *J Thorac Cardiovasc Surg* 2009;137(2):448-52).  
<http://www.ncbi.nlm.nih.gov/pubmed/19185168>
221. Fizazi K, Oldenburg J, Dunant A, Chen I, Salvioni R, Hartmann JT, De Santis M, Daugaard G, Flechon A, de Giorgi U, Tjulandin S, Schmoll HJ, Bouzy J, Fossa SD, Fromont G. Assessing prognosis and optimizing treatment in patients with postchemotherapy viable nonseminomatous germ-cell tumors (NSGCT): results of the sCR2 international study. *Ann Oncol* 2008;19(2):259-64.  
<http://www.ncbi.nlm.nih.gov/pubmed/18042838>
222. Miller KD, Loehrer PJ, Gonin R, Einhorn LH. Salvage chemotherapy with vinblastine, ifosfamide and cisplatin in recurrent seminoma. *J Clin Oncol* 1997;15(4):1427-31.  
<http://www.ncbi.nlm.nih.gov/pubmed/9193335>
223. Beyer J, Bokemeyer C, Schmoll HJ. [Salvagechemotherapie rezidivierender und refraktärer Hodentumoren] *Onkologie* 1998;4:541-546. [Salvage chemotherapy for relapsed and refractory germ cell tumours] [article in German]
224. Loehrer PJ, Gonin R, Nichols CR, Weathers T, Einhorn LH. Vinblastine plus ifosfamide plus cisplatin as initial salvage therapy in recurrent germ cell tumour. *J Clin Oncol* 1998;16(7):2500-4.  
<http://www.ncbi.nlm.nih.gov/pubmed/9667270>
225. Beyer J, Rick O, Siegert W, Bokemeyer C. Salvage chemotherapy in relapsed germ cell tumours. *World J Urol* 2001;19(2):90-3.  
<http://www.ncbi.nlm.nih.gov/pubmed/11374323>
226. Schmoll HJ, Beyer J. Prognostic factors in metastatic germ cell tumours. *Semin Oncol* 1998;25(2):174-85.  
<http://www.ncbi.nlm.nih.gov/pubmed/9562450>
227. Kaye SB, Mead GM, Fossa SD, Cullen M, de Wit R, Bodrogi I, van Groeningen C, Sylvester R, Collette L, Stenning S, de Pryck L, Lallemand E, de Mulder P. Intensive induction-sequential chemotherapy with BOP/VIP-B compared with treatment with PEB/EP for poor prognosis metastatic germ cell tumour: a randomized Medical Research Council/European Organization for Research and Treatment of Cancer study. *J Clin Oncol* 1998;16(2):692-701.  
<http://www.ncbi.nlm.nih.gov/pubmed/9469359>
228. Beyer J, Schmoll HJ. [Prognosefaktoren bei metastasierten seminomatösen und nichtseminomatösen Hodentumoren.] *Onkologie* 1998;4:518-523. [Prognostic factors in metastatic seminoma and non-seminoma germ-cell tumours] [article in German]
229. Beyer J, Stenning S, Gerl A, Fossa S, Siegert W. High-dose versus conventional-dose chemotherapy as a first-salvage treatment in patients with non-seminomatous germ-cell tumours: a matched pair analysis. *Ann Oncol* 2002;13(4):599-605.  
<http://www.ncbi.nlm.nih.gov/pubmed/12056711>
230. Bhatia S, Abonour R, Porcu P, Seshadri R, Nichols CR, Cornetta K, Einhorn LH. High-dose chemotherapy as initial salvage chemotherapy in patients with relapsed testicular cancer. *J Clin Oncol* 2000;18(19):3346-51.  
<http://www.ncbi.nlm.nih.gov/pubmed/11013274>

231. Rosti G, Pico JL, Wandt H et al. High-dose chemotherapy (HDC) in the salvage treatment of patients failing first-line platinum chemotherapy for advanced germ cell tumours (GCT): first results of a prospective randomised trial of the European Group for Blood and Marrow Transplantation (EBMT): IT- 94 study. *Proc Ann Soc Clin Oncol* 2002;21:180a, abstr 716.
232. Kondagunta GV, Bacik J, Donadio A, Bajorin D, Marion S, Sheinfeld J, Bosl GJ, Motzer RJ. Combination of paclitaxel, ifosfamide, and cisplatin is an effective second-line therapy for patients with relapsed testicular germ cell tumors. *J Clin Oncol* 2005;23(27):6549-55.  
<http://www.ncbi.nlm.nih.gov/pubmed/16170162>
233. Mead GM, Cullen MH, Huddart R, Harper P, Rustin GJ, Cook PA, Stenning SP, Mason M; MRC Testicular Tumour Working Party. A phase II trial of TIP (paclitaxel, ifosfamide and cisplatin) given as second-line (post-PEB) salvage chemotherapy for patients with metastatic germ cell cancer: a medical research council trial. *Br J Cancer* 2005;93(2):178-84.  
<http://www.ncbi.nlm.nih.gov/pubmed/15999102>
234. Pico JL, Rosti G, Kramar A, Wandt H, Koza V, Salvioni R, Theodore C, Lelli G, Siegert W, Horwich A, Marangolo M, Linkesch W, Pizzocaro G, Schmoll HJ, Bouzy J, Droz JP, Biron P; Genito-Urinary Group of the French Federation of Cancer Centers (GETUG-FNCLCC), France; European Group for Blood and Marrow Transplantation (EBMT). A randomised trial of high-dose chemotherapy in the salvage treatment of patients failing first-line platinum chemotherapy for advanced germ cell tumours. *Ann Oncol* 2005;16(7):1152-9.  
<http://www.ncbi.nlm.nih.gov/pubmed/15928070>
235. Lorch A, Kollmannsberger C, Hartmann JT, Metzner B, Schmidt-Wolf IG, Berdel WE, Weissinger F, Schleicher J, Egerer G, Haas A, Schirren R, Beyer J, Bokemeyer C, Rick O; German Testicular Cancer Study Group. Single versus sequential high-dose chemotherapy in patients with relapsed or refractory germ cell tumors: a prospective randomized multicenter trial of the German Testicular Cancer Study Group. *J Clin Oncol* 2007;25(19):2778-84.  
<http://www.ncbi.nlm.nih.gov/pubmed/17602082>
236. Motzer RJ, Mazumdar M, Sheinfeld J, Bajorin DF, Macapinlac HA, Bains M, Reich L, Flombaum C, Mariani T, Tong WP, Bosl GJ. Sequential dose-intensive paclitaxel, ifosfamide, carboplatin, and etoposide salvage therapy for germ cell tumor patients. *J Clin Oncol* 2000;18(6):1173-80.  
<http://www.ncbi.nlm.nih.gov/pubmed/10715285>
237. Vaena DA, Abonour R, Einhorn LH. Long-term survival after high-dose salvage chemotherapy for germ cell malignancies with adverse prognostic variables. *J Clin Oncol* 2003;21(22):4100-4.  
<http://www.ncbi.nlm.nih.gov/pubmed/14615439>
238. Reinhorn LH, Rajhavan D, Kindlen H. A phase I trial of gemcitabine plus paclitaxel combination therapy in patients with refractory advanced germ cell tumours. *Proc ASCO* 1999;18:207A (abstr 796).
239. Motzer JR, Sheinfeld J, Mazumdar M, Bains M, Mariani T, Bacik J, Bajorin D, Bosl GJ. Paclitaxel, ifosfamide, and cisplatin second-line therapy for patients with relapsed testicular germ cell cancer. *J Clin Oncol* 2000;18(12):2413-8.  
<http://www.ncbi.nlm.nih.gov/pubmed/10856101>
240. Bokemeyer C, Gerl A, Schoffski P, Harstrick A, Niederle N, Beyer J, Casper J, Schmoll HJ, Kanz L. Gemcitabine in patients with relapse or cisplatin refractory testicular cancer. *J Clin Oncol* 1999;17(2):512-6.  
<http://www.ncbi.nlm.nih.gov/pubmed/10080593>
241. George DW, Foster RS, Hromas RA, Robertson KA, Vance GH, Ulbright TM, Gobbett TA, Heiber DJ, Heerema NA, Ramsey HC, Thurston VC, Jung SH, Shen J, Finch DE, Kelley MR, Einhorn LH. Update on late relapse of germ cell tumor: a clinical and molecular analysis. *J Clin Oncol* 2003;21(1):113-22.  
<http://www.ncbi.nlm.nih.gov/pubmed/12506179>
242. Lipphardt ME, Albers P. Late relapse of testicular cancer. *World J Urol* 2004;22(1):47-54.  
<http://www.ncbi.nlm.nih.gov/pubmed/15064970>
243. Tiffany P, Morse MJ, Bosl G, Vaughan ED Jr, Sogani PC, Herr HW, Whitmore WF Jr. Sequential excision of residual thoracic and retroperitoneal masses after chemotherapy for stage III germ cell tumours. *Cancer* 1986;57(5):978-83.  
<http://www.ncbi.nlm.nih.gov/pubmed/3002596>
244. Cassidy J, Lewis CR, Kaye SB, Kirk D. The changing role of surgery in metastatic non-seminomatous germcell tumour. *Br J Cancer* 1992;65(1):127-9.  
<http://www.ncbi.nlm.nih.gov/pubmed/1370759>
245. Coogan CL, Foster RS, Rowland RG, Bihle R, Smith ER Jr, Einhorn LH, Roth BJ, Donohue JP. Postchemotherapy retroperitoneal lymph node dissection is effective therapy in selected patients with elevated tumour markers after primary chemotherapy alone. *Urology* 1997;50(6):957-62.  
<http://www.ncbi.nlm.nih.gov/pubmed/9426730>

246. Eastham JA, Wilson TG, Russell C, Ahlering TE, Skinner DG. Surgical resection in patients with nonseminomatous germ cell tumour who fail to normalize serum tumour markers after chemotherapy. *Urology* 1994;43(1):74-80.  
<http://www.ncbi.nlm.nih.gov/pubmed/7506856>
247. Gerl A, Clemm C, Schmeller N, Hentrich M, Lamerz R, Wilmanns W. Late relapse of germ cell tumours after cisplatin-based chemotherapy. *Ann Oncol* 1997;8(1):41-7.  
<http://www.ncbi.nlm.nih.gov/pubmed/9093706>
248. Kisbenedek L, Bodrogi I, Szeldeli P, Baki M, Tenke P, Horti J. Results of salvage retroperitoneal lymphadenectomy (RLA) in the treatment of patients with nonseminomatous germ cell tumours remaining marker positive after inductive chemotherapy. *Int Urol Nephrol* 1995;27(3):325-9.  
<http://www.ncbi.nlm.nih.gov/pubmed/7591598>
249. Murphy BR, Breeden ES, Donohue JP, Messemer J, Walsh W, Roth BJ, Einhorn LH. Surgical salvage of chemorefractory germ cell tumours. *J Clin Oncol* 1993;11(2):324-9.  
<http://www.ncbi.nlm.nih.gov/pubmed/8381163>
250. Nichols C. Treatment of recurrent germ cell tumours. *Semin Surg Oncol* 1999;17(4):268-74.  
<http://www.ncbi.nlm.nih.gov/pubmed/10588856>
251. Ravi R, Ong J, Oliver RT, Badenoch DF, Fowler CG, Hendry WF. Surgery as salvage therapy in chemotherapy-resistant nonseminomatous germ cell tumours. *Br J Urol* 1998;81(6):884-8.  
<http://www.ncbi.nlm.nih.gov/pubmed/9666776>
252. Albers P, Ganz A, Hanning E, Miersch WD, Muller SC. Salvage surgery of chemorefractory germ cell tumours with elevated tumour markers. *J Urol*, 2000;164(2):381-4.  
<http://www.ncbi.nlm.nih.gov/pubmed/10893590>
253. Fossa SD, Bokemeyer C, Gerl A, Culine S, Jones WG, Mead GM, Germa-Luch JR, Pont J, Schmoll HJ, Tjulandin S. Treatment outcome of patients with brain metastases from malignant germ cell tumours. *Cancer* 1999;85(4):988-97.  
<http://www.ncbi.nlm.nih.gov/pubmed/10091779>
254. Bokemeyer C, Nowak P, Haupt A, Metzner B, Köhne H, Hartmann JT, Kanz L, Schmoll HJ. Treatment of brain metastases in patients with testicular cancer. *J Clin Oncol* 1997;15(4):1449-54.  
<http://www.ncbi.nlm.nih.gov/pubmed/9193339>
255. Hartmann JT, Bamberg M, Albers P et al. Multidisciplinary treatment and prognosis of patients with central nervous metastases (CNS) from testicular germ cell tumour (GCT) origin. *Proc Ann Soc Clin Oncol* 2003;22:400, abstr 1607.
256. Edelman MJ, Meyers FJ, Siegel D. The utility of follow-up testing after curative cancer therapy. *J Gen Intern Med* 1997;12(5):318-31.  
<http://www.ncbi.nlm.nih.gov/pubmed/9159703>
257. Rathmell AJ, Brand IR, Carey BM, Jones WG. Early detection of relapse after treatment for metastatic germ cell tumour of the testis: an exercise in medical audit. *Clin Oncol (R Coll Radiol)* 1993;5(1):34-8.  
<http://www.ncbi.nlm.nih.gov/pubmed/7678749>
258. Gietema JA, Meinardi MT, Sleifer DT, Hoekstra HJ, van der Graaf WT. Routine chest X-rays have no additional value in the detection of relapse during routine follow-up of patients treated with chemotherapy for disseminated non-seminomatous testicular cancer. *Ann Oncol* 2002;13(10):1616-20.  
<http://www.ncbi.nlm.nih.gov/pubmed/12377651>
259. Pont J, Albrecht W, Postner G, Sellner F, Angel K, Holtl W. Adjuvant chemotherapy for high risk clinical stage I nonseminomatous testicular germ cell cancer: long-term results of a prospective trial. *J Clin Oncol* 1996;14(2):441-8.  
<http://www.ncbi.nlm.nih.gov/pubmed/8636755>
260. Bohlen D, Borner M, Sonntag RW, Fey MF, Studer UE. Long-term results following adjuvant chemotherapy in patients with clinical stage I testicular nonseminomatous malignant germ cell tumours with high risk factors. *J Urol* 1999;161(4):1148-52.  
<http://www.ncbi.nlm.nih.gov/pubmed/10081858>
261. Tjan-Heijnen VCG, Oosterhof GON, de Wit R, de Mulder PHM. Treatment of germ cell tumours: state of the art. *Eur J Surg Oncol* 1997;23(2):110-7.  
<http://www.ncbi.nlm.nih.gov/pubmed/9158183>
262. Lowe BA. Surveillance versus nerve-sparing retroperitoneal lymphadenectomy in stage I germ cell tumours. *Urol Clin North Am* 1993;20(1):75-83.  
<http://www.ncbi.nlm.nih.gov/pubmed/8381999>

263. Gels ME, Hoekstra HJ, Sleijfer DT, Marrink J, de Bruijn HW, Molenaar WM, Freling NJ, Droste JH, Schraffordt Koops H. Detection of recurrence in patients with clinical stage I nonseminomatous testicular germ cell tumours and consequences for further follow-up: a single-center 10-year experience. *J Clin Oncol* 1995;13(5):1188-94.  
<http://www.ncbi.nlm.nih.gov/pubmed/7537802>
264. van As NJ, Gilbert DC, Money-Kyrle J, Bloomfield D, Beesley S, Dearnaley DP, Horwich A, Huddart RA. Evidence-based pragmatic guidelines for the follow-up of testicular cancer: optimising the detection of relapse. *Br J Cancer* 2008;17:98(12):1894-902.  
<http://www.ncbi.nlm.nih.gov/pubmed/18542063>
265. McLeod DG, Weiss RB, Stablein DM, Muggia FM, Paulson DF, Ellis JH, Spaulding JT, Donohue JP. Staging relationships and outcome in early stage testicular cancer: a report from the Testicular Cancer Intergroup Study. *J Urol* 1991;145(6):1178-83.  
<http://www.ncbi.nlm.nih.gov/pubmed/1851890>
266. Donohue JP, Thornhill JA, Foster RS, Rowland RG, Bihrl R. Primary retroperitoneal lymph node dissection in clinical stage A non-seminomatous germ cell testis cancer: review of the Indiana University Experience 1965-1989. *Br J Urol* 1993;71(3):326-35.  
<http://www.ncbi.nlm.nih.gov/pubmed/8386580>
267. Schmoll HJ, Weissbach L. [Diagnostik und Therapie von Hodentumouren.] Interdisziplinäre Konsensus-Konferenz, Halle (Saale), 1996. EBM IIa, IIb, III. [Diagnosis and therapy for germ cell tumours] [article in German]
268. McCaffrey JA, Bajorin DF, Motzer RJ. Risk assessment for metastatic testis cancer. *Urol Clin North Am* 1998;25(3):389-95.  
<http://www.ncbi.nlm.nih.gov/pubmed/9728209>
269. Buchholz TA, Walden TL, Prestidge BR. Cost-effectiveness of post-treatment surveillance after radiation therapy for early stage seminoma. *Cancer* 1998;82(6):1126-33.  
<http://www.ncbi.nlm.nih.gov/pubmed/9506359>
270. Tana S, Cerrotta A, Gardani G, Palazzi M, Pizzocaro G. Post surgical policy in stage I testicular seminoma: cost and benefit of prophylactic irradiation in a long-term experience. *Tumori* 1997;83(6):918-21.  
<http://www.ncbi.nlm.nih.gov/pubmed/9526584>
271. Sultanem K, Souhami L, Benk V, Bahary JP, Roman T, Shenouda G, Freeman C. Para-aortic irradiation only appears to be adequate treatment for patients with stage I seminoma of the testis. *Int J Radiat Oncol Biol Phys* 1998;40(2):455-9.  
<http://www.ncbi.nlm.nih.gov/pubmed/9457835>
272. Kiricuta IC, Sauer J, Bohndorf W. Omission of the pelvic irradiation in stage I testicular seminoma: a study of postorchidectomy paraaortic radiotherapy. *Int J Radiat Oncol Biol Phys* 1996;35(2):293-8.  
<http://www.ncbi.nlm.nih.gov/pubmed/9457835>
273. Warde P, Gospodarowicz MK, Panzarella T, Catton CN, Sturgeon JF, Moore M, Goodman P, Jewett MA. Stage I testicular seminoma: results of adjuvant irradiation and surveillance. *J Clin Oncol* 1995;13(9):2255-62.  
<http://www.ncbi.nlm.nih.gov/pubmed/7666083>
274. Fossa SD, Aass N, Kaalhus O. Radiotherapy for testicular seminoma stage I: treatment results and long-term post-irradiation morbidity in 365 patients. *Int J Radiat Oncol Biol Phys* 1989;16(2):383-8.  
<http://www.ncbi.nlm.nih.gov/pubmed/7666083>
275. Baniel J, Foster RS, Einhorn LH, Donohue JP. Late relapse of clinical stage I testicular cancer. *J Urol* 1995;154(4):1370-2.  
<http://www.ncbi.nlm.nih.gov/pubmed/7658541>
276. Stein ME, Leviov M, Drumea K, Moshkovitz B, Nativ O, Milstein D, Sabo E, Kuten A. Radiation-induced tumours in irradiated stage I testicular seminoma: results of a 25-year follow-up (1968-1993). *J Surg Oncol* 1998;67(1):38-40.  
<http://www.ncbi.nlm.nih.gov/pubmed/9457255>
277. Akimoto T, Takahashi I, Takahashi M, Yamakawa M, Hayakawa K, Mitsuhashi N, Niibe H. Long-term outcome of postorchidectomy radiation therapy for stage I and II testicular seminoma. *Anticancer Res* 1997;17(5B):3781-5.  
<http://www.ncbi.nlm.nih.gov/pubmed/9427780>
278. Von der Maase H, Specht L, Jacobsen GK, Jakobsen A, Madsen EL, Pedersen M, Rorth M, Schultz H. Surveillance following orchidectomy for stage I seminoma of the testis. *Eur J Cancer* 1993;29A(14):1931-4.  
<http://www.ncbi.nlm.nih.gov/pubmed/8280484>

279. Horwich A, Alsanjari N, A'Hern, Nicholls J, Dearnaley DP, Fisher C. Surveillance following orchidectomy for stage I testicular seminoma. *Br J Cancer* 1992;65(5):775-8.  
<http://www.ncbi.nlm.nih.gov/pubmed/1586607>
280. Germá Lluch JR, Climent MA, Villavicencio H, Gomez de Segura G, Blanco R, Mercedes A, de Andres L, Sole Balcells FJ. Treatment of stage I testicular tumours. *Br J Urol* 1993;71(4):473-7.  
<http://www.ncbi.nlm.nih.gov/pubmed/8499994>
281. Warde P, Gospodarowicz MK, Goodman PJ, Sturgeon JF, Jewett MA, Catton CN, Richmond H, Thomas GM, Duncan W, Munro AJ. Results of a policy of surveillance in stage I testicular seminoma. *Int J Radiat Oncol Biol Phys* 1993;27(1):11-5.  
<http://www.ncbi.nlm.nih.gov/pubmed/8365931>
282. Allhoff EP, Liedke S, de Riese W, Stief C, Schneider B. Stage I seminoma of the testis: adjuvant radiotherapy or surveillance? *Br J Urol* 1991;68(2):190-4.  
<http://www.ncbi.nlm.nih.gov/pubmed/1715798>
283. Fosså SD, Chen J, Schonfeld SJ, McGlynn KA, McMaster ML, Gail MH, Travis LB. Risk of contralateral testicular cancer: a population-based study of 29,515 US men. *J Natl Cancer Inst* 2005;97(14):1056-66.  
<http://www.ncbi.nlm.nih.gov/pubmed/1603030>
284. Wierecky J, Kollmannsberger C, Boehlke I, Kuczyk M, Schleicher J, Schleucher N, Metzner B, Kanz L, Hartmann JT, Bokemeyer C. Secondary leukemia after first-line high-dose chemotherapy for patients with advanced germ cell cancer. *J Cancer Res Clin Oncol* 2005;131(4):255-60.  
<http://www.ncbi.nlm.nih.gov/pubmed/15627215>
285. Nuver J, Smit AJ, Sleijfer DT, van Gessel AI, van Roon AM, van der Meer J, van den Berg MP, Hoekstra HJ, Sluiter WJ, Gietema JA. Left ventricular and cardiac autonomic function in survivors of testicular cancer. *Eur J Clin Invest* 2005;35(2):99-103.  
<http://www.ncbi.nlm.nih.gov/pubmed/15667580>
286. Huddart RA, Norman A, Shahidi M, Horwich A, Coward D, Nicholls J, Dearnaley DP. Cardiovascular disease as a long-term complication of treatment for testicular cancer. *J Clin Oncol* 2003;21(8):1513-23.  
<http://www.ncbi.nlm.nih.gov/pubmed/12697875>
287. van den Belt-Dusebout AW, Nuver J, de Wit R, Gietema JA, ten Bokkel Huinink WW, Rodrigus PT, Schimmel EC, Aleman BM, van Leeuwen FE. Long-term risk of cardiovascular disease in 5-year survivors of testicular cancer. *J Clin Oncol* 2006;24(3):467-75.  
<http://www.ncbi.nlm.nih.gov/pubmed/16421423>
288. Haugnes HS, Aass N, Fosså SD, Dahl O, Klepp O, Wist EA, Svartberg J, Wilsgaard T, Bremnes RM. Components of the metabolic syndrome in long-term survivors of testicular cancer. *Ann Oncol* 2007;18(2):241-8.  
<http://www.ncbi.nlm.nih.gov/pubmed/17060482>
289. Huddart RA, Joffe JK. Preferred treatment for stage I seminoma: a survey of Canadian radiation oncologists. *Clin Oncol (R Coll Radiol)* 2006;18(9):693-5.  
<http://www.ncbi.nlm.nih.gov/pubmed/17100155>
290. Krega S, Kalund G, Otto T, Goepel M, Rubben H. Phase II study: adjuvant single-agent carboplatin therapy for clinical stage I seminoma. *Eur Urol* 1997;31(4):405-7.  
<http://www.ncbi.nlm.nih.gov/pubmed/9187898>
291. Dieckmann KP, Krain J, Kuster J, Bruggeboes B. Adjuvant carboplatin treatment for seminoma clinical stage I. *J Cancer Res Clin Oncol* 1996;122(1):63-6.  
<http://www.ncbi.nlm.nih.gov/pubmed/8543595>
292. Bukowski RM. Management of advanced and extragonadal germ-cell tumours. *Urol Clin North Am* 1993;20(1):153-60.  
<http://www.ncbi.nlm.nih.gov/pubmed/8381995>
293. Fair W, Dalbagni G, Machele Donat S, Theodorescu D. Evaluation and follow-up of patients with urologic cancer. AUA Office of Education Publications 9958 PG, 1999.
294. Pizzocaro G. Non-seminomatous germ-cell tumours (NSGCT) of the testis: diagnosis and management, stage by stage. *Eur Urol Update Series* 1997;6:139-45.
295. Sheinfeld J, Bajorin DF, Solomon M. Management of postchemotherapy residual masses in advanced germ cell tumours. *Urol Clin North Am* 1997;3:18-23.
296. Little JS, Foster RS, Ulbright TM, Donohue JP. Unusual neoplasms detected in testis cancer patients undergoing postchemotherapy retroperitoneal lymphadenectomy. *J Urol* 1994;152(4):1144-9.  
<http://www.ncbi.nlm.nih.gov/pubmed/8072083>

## 11.2 Non-germ cell tumours

1. Cheville JC, Sebo TJ, Lager DJ, Bostwick DG, Farrow GM. Leydig cell tumour of the testis: a clinicopathologic, DNA content, and MIB-1 comparison of nonmetastasizing and metastasizing tumours. *Am J Surg Pathol* 1998;22(11):1361-7.  
<http://www.ncbi.nlm.nih.gov/pubmed/9808128>
2. Kim I, Young RH, Scully RE. Leydig cell tumours of the testis. A clinicopathological analysis of 40 cases and review of the literature. *Am J Surg Pathol* 1985;9(3):177-92.  
<http://www.ncbi.nlm.nih.gov/pubmed/3993830>
3. Matveev BP, Gurarii LL. [Leydig-cell tumours of the testis] *Urol Nefrol (Mosk)* 1997;(4):34-6. [article in Russian]  
<http://www.ncbi.nlm.nih.gov/pubmed/9381620>
4. Young RH, Koelliker DD, Scully RE. Sertoli cell tumours of the testis, not otherwise specified: a clinicopathologic analysis of 60 cases. *Am J Surg Pathol* 1998;22(6):709-21.  
<http://www.ncbi.nlm.nih.gov/pubmed/9630178>
5. Proppe KH, Scully RE. Large-cell calcifying Sertoli cell tumour of the testis. *Am J Clin Pathol* 1980;74(5):607-19.  
<http://www.ncbi.nlm.nih.gov/pubmed/7446466>
6. Zukerberg LR, Young RH, Scully RE. Sclerosing Sertoli cell tumour of the testis. A report of 10 cases. *Am J Surg Pathol* 1991;15(9):829-34.  
<http://www.ncbi.nlm.nih.gov/pubmed/1719830>
7. WHO histological classification of testis tumours, In: Eble JN, Sauter G, Epstein JI, Sesterhenn IA (eds). *Pathology & Genetics. Tumours of the urinary system and male genital organs*. Lyon: IARC Press, 2004: 218, pp. 250-262.
8. Ulbright TM, Amin MB, Young RH. Tumours of the testis, adnexia, spermatic cord and scrotum. *AFIP* 1999.
9. Cheville JC, Sebo TJ, Lager DJ, Bostwick DG, Farrow GM. Leydig cell tumour of the testis: a clinicopathologic, DNA content, and MIB-1 comparison of non-metastasizing and metastasizing tumours. *Am J Surg Pathol* 1998;22(11):1361-7.  
<http://www.ncbi.nlm.nih.gov/pubmed/9808128>
10. McCluggage WG, Shanks JH, Arthur K, Banerjee SS. Cellular proliferation and nuclear ploidy assessments augment established prognostic factors in predicting malignancy in testicular Leydig cell tumours. *Histopathology* 1998;33(4):361-8.  
<http://www.ncbi.nlm.nih.gov/pubmed/9822927>
11. Mineur P, de Cooman S, Hustin J, Verhoeven G, de Hertogh E. Feminizing testicular Leydig cell tumour: hormonal profile before and after unilateral orchidectomy. *J Clin Endocrinol Metab* 1987;64(4):686-91.  
<http://www.ncbi.nlm.nih.gov/pubmed/3818898>
12. Reznik Y, Rieu M, Kuhn JM, Mandard JC, Bottet P, Lemonnier D, Bekka S, Mahoudeau J. Luteinizing hormone regulation by sex steroids in men with germinal and Leydig cell tumours. *Clin Endocrinol (Oxf)* 1993;38(5):487-93.  
<http://www.ncbi.nlm.nih.gov/pubmed/8392454>
13. Bercovici JP, Nahoul K, Tater D, Charles JF, Scholler R. Hormonal profile of Leydig cell tumours with gynecomastia. *J Clin Endocrinol Metab* 1984;59(4):625-30.  
<http://www.ncbi.nlm.nih.gov/pubmed/6434575>
14. Haas GP, Pittaluga S, Gomella L, Travis WD, Sherins RJ, Doppman JL, Linehan WL, Robertson C. Clinical occult Leydig cell tumour presenting with gynecomastia. *J Urol* 1989;142(5):1325-7.  
<http://www.ncbi.nlm.nih.gov/pubmed/2810523>
15. Ruthgers JL, Young RH, Scully RE. The testicular 'tumour' of the adrenogenital syndrome. A report of six cases and review of the literature on testicular masses in patients with adrenocortical disorders. *Am J Surg Pathol* 1988;12(7):503-13.  
<http://www.ncbi.nlm.nih.gov/pubmed/3291624>
16. Maizlin ZV, Belenky A, Kunichezky M, Sandbank J, Strauss S. Leydig cell tumours of the testis: gray scale and color Doppler sonographic appearance. *J Ultrasound Med* 2004;23(7):959-64.  
<http://www.ncbi.nlm.nih.gov/pubmed/15292565>
17. Ponce de Leon Roca J, Algaba Arrea F, Bassas Arnau L, Villavicencio Mavrich H. [Leydig-cell tumours of the testis] *Arch Esp Urol* 2000;53(6):453-8. [article in Spanish]  
<http://www.ncbi.nlm.nih.gov/pubmed/11002512>
18. Wegner HE, Dieckmann KP, Herbst H, Andresen R, Miller K. Leydig cell tumour—comparison of results of radical and testis sparing surgery in a single center. *Urol Int* 1997;59(3):170-3.  
<http://www.ncbi.nlm.nih.gov/pubmed/9428434>

19. Mosharafa AA, Foster RS, Bihrlé R, Koch MO, Ulbright TM, Einhorn LH, Donohue JP. Does retroperitoneal lymph node dissection have a curative role for patients with sex cord-stromal testicular tumours? *Cancer* 2003;98(4):753-7.  
<http://www.ncbi.nlm.nih.gov/pubmed/9428434>
20. Giglio M, Medica M, De Rose AF, Germinale F, Ravetti JL, Carmignani G. Testicular Sertoli cell tumours and relative sub-types. Analysis of clinical and prognostic features. *Urol Int* 2003;70(3): 205-10.  
<http://www.ncbi.nlm.nih.gov/pubmed/12660458>
21. Jacobsen GK. Malignant Sertoli cell tumours of the testis. *J Urol Pathol* 1993;1:233-55.
22. Kratzer SS, Ulbright TM, Talerman A, Srigley JR, Roth LM, Wahle GR, Moussa M, Stephens JK, Millos A, Young RH. Large cell calcifying Sertoli cell tumour of the testis: contrasting features of six malignant and six benign tumours and a review of the literature. *Am J Surg Pathol* 1997;21(11): 1271-80.  
<http://www.ncbi.nlm.nih.gov/pubmed/9351565>
23. Henley JD, Young RH, Ulbright TM. Malignant Sertoli cell tumours of the testis: a study of 13 examples of a neoplasm frequently misinterpreted as seminoma. *Am J Surg Pathol* 2002;26:541-50.
24. Plata C, Algaba F, Andujar M, Nistal M, Stocks P, Martinez JL, Nogales FF. Large cell calcifying Sertoli cell tumour of the testis. *Histopathology* 1995;26(3):255-9.  
<http://www.ncbi.nlm.nih.gov/pubmed/7541015>
25. Anderson GA. Sclerosing Sertoli cell tumour of the testis: a distinct histological subtype. *J Urol* 1995;154(5):1756-8. Review.  
<http://www.ncbi.nlm.nih.gov/pubmed/7563340>
26. Grabrilove JL, Freiberg EK, Leiter E, Nicolis GL. Feminizing and non-feminizing Sertoli cell tumour. *J Urol* 1980;124(6):757-67.  
<http://www.ncbi.nlm.nih.gov/pubmed/7003168>
27. Gierke CL, King BF, Bostwick DG, Choyke PL, Hattery RR. Large-cell calcifying Sertoli cell tumour of the testis: appearance at sonography. *AJR Am J Roentgenol* 1994;163(2):373-5.  
<http://www.ncbi.nlm.nih.gov/pubmed/8037034>
28. Chang B, Borer JG, Tan PE, Diamond DA. Large-cell calcifying Sertoli cell tumour of the testis: case report and review of the literature. *Urology* 1998;52(3):520-2.  
<http://www.ncbi.nlm.nih.gov/pubmed/9730477>
29. Washecka R, Dresner MI, Honda SA. Testicular tumours in Carney's complex. *J Urol* 2002;167(3):1299-302.  
<http://www.ncbi.nlm.nih.gov/pubmed/11832717>
30. Young S, Gooneratne S, Straus FH, Zeller WP, Bulun SE, Rosenthal IM. Feminizing Sertoli cell tumours in boys with Peutz-Jeghers syndrome. *Am J Surg Pathol* 1995;19(1):50-8.  
<http://www.ncbi.nlm.nih.gov/pubmed/7802138>
31. Kaplan GW, Cromie WJ, Kelalis PP, Silber I, Tank ES Jr. Gonadal stromal tumours: a report of the prepubertal testicular tumours registry. *J Urol* 1986;136(1Pt2):300-2.  
<http://www.ncbi.nlm.nih.gov/pubmed/3723681>
32. Al-Bozom IA, El-Faqih SR, Hassan SH, El-Tiraifi AE, Talic RF. Granulosa cell tumour of the adult type. A case report and review of the literature of a very rare testicular tumour. *Arch Pathol Lab Med* 2000;124(10):1525-8.  
<http://www.ncbi.nlm.nih.gov/pubmed/11035589>
33. Perito PE, Ciancio G, Civantos F, Politano VA. Sertoli-Leydig cell testicular tumour. case report and review of sex cord/gonadal stromal tumour histogenesis. *J Urol* 1992;148(3):883-5.  
<http://www.ncbi.nlm.nih.gov/pubmed/1512847>
34. Scully RE. Gonadoblastoma. A review of 74 cases. *Cancer* 1970;25(6):1340-56.  
<http://www.ncbi.nlm.nih.gov/pubmed/4193741>
35. Ulbright TM, Srigley JR, Reuter VE, Wojno K, Roth LM, Young RH. Sex-cord-stromal tumours of the testis with entrapped germ cells: a lesion mimicking unclassified mixed germ cell sex cord-stromal tumours. *Am J Surg Pathol* 2000;24(4):535-42.  
<http://www.ncbi.nlm.nih.gov/pubmed/10757400>

## 12. ABBREVIATIONS USED IN THE TEXT

*This list is not comprehensive for the most common abbreviations.*

AFP	alpha-fetoprotein
AUC	area under curve
Cg A	chromogranine A
CI	confidence interval
CS	clinical stage
CT	computed tomography
EAU	European Association of Urology
EBM	evidence-based medicine
EP	etoposide, cisplatin
EORTC	European Organisation for Research and Treatment of Cancer
FDG-PET	fluorodeoxyglucose-positron emission tomography
FSH	follicle-stimulating hormone
GI	gastrointestinal
G-CSF	granulocyte colony-stimulating factor
GR	grade of recommendation
hCG	human chorionic gonadotrophin
HPF	high-power field
IGCCCG	International Germ Cell Cancer Collaborative Group
LE	level of evidence
LH	luteinising hormone
LDH	lactate dehydrogenase
MRC	Medical Research Council
MRI	magnetic resonance imaging
NSGCT	non-seminomatous germ cell tumour
PA	para-aortic
PEB	cisplatin, etoposide, bleomycin
PEI	cisplatin, etoposide, ifosfamide
PET	positron emission tomography
PFS	progression-free survival
PS	pathological stage
PLAP	placental alkaline phosphatase
PVB	cisplatin, vinblastine, bleomycin
RPLND	retroperitoneal lymph node dissection
SWENOTECA	Swedish-Norwegian Testicular Cancer Project
Tin	carcinoma <i>in situ</i> pathological definition: undifferentiated intratubular germ cell carcinoma
TIP	paclitaxel, ifosfamide, cisplatin
TNM	Tumour Node Metastasis
UICC	International Union Against Cancer
ULN	upper limit of normal
VeIP	vinblastine, ifosfamide, cisplatin
WHO	World Health Organization
VIP (VP-16)	etoposide, ifosfamide, cisplatin

### Conflict of interest

All members of the Testicular Cancer Guidelines writing panel have provided disclosure statements on all relationships that they have and that might be perceived to be a potential source of conflict of interest. This information is kept on file in the European Association of Urology Central Office database. This guidelines document was developed with the financial support of the European Association of Urology. No external sources of funding and support have been involved. The EAU is a non-profit organisation and funding is limited to administrative assistance and travel and meeting expenses. No honoraria or other reimbursements have been provided.