

Guidelines on Penile Cancer

G. Pizzocaro (Chairman), F. Algaba, S. Horenblas, E. Solsona,
S. Tana, H. Van Der Poel, N. Watkin

TABLE OF CONTENTS

PAGE

1.	INTRODUCTION	4
2.	METHODOLOGY	4
2.1	References	4
3.	DEFINITION OF PENILE CANCER	5
4.	EPIDEMIOLOGY	5
4.1	References	6
5.	RISK FACTORS AND PREVENTION	6
5.1	References	7
6.	TNM CLASSIFICATION AND PATHOLOGY	8
6.1	TNM classification	8
6.1.1	References	9
6.2	Pathology	9
6.2.1	Penile biopsy	10
6.2.2.1	Pathological categories	10
6.2.2.2	Histology and metastatic risk	10
6.2.3	References	10
7.	DIAGNOSIS AND STAGING	11
7.1	Primary lesion	11
7.2	Regional lymph nodes	11
7.2.1	Lymphatic drainage of the penis	11
7.2.2	Non-palpable nodes	12
7.2.3	Risk factors	12
7.2.4	Palpable nodes	12
7.3	Distant metastases	12
7.4	Guidelines for the diagnosis of penile cancer	13
7.5	References	13
8.	TREATMENT	16
8.1	Primary tumour	16
8.1.1	Category Tis and Ta	16
8.1.2	Category T1G1	16
8.1.3	Category T1G2-3	16
8.1.4	Category T2 (of the glans)	17
8.1.5	Category T2 (of the corpora) and T3	17
8.1.6	Category T4	17
8.1.7	Local disease recurrence	17
8.1.8	Technical aspects	17
8.1.8.1	Conservative surgery	17
8.1.8.2	Radical amputation	17
8.1.9	Radiotherapy	17
8.1.9.1	Recommendations for radiotherapy	18
8.1.10	Guidelines for treatment strategies for primary tumour	18
8.2	Treatment of regional lymph nodes	19
8.2.1	Management of patients with non-palpable inguinal nodes	19
8.2.1.1	Surveillance	19
8.2.1.2	Prognostic factors	19
8.2.1.3	Sentinel node biopsy (SNB)	19
8.2.2	Management of patients with palpable inguinal nodes	19
8.2.2.1	Inguinal LAD	20
8.2.2.2	Modified inguinal LAD	20
8.2.2.3	The role of pelvic LAD	20
8.2.2.4	Video-endoscopic inguinal and pelvic LAD	20

8.2.3	Adjuvant chemotherapy	20
8.2.4	Management of patients with fixed or relapsed inguinal nodes	21
8.2.5	The role of radiotherapy	21
8.2.6	Guidelines for treatment strategies for nodal metastases	22
8.3	References	22
9.	FOLLOW-UP	27
9.1	How to follow-up	27
9.2	When to follow-up	27
9.3	Primary tumour	27
9.4	Regional recurrences	27
9.5	Guidelines for follow-up in penile cancer	28
9.6	References	28
10.	QUALITY OF LIFE	29
10.1	Sexuality and fertility after penile cancer	29
10.1.1	Sexual activity and quality of life after penile cancer laser treatment	29
10.1.2	Sexual function after partial penectomy for penile cancer	29
10.2	Sexual mutilation, relapse and death	29
10.3	References	30
11.	ABBREVIATIONS USED IN THE TEXT	31

1. INTRODUCTION

The European Association of Urology (EAU) Guidelines Group on Penile Cancer has prepared this guidelines document to assist medical professionals in the management of penile cancer. The guidelines aim to provide detailed, up-to-date information, based on recent developments in our understanding and management of penile squamous cell carcinoma (SCC). However, it must be emphasised that these guidelines provide a standardised general approach to treating a patient and that the Guidelines provide guidance and recommendations without legal authority or implications.

Publication history information: The Penile Cancer Guidelines were first published in 2001 and updated in 2004, followed by this full text update in 2009.

2. METHODOLOGY

To update the last published guidelines in 2004, a meticulous PubMed literature search between October 2003 and October 2008 was carried out by all members of the Penile Cancer Consensus Group according to their field of interest (1). A total of 980 abstracts published on SCC of the penis were identified.

Only one evidence-based peer-reviewed document was published during the period 2004 to 2008. This was the physician data query (PDQ) on 'Penile Cancer Treatment' (Health Professional Version) published by the National Cancer Institute, National Institutes of Health (Bethesda, USA) (2). No randomised controlled trials or Cochrane reviews were published.

References used in the text have been assessed according to their level of scientific evidence (Table 1) and guideline recommendations have been graded (Table 2) according to the Oxford Centre for Evidence-based Medicine Levels of Evidence (3). The aim of grading recommendations is to provide transparency between the underlying evidence and the recommendation given.

Publication history: The EAU Penile Cancer Guidelines were first published in 2000. Partial updates were achieved in 2001 and 2004, followed by the current version which presents a full text update. Additionally, a quick reference guide is available. All texts can be viewed and downloaded for personal use at the society website: <http://www.uroweb.org/professional-resources/guidelines/>.

Table 1: Level of evidence

Level	Type of evidence
1a	Evidence obtained from meta-analysis of randomised trials
1b	Evidence obtained from at least one randomised trial
2a	Evidence obtained from one well-designed controlled study without randomisation
2b	Evidence obtained from at least one other type of well-designed quasi-experimental study
3	Evidence obtained from well-designed non-experimental studies, such as comparative studies, correlation studies and case reports
4	Evidence obtained from expert committee reports or opinions or clinical experience of respected authorities

Table 2: Grade of recommendation

Grade	Nature of recommendations
A	Based on clinical studies of good quality and consistency addressing the specific recommendations and including at least one randomised trial
B	Based on well-conducted clinical studies, but without randomised clinical trials
C	Made despite the absence of directly applicable clinical studies of good quality

**modified from Sackett et al. (3)*

2.1 REFERENCES

1. Solsona E, Algaba F, Horenblas S, Pizzocaro G, Windahl T. EAU guidelines on penile cancer. *Eur Urol* 2004;46(1):1-8.
<http://www.ncbi.nlm.nih.gov/pubmed/15183542>

2. National Cancer Institute. Penile Cancer Treatment (PDQ). Health Professional Version. US National Institutes of Health, 2008, pp. 1-13.
<http://www.cancer.gov/cancertopics/pdq/treatment/penile/healthprofessional/allpages>
3. Oxford Centre for Evidence-based Medicine Levels of Evidence (May 2001). Produced by Bob Phillips, Chris Ball, Dave Sackett, Doug Badenoch, Sharon Straus, Brian Haynes, Martin Dawes since November 1998.
<http://www.cebm.net/index.aspx?o=1025> [Access date February 2009]

3. DEFINITION OF PENILE CANCER

Penile cancer is a relatively rare SCC. It usually originates in the epithelium of the inner prepuce and glans. It shares a similar pathology and natural history with SCC of the oropharynx, female genitalia (cervix, vagina and vulva) and anus. Phimosis, poor hygiene and smoking are the major risk factors for penile cancer. Typing has been done of the human papillomaviruses (HPV) responsible for the sexual transmission of genital warts, condyloma acuminata SCC of the penis.

An improved understanding of the natural history of the disease, earlier diagnosis, better technology, research group collaboration and centralisation of patients in centres of excellence has improved the cure rate for penile cancer from 50% in the 1990s to 80% in 2008.

4. EPIDEMIOLOGY

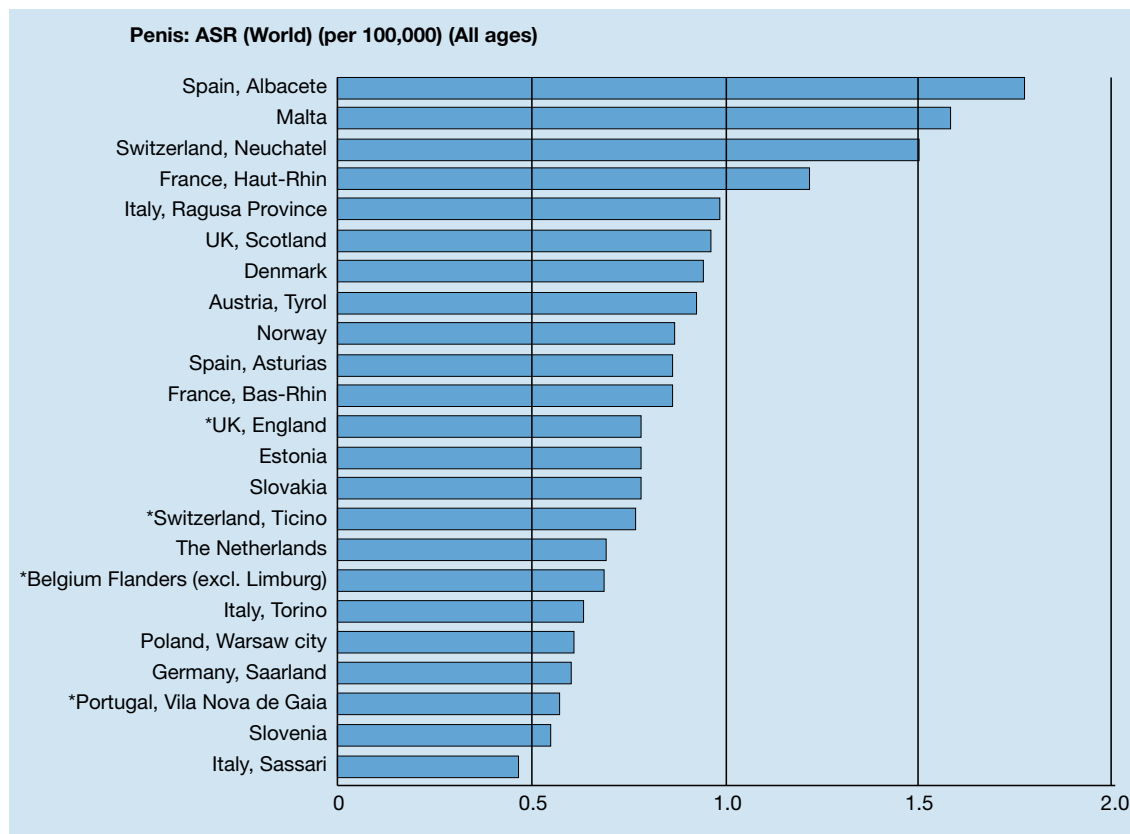
In Western countries, primary malignant penile cancer is uncommon, with an incidence of less than 1.00 per 100,000 males in Europe and the United States of America (USA) (1, 2). There are, however, important geographical variations, with several European regions (Figure 1) reporting an incidence greater than 1.00 per 100,000 males (3). Incidence is also affected by race and ethnicity in North America (1), with the highest incidence of penile cancer found in white Hispanics (1.01 per 100,000), followed by Alaskan, Native/American Indians (0.77 per 100,000), Blacks (0.62 per 100,000) and White non-Hispanics (0.51 per 100,000).

In contrast, in the non-Western world, the incidence rate of penile cancer is much higher and can represent 10-20% of malignant disease in men ranging from an age-adjusted incidence of 0.7 to 3 per 100,000 people in India to 8.3 per 100,000 men in Brazil and even higher in Uganda, where it is the most commonly diagnosed cancer.

Important risk factors include social and cultural habits, hygienic and religious practices (4). Penile carcinoma is rare in communities that practise circumcision in newborns or before puberty (Jews, Muslims and the Ibos of Nigeria). Early circumcision reduces the risk of penile cancer by 3 to 5 times. Adult circumcision does not protect against penile cancer.

In the USA, the overall age-adjusted incidence rate decreased considerably between 1973 and 2002 from 0.84 per 100,000 in 1973-1982 to 0.69 per 100,000 in 1983-1992 and further to 0.58 per 100,000 in 1993-2002 (1). In European countries, the incidence during the 1980s and 1990s was stable or increased slightly (2). The incidence rate continuously increases with age (2); however, the disease has been reported in younger men and in children.

Figure 1: Annual incidence rate (world standardised) by European region/country*



*From Parkin et al. (2003) (3).

4.1 REFERENCES

1. Barnholtz-Sloan JS, Maldonado JL, Pow-sang J, Giuliano AR. Incidence trends in primary penile cancer. *Urol Oncol* 2007;25(5):361-7. <http://www.ncbi.nlm.nih.gov/pubmed/17826651>
2. ENCR (European Network of Cancer Registries). Eurocim version 4.0. European incidence database V2.2 (1999). Lyon, France: IARC, 2001.
3. Parkin DM, Whelan SL, Ferlay J, Teppo L, Thomas DB (eds). *Cancer Incidence in Five Continents*. Vol. VIII. IARC Scientific Publications. No. 155. Lyon, France: IARC, 2002. <http://www.iarc.fr/en/Publications/PDFs-online/Cancer-Epidemiology/IARC-Scientific-Publication-No.-155>
4. Misra S, Chaturvedi A, Misra NC. Penile carcinoma: a challenge for the developing world. *Lancet Oncol* 2004;5(4):240-7. <http://www.ncbi.nlm.nih.gov/pubmed/15050955>

5. RISK FACTORS AND PREVENTION

Risk factors for penile cancer were identified by the Karolinska Institute from a Medline search of published literature from 1966-2000 (1). Strong risk factors (OR > 10) identified by case-control studies included (level of evidence: 2a):

- phimosis
- chronic inflammatory conditions, e.g. balanoposthitis, lichen sclerosus and atrophicus (balanitis xerotica obliterans)
- treatment with sporalene and ultraviolet A photochemotherapy.

Sexual history (multiple partners, early age of first intercourse) and a self-reported history of condylomata were associated with a 3- to 5-fold increased risk of penile cancer. Smoking is also a risk factor. Cervical cancer in the wife was not consistently associated with penile cancer in the husband.

In many case series, HPV DNA was identified in 70-100% intraepithelial neoplasia and in 40-50% of cases with invasive penile cancer. These results were confirmed by a population-based case control study (2). Among men not circumcised in childhood, phimosis was strongly associated with the development of invasive penile cancer (OR = 11.4; 95% CI 5.0-25.9), while cigarette smoking was associated with a 4.5-fold increased risk (95% CI 2.0-10.1). Human papillomavirus DNA was detected in 80% of tumour specimens; 69% were positive for HPV-16 (level of evidence: 2a).

Smegma as a carcinogen has been clearly excluded (3). The risk of cancer among patients with condyloma acuminata increased for vulva, vagina, penis and anus (4) (level of evidence: 2b).

Human papillomavirus-16 and -18 have a causal role in 70% of cancers of the cervix, vagina and anus and about 30-40% of cancers of the vulva, penis and oropharynx. Other cofactors are very likely to be necessary for progression from HPV infection to cancer (5).

In June 2006, the US Food and Drug Administration (FDA) licensed the first vaccine to prevent cervical cancer and other HPV-associated diseases in women (6). The vaccine protects against infection with HPV-6, HPV-11, HPV-16 and HPV-18, which together are responsible for 70% of cervical cancers and 90% of genital warts. Human papillomavirus is highly transmissible, with a peak incidence soon after the onset of sexual activity. The recommended age for vaccination in females is 11-12 years (7), with catch-up vaccination recommended in females aged 13-26 years.

However, vaccination is not a substitute for routine cervical cancer screening and vaccinated females should continue to have cervical cancer screening. Vaccination against HPV has also been recommended in males (8). Although a study found that mid-adult (25 years or older) women have a high level of acceptance for HPV vaccination (9), only 33% of males wanted the HPV vaccine, 27% did not and 40% were undecided (10).

Interestingly, the presence of high-risk HPV DNA in penile cancer does not compromise prognosis.

An early study (11) found no difference between HPV DNA-negative and HPV DNA-positive patients in lymph node metastases and 10-year survival rate. In a more recent study (12), disease-specific 5-year survival in the high-risk HPV-negative group was 78% versus 93% in the high-risk HPV-positive group (log rank test $p = 0.03$). This suggests the presence of high-risk HPV confers a survival advantage in patients with penile cancer. The virus plays an important role in oncogenesis through interaction with oncogenes and tumour suppressor genes (P53 and Rb-gene) (13).

5.1 REFERENCES

1. Dillner J, von Krogh G, Horenblas S, Meijer CJ. Etiology of squamous cell carcinoma of the penis. *Scand J Urol Nephrol Suppl* 2000;(205):189-93.
<http://www.ncbi.nlm.nih.gov/pubmed/11144896>
2. Daling JR, Madeleine MM, Johnson LG, Schwartz SM, Shera KA, Wurscher MA, Carter JJ, Porter PL, Galloway DA, McDougall JK, Krieger JN. Penile cancer: importance of circumcision, human papillomavirus and smoking in situ and invasive disease. *Int J Cancer* 2005;116(4):606-16.
<http://www.ncbi.nlm.nih.gov/pubmed/15825185>
3. Van Howe RS, Hodges FM. The carcinogenicity of smegma: debunking a myth. *Eur Acad Dermatol Venereol* 2006;20(9):1046-54.
<http://www.ncbi.nlm.nih.gov/pubmed/16987256>
4. Nordenvall C, Chang ET, Adami HO, Ye W. Cancer risk among patients with condylomata acuminata. *Int J Cancer* 2006;119(4):888-93.
<http://www.ncbi.nlm.nih.gov/pubmed/16557590>
5. Munoz N, Castelisague X, de Gonzalez AB, Gissmann L. HPV in the etiology of human cancer. *Vaccine* 2006;24(Suppl 3):S3/1-10.
<http://www.ncbi.nlm.nih.gov/pubmed/16949995>
6. Huang CM. Human papillomavirus and vaccination. *Mayo Clin Proc* 2008;83(6):701-6.
<http://www.ncbi.nlm.nih.gov/pubmed/18533087>
7. Markowitz LE, Dunne EF, Saraiya M, Lawson HW, Chesson H, Unger ER; Centers for Disease Control and Prevention (CDC); Advisory Committee on Immunization Practices (ACIP). Quadrivalent Human Papillomavirus Vaccine: recommendations of the Advisory Committee on Immunization Practices (ACIP). *MMWR Recomm Rep* 2007;56(RR-2):1-24.
<http://www.ncbi.nlm.nih.gov/pubmed/17380109>
8. Giuliano AR. Human papillomavirus vaccination in males. *Gynecol Oncol* 2007;107(2 Suppl 1):S24-S26.
<http://www.ncbi.nlm.nih.gov/pubmed/17938015>

9. Ferris DG, Waller JL, Owen A and Smith J. Midadult women's attitudes about receiving the prophylactic human papillomavirus vaccine. *J Low Genit Tract Dis* 2007;11(3):166-72.
<http://www.ncbi.nlm.nih.gov/pubmed/17596762>
10. Ferris DG, Waller JL, Miller J, Patel P, Jackson L, Price GA, Wilson C. Men's attitudes toward receiving the human papillomavirus vaccine. *J Low Genit Tract Dis* 2008;12(4):276-81.
<http://www.ncbi.nlm.nih.gov/pubmed/18820541>
11. Bezerra AL, Lopes A, Santiago GH, Ribeiro KC, Latorre MR, Villa LL. Human papillomavirus as a prognostic factor in carcinoma of the penis: analysis of 82 patients treated with amputation and bilateral lymphadenectomy. *Cancer* 2001;15;91(12):5-21.
<http://www.ncbi.nlm.nih.gov/pubmed/11413520>
12. Lont AP, Kroon BK, Horenblas S, Gallee MP, Berkhof J, Meijer CJ, Snijders PJ. Presence of high risk human papillomavirus DNA in penile carcinoma predicts favorable outcome in survival. *Int J Cancer* 2006;119(5):1078-81.
<http://www.ncbi.nlm.nih.gov/pubmed/16570278>
13. Kayes O, Ahmed HU, Arya M, Minhas S. Molecular and genetic pathways in penile cancer. *Lancet Oncol* 2007;8(5):420-9.
<http://www.ncbi.nlm.nih.gov/pubmed/17466899>

6. TNM CLASSIFICATION AND PATHOLOGY

6.1 TNM classification

The 2002 UICC Tumour Node Metastasis (TNM) classification (1) for penile cancer is shown in Table 3.

Table 3: 2002 TNM (Tumour, Node, Metastasis) classification of penile cancer

T - Primary tumour

- TX Primary tumour cannot be assessed
- T0 No evidence of primary tumour
- Tis Carcinoma in situ
- Ta Non-invasive verrucous carcinoma
- T1 Tumour invades subepithelial connective tissue
- T2 Tumour invades corpus spongiosum or cavernosum
- T3 Tumour invades urethra or prostate
- T4 Tumour invades other adjacent structures

N - Regional lymph nodes

- NX Regional lymph nodes cannot be assessed
- N0 No evidence of lymph node metastasis
- N1 Metastasis in a single inguinal lymph node
- N2 Metastasis in multiple or bilateral superficial lymph nodes
- N3 Metastasis in deep inguinal or pelvic lymph nodes, unilateral or bilateral

M - Distant metastases

- MX Distant metastases cannot be assessed
 - M0 No evidence of distant metastases
 - M1 Distant metastases
-

This classification is in need of an update, particularly the definition of T2 category, as the prognosis of patients with tumour invasion of the corpus spongiosum is much better than invasion of the corpus cavernosum (2, 3).

Rees et al. (2) reported on 72 patients with T2 tumours. Both local recurrence (35% vs 17%) and mortality (30% vs 21%) rates were higher in patients with tunical or cavernosal involvement after a mean follow-up of 3 years (level of evidence: 2b). The authors proposed defining T2a patients by spongiosum-only invasion and T2b patients by involvement of tunica or corpus cavernosum.

However, a deeper analysis resulted in severe criticism and a new proposal for classification (3). A retrospective analysis of the records of 513 patients treated between 1956 and 2006 confirmed the above-mentioned difference between tumour invasion of corpus spongiosum and cavernosum. It also confirmed that there were no differences in long-term survival between T2 and T3, and no

significant differences between N1 and N2 in the 1987-2002 TNM classification (level of evidence: 2a). A new TNM classification was therefore proposed for T2, T3, T4 and N1, N2, N3 (Table 4) (3). In the new proposed classification, retroperitoneal node metastases are considered to be distant metastases as for the neck, lung and other visceral organs. The new classification is much more appropriate than the present TNM categories, but it needs to be confirmed by UICC.

Table 4: Proposed modification to 1987-2002 TNM classification*

T - Primary tumour

- TX, T0, Tis, Ta and T1 Unchanged
- T2 Tumour invades corpus spongiosum
- T3 Tumour invades corpus cavernosum
- T4 Tumour invades adjacent structures (e.g. urethra, prostate)

N - Regional lymph nodes

- Nx and N0 Unchanged
 - N1 Unilateral inguinal metastases, mobile
 - N2 Bilateral inguinal metastases
 - N3 Fixed inguinal metastases or metastases in pelvic lymph nodes
-

*From Leijtje et al. (2008) (3).

6.1.1 References

1. Sobin LH, Wittekind C. TNM Classification of Malignant Tumours. Philadelphia, PA: Wiley-Liss, 2002.
2. Rees RW, Freeman A, Borley N, Ralf DJ, Minhas S. PT2 penile squamous cell carcinomas: cavernosus vs. spongiosus invasion. Eur Urol Suppl 2008;7(3):111 (abstr 163).
3. Leijtje JA, Gallee M, Antonini N, Horenblas S. Evaluation of current TNM classification of penile carcinoma. J Urol 2008;180(3):933-8; discussion 938.
<http://www.ncbi.nlm.nih.gov/pubmed/18635216>

6.2 Pathology

Squamous cell carcinoma accounts for more than 95% of cases of malignant disease of the penis. Malignant melanomas and basal cell carcinoma are much less common. It is not known how often SCC is preceded by premalignant lesions (1). Although SCC is the most common penile neoplasia, different types and varying growth patterns have been identified (2-4) (Tables 5 and 6).

Table 5: Premalignant lesions

Lesions sporadically associated with SCC of the penis

- Cutaneous horn of the penis
- Bowenoid papulosis of the penis
- Balanitis xerotica obliterans (lichen sclerosus et atrophicus)

Lesions at high risk of developing SCC of the penis (up to one-third transform to invasive SCC)

- Penile intraepithelial neoplasia (carcinoma *in situ*): erythroplasia of Queyrat and Bowen's disease
-

LE = level of evidence; SCC = squamous cell carcinoma.

Table 6: Penile SCC

Types of SCC

- Classic
- Basaloid
- Verrucous and its varieties (2):
 - Warty (condylomatous) carcinoma
 - Verrucous carcinoma
 - Papillary carcinoma
 - Hybrid verrucous carcinoma
 - Mixed carcinomas (warty basaloid, adenobasaloid carcinoma)
- Sarcomatoid
- Adenosquamous

Growth patterns of SCC

- Superficial spread
- Nodular or vertical-phase growth
- Verrucous

Differentiation grading systems for SCC

- Broders' system (5)
- Maiche's system score (6)

SCC = squamous cell carcinoma.

6.2.1 Penile biopsy

There is no need for biopsy if:

- There is no doubt about the diagnosis and/or
- Treatment of the lymph nodes is postponed after treatment of the primary tumour and/ or after histological examinations of the sentinel node(s).

There is a need for histological confirmation if:

- There is doubt about the exact nature of the lesion (metastasis, melanoma, etc)
- Treatment of the lymph nodes is based on pre-operative histological information (risk-adapted strategy).

In these cases an adequate biopsy is advised. When performing a biopsy, it is important to consider the findings from a study of biopsy size. The study of biopsies with an average size of 1.1 cm found there was:

- difficulty in evaluating the extent of depth in 91% of biopsies
- discordance between the grade at biopsy and the final specimen in 30% of cases
- failure to detect cancer in 3.5% (1)
- Thus, although a punch biopsy may be sufficient for superficial lesions, an excisional biopsy is preferred.

6.2.2.1 Pathological categories

Traditionally, squamous cell carcinomas were considered as superficial or invasive. However, Cubilla et al. (2) has divided penile carcinoma into four categories:

- superficial spreading
- vertical growth
- verrucous
- multicentric.

Different types of growth have different prognoses (3) and different ways of dissemination. The limits of surgical partial resections must therefore be set according to the growth pattern at the time of evaluation of the frozen sections (4). If the margins are studied following these criteria (including urethral and periurethral tissue), only 3-4 mm of tumourfree tissue is sufficient to consider the surgical margins to be negative (7). Basaloid SSC is a cellular subtype that is better recognised than before. It is highly aggressive. (8)

6.2.2.2 Histology and metastatic risk

Histological subtypes carry different risks of developing metastatic lymph nodes:

- condylomatous: 18.2%
- SCC: 56.7%
- sarcomatoid carcinoma: 89% (9).

Similarly, invasion pattern (10) and vascular invasion (10, 11) are correlated with lymph node metastases, with 23.1% of positive lymph nodes associated with a nodular pattern and 64.6% with an infiltrative pattern.

6.2.3 References

1. Velazquez EF, Barreto JE, Rodriguez I, Piris A, Cubilla AL. Limitations in the interpretation of biopsies in patients with penile squamous cell carcinoma. *Int J Surg Pathol* 2004;12(2):139-46.
<http://www.ncbi.nlm.nih.gov/pubmed/15173919>
2. Cubilla AL, Barreto J, Caballero C, Ayala G, Riveros M. Pathologic features of epidermoid carcinoma of the penis. A prospective study of 66 cases. *Am J Surg Pathol* 1993;17(8):753-63.
<http://www.ncbi.nlm.nih.gov/pubmed/8338190>

3. Villavicencio H, Rubio-Briones J, Regalado R, Chéchile G, Algaba F, Palou J. Grade, local stage and growth pattern as prognostic factors in carcinoma of the penis. *Eur Urol* 1997;32(4):442-7.
<http://www.ncbi.nlm.nih.gov/pubmed/9412803>
4. Velazquez EF, Soskin A, Bock A, Codas R, Barreto JE, Cubilla AL. Positive resection margins in partial penectomies: sites of involvement and proposal of local routes of spread of penile squamous cell carcinoma. *Am J Surg Pathol* 2004;28(3):384-9.
<http://www.ncbi.nlm.nih.gov/pubmed/15104302>
5. Broders AC. Squamous cell epithelioma of the skin: A study of 256 cases. *Ann Surg* 1921;73(2):141-160.
<http://www.ncbi.nlm.nih.gov/pubmed/17864409>
6. Maiche AG, Pyrhönen S, Karkinen M. Histological grading of squamous cell carcinoma of the penis: a new score system. *Br J Urol* 1991;67(5):522-526.
<http://www.ncbi.nlm.nih.gov/pubmed/1710163>
7. Minhas S, Kayes O, Hegarty P, Kumar P, Freeman A, Ralph D. What surgical resection margins are required to achieve oncological control in men with primary penile cancer? *BJU Int* 2005;96(7):1040-3.
<http://www.ncbi.nlm.nih.gov/pubmed/16225525>
8. Cubilla AL, Reuter V, Velazquez E, Piris A, Saito S, Young RH. Histologic classification of penile carcinoma and its relation to outcome in 61 patients with primary resection. *Int J Surg Pathol* 2001;9(2):111-20.
<http://www.ncbi.nlm.nih.gov/pubmed/11484498>
9. Bezerra AL, Lopes A, Landman G, Alencar GN, Torloni H, Villa LL. Clinicopathologic features and human papillomavirus DNA prevalence of warty and squamous cell carcinoma of the penis. *Am J Surg Pathol* 2001;25(5):673-8.
<http://www.ncbi.nlm.nih.gov/pubmed/11342782>
10. Guimarães GC, Lopes A, Campos RS, Zequi Sde C, Leal ML, Carvalho AL, da Cunha IW, Soares FA. Front pattern of invasion in squamous cell carcinoma of the penis: new prognostic factor for predicting risk of lymph node metastases. *Urology* 2006;68(1):148-53.
<http://www.ncbi.nlm.nih.gov/pubmed/16844455>
11. Busby JE, Pettaway CA. What's new in the management of penile cancer? *Curr Opin Urol* 2005;15(5):350-7.
<http://www.ncbi.nlm.nih.gov/pubmed/16093861>

7. DIAGNOSIS AND STAGING

The primary tumour and regional lymph nodes must be staged correctly to enable the most appropriate treatment.

7.1 Primary lesion

Physical examination of a patient with penile cancer includes:

- diameter of the penile lesion(s) or suspicious areas
- location of lesion(s) on the penis
- number of lesions
- morphology of lesion(s): papillary, nodular, ulcerous or flat
- relationship of lesion(s) to other structures, e.g. submucosa, tunica albuginea, urethra,
- corpus spongiosum and corpus cavernosum
- colour and boundaries of lesion(s)
- penis length.

Accurate histological diagnosis and staging of both the primary tumour and regional nodes are necessary in making treatment decisions (1). In a small series, physical examination alone was more reliable than imaging with ultrasound and/or MRI to judge infiltration into the corpora (2). Artificial erection with prostaglandin E1 (alprostadil) in combination with magnetic resonance imaging (MRI) was helpful in identifying the depth of tumour invasion of the corpora cavernosa and whether or not conservative surgery should be used (3, 4).

7.2 Regional lymph nodes

7.2.1 Lymphatic drainage of the penis

Primary lymphatic drainage of penile cancer occurs to the inguinal nodes. A recent imaging study (5) has

shown that all sentinel nodes are located in the superior and central inguinal zones with most found in the medial superior zone. No lymphatic drainage was observed from the penis to the inferior two regions of the groin and no direct drainage to the pelvic nodes was visualised. These findings confirm earlier studies (6-8).

7.2.2 *Non-palpable nodes*

A careful inguinal physical examination is necessary. In the absence of palpable abnormalities, an inguinal ultrasound (7.5 MHz) may reveal abnormal nodes and can be used as a guide for fine-needle aspiration biopsy (9, 10). A sentinel node biopsy (SNB) (8) is not recommended because of a high rate of false-negative results (25%, range 9-50%) (11). However, recent reports suggest that dynamic SNB (using isosulphan blue and/or technetium-99m (99mTc)-colloid sulphur) improved survival compared to a 'wait-and-see' policy (level of evidence: 3) and reduced toxicity compared to inguinal lymphadenectomy (LAD) (12, 13). A prospective study found dynamic SNB had 100% specificity and 95% sensitivity (14-18) (level of evidence: 2a). As analysis of dynamic SNB is operator-dependent (19) and relies on experience, the procedure is only available in a few centres. Because iliac lymph node metastases do not occur in the absence of inguinal metastases (19), an abdominal computed tomography (CT) scan is not necessary in patients with no inguinal node metastases.

A conventional CT or MRI scan cannot detect micrometastases (20). Large studies are required to confirm promising results reported with nanoparticle-enhanced MRI and positron emission tomography (PET) or CT imaging (21, 22).

7.2.3 *Risk factors*

The presence of lymph node metastases may be predicted from tumour characteristics other than T and G categories. Risk factors identified from retrospective studies include pathological subtype, perineural invasion, lymphovascular invasion, tumour depth or thickness, anatomical site, size and growth pattern, front of invasion, positive margins and urethral invasion (23). Several large series have identified lymphovascular invasion alone (24), lymphovascular invasion plus absent koilocytosis (25), lymphovascular invasion plus palpable inguinal nodes (26), high histological grade plus perineural invasion (27). The most important adverse pathological prognostic factors appear to be perineural invasion, vascular invasion and high histological grade (23). Nomograms can be used to evaluate the predictive power of clinical and pathological indicators (23, 26).

7.2.4 *Palpable nodes*

Palpable nodes should be described as follows:

- node consistency
- node location(s)
- diameter of node(s) or mass(es)
- unilateral or bilateral localisation
- number of nodes identified in each inguinal area
- mobile or fixed nodes or masses
- relationship (e.g. infiltration, perforation, etc) to other structures, such as the skin or Cooper ligament
- oedema on leg and/or scrotum.

Lymph node metastases in palpable nodes can be diagnosed using a percutaneous needle aspiration biopsy (cytology and/or histology puncture). At the time of diagnosis of penile cancer, as many as 50% of palpable inguinal nodes will be reactive rather than due to lymph node metastasis. In contrast, during follow-up, nearly 100% of enlarged nodes are metastatic (28-30) (level of evidence: 2a).

Thus, after allowing time for inflammatory reactions to subside, regional nodes should be evaluated within a few weeks after treatment of the primary tumour. Histological diagnosis can be done using fine-needle aspiration biopsy, tissue core biopsy or open biopsy, according to the preference of the pathologist (31, 32) (level of evidence: 2b). In the case of a negative biopsy and clinically suspicious nodes, a repeat biopsy or excisional biopsy should be performed.

Imaging techniques (CT, MRI) are widely used, but are only useful for staging in patients with proven lymph node metastases. So far no imaging modality can identify microscopic invasion. Imaging using PET (33) and the use of molecular biology are under investigation (34, 35).

7.3 **Distant metastases**

An assessment of distant metastases should be performed in patients with proven positive inguinal nodes (36) (level of evidence: 2b). Pelvic or abdominal CT scan should be used to identify pelvic (and retroperitoneal) adenopathies in patients with inguinal metastases. While this is not a very reliable diagnostic method, the detection of pelvic masses has a considerable impact on therapy and prognosis (39). Routine blood determination and chest X-rays are usually performed, despite the fact that lung metastasis

is exceptionally rare. The value of SCC antigen determination as a staging tool is unclear and therefore not recommended for routine use (34). Biological studies are investigational (37).

A diagnostic schedule is summarised in Table 7.

Table 7: Diagnostic schedule for penile cancer

Lesion level		Procedures		
		Mandatory	Advisable	Optional
Primary tumour		Physical examination	Cytology or histology	MRI Ultrasound
Regional disease	• Non-palpable nodes	Physical examination Ultrasound	Dynamic sentinel node biopsy*	
	• Palpable node	Ultra-sound (FNAC)* Cytology or histology		
Distant metastases		Pelvic CT, if positive inguinal nodes	Abdominal CT (chest X-rays)	Bone scan in symptomatic patients

FNAC=fine needle aspiration biopsy;MRI = magnetic resonance imaging; PGE1 = prostaglandin E1; CT = computed tomography.

*Dual technique: isosulphan blue with technetium-99m (99mTc) colloid sulphur (8, 19).

Regional lymph nodes are the regional disease.

7.4 Guidelines for the diagnosis of penile cancer

Primary tumour	GR
• Physical examination is mandatory, recording morphological and physical characteristics of the lesion	B
• Cytological or histological diagnosis is mandatory	B
Regional lymph node disease	
• Physical examination is mandatory	B
• If nodes are non-palpable, ultrasound-guided FNAB	B
• If FNAB is tumour-negative, dynamic SNB is indicated	B
• If nodes are palpable, it is mandatory to record nodal morphological and physical and physical characteristics and to perform FNAB for histological diagnosis	B
Distant metastasis (beside inguinal nodes)	
• A pelvic CT scan is indicated if metastatic inguinal nodes are present	B
• An abdominal CT scan and chest X-ray are advisable if pelvic CT scan is positive	B
• A bone scan is advisable in M1 symptomatic patients	C
• Biological laboratory determinations for penile cancer are investigational	None

GR = grade of recommendation, MRI = magnetic resonance imaging; PGE1 = prostaglandin E1;

FNAB = fine-needle aspiration biopsy; DSNB = sentinel node biopsy; CT = computed tomography.

7.5 REFERENCES

- Solsona E, Iborra I, Rubio J, Casanova JL, Ricós JV, Calabuig C. Prospective validation of the association of local tumor stage grade as a predictive factor for occult lymph node micrometastasis in patients with penile carcinoma and clinically negative inguinal lymph nodes. J Urol 2001;165(5): 1506-9.
<http://www.ncbi.nlm.nih.gov/pubmed/11342906>
- Horenblas S. The accuracy of ultrasound in squamous cell carcinoma. In: The Management of Penile Squamous Cell Carcinoma. A Retrospective and Prospective Study. Thesis. Amsterdam Zoetermeer: BV Export drukkerij, 1993, pp. 71-83.
- Kayes O, Minhas S, Allen C, Harc C, Freeman A, Ralph D. The role of magnetic resonance imaging in the local staging of penile cancer. Eur Urol 2007;51(5):1313-8.
<http://www.ncbi.nlm.nih.gov/pubmed/17113213>

4. Lont AP, Besnard AP, Gallee MP, van Tinteren H, Horenblas S. A comparison of physical examination and imaging in determining the extent of primary penile carcinoma. *BJU Int* 2003;91(6):493-5.
<http://www.ncbi.nlm.nih.gov/pubmed/12656901>
5. Leijte JA, Valdés Olmos RA, Nieweg OE, Horenblas S. Anatomical mapping of lymphatic drainage in penile carcinoma with SPECT-CT: implications for the extent of inguinal lymph node dissection. *Eur Urol* 2008;54(4):885-90.
<http://www.ncbi.nlm.nih.gov/pubmed/18502024>
6. Daseler EH, Anson BJ, Reimann AF. Radical excision of the inguinal and iliac lymph glands: a study based upon 450 anatomical dissections and upon supportive clinical observations. *Surg Gynecol Obstet* 1948;87(6):679-94.
<http://www.ncbi.nlm.nih.gov/pubmed/18120502>
7. Cabanas RM. An approach for the treatment of penile carcinoma. *Cancer* 1977;39(2):456-66.
<http://www.ncbi.nlm.nih.gov/pubmed/837331>
8. Catalona WJ. Modified inguinal lymphadenectomy for carcinoma of the penis with preservation of saphenous veins: technique and preliminary results. *J Urol* 1988;140(4):306-10.
<http://www.ncbi.nlm.nih.gov/pubmed/3418818>
9. Saisorn I, Lawrentschut N, Leewansangtong S, Bolton DM. Fine-needle aspiration cytology predicts inguinal lymph node metastases without antibiotic pretreatment in penile carcinoma. *BJU Int* 2006;97(6):1125-8.
<http://www.ncbi.nlm.nih.gov/pubmed/16686716>
10. Kroon BK, Horenblas S, Deurloo EE, Nieweg OE, Teertstra HJ. Ultrasonography-guided fine-needle aspiration cytology before sentinel node biopsy in patients with penile carcinoma. *BJU Int* 2005;95(4):517-21.
<http://www.ncbi.nlm.nih.gov/pubmed/15705071>
11. Pettaway CA, Pisters LL, Dinney CPN, Jularbal F, Swanson DA, von Eschenbach AC, Ayala A. Sentinel lymph node dissection for penile carcinoma: the MD Anderson Cancer Center Experience. *J Urol* 1995;154(6):1999-2003.
<http://www.ncbi.nlm.nih.gov/pubmed/7500444>
12. Horenblas S. Surgical management of carcinoma of the penis and scrotum. In: Petrovich Z, Baert L, Brady LW (eds). *Medical Radiology. Diagnostic Imaging and Radiation Oncology. Carcinoma of the Kidney and Testis, and Rare Urologic Malignancies*. Berlin: Springer-Verlag, 1999, pp. 341-54.
13. Pettaway CA, Jularbal FA, Babaian RJ, Dinney CPN, Pisters LL. Intraoperative lymphatic mapping to detect inguinal metastases in penile carcinoma: results of a pilot study. *J Urol* 1999;161:159 (abstr 612).
14. Akduman B, Fleshner NE, Ehrlich L, Klotz L. Early experience in intermediate-risk penile cancer with sentinel node identification using the gamma probe. *Urology* 2001;58(1):65-8.
<http://www.ncbi.nlm.nih.gov/pubmed/11445481>
15. Perdonà S, Gallo L, Claudio L, Marra L, Gentile M, Gallo A. [Role of crural inguinal lymphadenectomy and dynamic sentinel lymph node biopsy in lymph node staging in squamous-cell carcinoma of the penis. Our experience.] *Tumori* 2003;89(4 Suppl):276-9. [article in Italian]
<http://www.ncbi.nlm.nih.gov/pubmed/12903620>
16. Tanis PJ, Lont AP, Meinhardt W, Olmos RA, Nieweg OE, Horenblas S. Dynamic sentinel node biopsy for penile cancer: reliability of a staging technique. *J Urol* 2002;168(1):76-80.
<http://www.ncbi.nlm.nih.gov/pubmed/12050496>
17. Wawroschek F, Vogt H, Bachter D, Weckermann D, Hamm M, Harzmann R. First experience with gamma probe guided sentinel lymph node surgery in penile cancer. *Urol Res* 2000;28(4):246-9.
<http://www.ncbi.nlm.nih.gov/pubmed/11011963>
18. Lont AP, Horenblas S, Tanis PJ, Gallee MP, Van Tinteren H, Nieweg OE. Management of clinically node negative penile carcinoma: improved survival after the introduction of dynamic sentinel node biopsy. *J Urol* 2003;170(3):783-6.
<http://www.ncbi.nlm.nih.gov/pubmed/12913697>
19. Leijte JA, Kroon BK, Valdés Olmos RA, Nieweg OE, Horenblas S. Reliability and safety of current dynamic sentinel node biopsy for penile carcinoma. *Eur Urol* 2007;52(1):170-7.
20. Mueller-Lisse UG, Scher B, Scherr MK, Seitz M. Functional imaging in penile cancer: PET/computed tomography, MRI, and sentinel lymph node biopsy. *Curr Opin Urol* 2008;18(1):105-10.
<http://www.ncbi.nlm.nih.gov/pubmed/18090498>
21. Tabatabaei S, Harisinghani M, McDougal WS. Regional lymph node staging using lymphotropic nanoparticle enhanced magnetic resonance imaging with ferumoxtran-10 in patients with penile cancer. *J Urol* 2005;174:923-7; discussion 927.
<http://www.ncbi.nlm.nih.gov/pubmed/16093989>

22. Scher B, Seitz M, Albinger W, Reiser M, Schlenker B, Stief C, Mueller-Lisse U, Dresel S. Value of PET and PET/CT in the diagnostics of prostate and penile cancer. *Recent Results Cancer Res* 2008;170:159-79.
<http://www.ncbi.nlm.nih.gov/pubmed/18019625>
23. Cubilla AL. The role of pathologic prognostic factors in squamous cell carcinoma of the penis. *World J Urol* 2008 Sep 3. [Epub ahead of print]
<http://www.ncbi.nlm.nih.gov/pubmed/18766352>
24. Lopes A, Hidalgo GS, Kowalski LP, Torloni H, Rossi BM, Fonseca FP. Prognostic factors in carcinoma of the penis: multivariate analysis of 145 patients treated with amputation and lymphadenectomy *J Urol* 1996;156(5):1637-42.
<http://www.ncbi.nlm.nih.gov/pubmed/8863559>
25. Ornellas AA, Nóbrega BL, Wei Kin Chin E, Wisnescky A, da Silva PC, de Santos Schwindt AB. Prognostic factors in invasive squamous cell carcinoma of the penis: analysis of 196 patients treated at the Brazilian National Cancer Institute. *J Urol* 2008;180(4):1354-9.
<http://www.ncbi.nlm.nih.gov/pubmed/18707720>
26. Ficarra V, Zattoni F, Artibani W, Cunico SC, Fandella A, Martignoni G, Novara G, Galetti TP, Zattoni F; GUONE Penile Cancer Project Members. Nomogram predictive of pathological inguinal lymph nodes involvement in patients with squamous cell carcinoma of the penis. *J Urol* 2006;175(6):1700-5.
<http://www.ncbi.nlm.nih.gov/pubmed/16697813>
27. Velazquez EF, Ayala G, Liu H, Chaux A, Zanotti M, Torres J, Cho SI, Barreto JE, Soares F, Cubilla AL. Histologic grade and perineural invasion are more important than tumor thickness as predictor of nodal metastasis in penile squamous cell carcinoma invading 5 to 10 mm. *Am J Surg Pathol* 2008;32(7):974-9.
<http://www.ncbi.nlm.nih.gov/pubmed/18460979>
28. Horenblas S, Van Tinteren H, Delamarre JFM, Moonen LM, Lustig V, van Waardenburg EW. Squamous cell carcinoma of the penis. III. Treatment of regional lymph nodes. *J Urol* 1993;149(3):492-7.
<http://www.ncbi.nlm.nih.gov/pubmed/8437253>
29. Ornellas AA, Seixas AL, Marota A, Wisnescky A, Campos F, de Moraes JR. Surgical treatment of invasive squamous cell carcinoma of the penis: retrospective analysis of 350 cases. *J Urol* 1994;151(5):1244-9.
<http://www.ncbi.nlm.nih.gov/pubmed/7512656>
30. Pizzocaro G, Piva L, Nicolai N. Treatment of lymphatic metastasis of squamous cell carcinoma of the penis: experience at the National Tumor Institute of Milan. *Arch Ital Urol Androl* 1996;68(3):169-72.
<http://www.ncbi.nlm.nih.gov/pubmed/8767505>
31. Senthil Kumar MP, Ananthakrishnan N, Prema V. Predicting regional node metastasis in carcinoma of the penis: a comparison between fine-needle aspiration cytology, sentinel lymph node biopsy and medial inguinal lymph node biopsy. *Br J Urol* 1998;81(3):453-7.
<http://www.ncbi.nlm.nih.gov/pubmed/9523669>
32. Skoog L, Collins BT, Tani E, Ramos RR. Fine-needle aspiration cytology of penile tumors. *Acta Cytol* 1998;42(2):1336-40.
<http://www.ncbi.nlm.nih.gov/pubmed/9568135>
33. Ravizzini GC, Wagner M, Borges-Neto S. Positron emission tomography detection of metastatic penile squamous cell carcinoma. *J Urol* 2001;165(5):1633-4.
<http://www.ncbi.nlm.nih.gov/pubmed/11342941>
34. Laniado ME, Lowdell C, Mitchell H, Christmas TJ. Squamous cell carcinoma antigen: a role in the early identification of nodal metastases in men with squamous cell carcinoma of the penis. *BJU Int* 2003;92(3):248-5.
<http://www.ncbi.nlm.nih.gov/pubmed/12887477>
35. Lopez A, Bezena AL, Pinto CA, Serrano SV, de Mello CA, Villa LL. p53 as a new prognostic factor for lymph node metastasis in penile carcinoma: analysis of 82 patients treated with amputation and bilateral lymphadenectomy. *J Urol* 2002;168:81-6.
<http://www.ncbi.nlm.nih.gov/pubmed/12050497>
36. Zhu Y, Zhang SL, Ye DW, Yao XD, Jiang ZX, Zhou XY Predicting pelvic lymph node metastases in penile cancer patients: a comparison of computed tomography, Cloquet's node, and disease burden of inguinal lymph nodes. *Onkologie*. 2008;31:37-41.
37. Kayes O, Ahmed HU, Arya M, Minhas S. Molecular and genetic pathways in penile cancer. *Lancet Oncol* 2007;8(5):420-9.
<http://www.ncbi.nlm.nih.gov/pubmed/17466899>

38. Lont AP, Kroon BK, Gallee MP, van Tinteren H, Moonen LM, Horenblas S. Pelvic lymph node dissection for penile carcinoma: extent of inguinal lymph node involvement as an indicator for pelvic lymph node involvement and survival. *J Urol* 2007;177(3):947-52; discussion 952. <http://www.ncbi.nlm.nih.gov/pubmed/17296384>

8. TREATMENT

The primary tumour and regional lymph nodes are usually treated separately. It is important to avoid both overtreatment, which may lead to side-effects, and undertreatment, which may impair survival.

8.1 Primary tumour

8.1.1 Category Tis and Ta

Tis and Ta are superficial lesions that can be treated with several conservative techniques:

- topical 5-fluorouracil for Tis (1)
- imiquimod 5% cream, an immune response modifier with good cosmetic and functional results on flat lesions (2)
- laser therapy with carbon dioxide (CO₂) or neodymium:yttrium-aluminum-garnet (Nd:YAG) lasers (3, 4)
- photodynamic therapy (5)
- Mohs' micrographic surgery for Ta lesions (6, 7).

However, conservative treatment may not be suitable in cases of multifocal lesions, which are responsible for 15% of recurrences. Total treatment of the glans surface combined with concomitant circumcision is strongly recommended (4) to avoid multiple recurrences (grade of recommendation: A). Cure with secondary healing was obtained in 94% of 106 Tis patients treated with peniscopically controlled CO₂ laser excision. However, five patients had multiple recurrences and two required penile amputation (7). A recent paper on photodynamic therapy reported seven responses in 10 treated patients, but only four patients were recurrence-free after a mean follow-up of 35 months (5). Non-invasive verrucous carcinoma (Ta) needs a correct pre-operative diagnosis to avoid unnecessary extensive surgery (6). Furthermore, a recent report on Mohs' micrographic surgery demonstrated a significant local recurrence rate for Tis and verrucous carcinoma as well as invasive SCC (7). In conclusion, the best results are achieved with laser surgery (level of evidence: 2b; grade of recommendation: B).

8.1.2 Category T1G1

For lesions limited (level of evidence: 2a) to the foreskin and sulcus, wide local excision with circumcision may provide adequate treatment. Pathological assessment of the surgical margin is mandatory; a margin of 3-4 mm is sufficient (8). For T1 tumours of the glans, peniscopically controlled CO₂ laser excision alone cured 86% of 78 patients with histologically superficial infiltration (≤ 1 mm) of lamina propria (4). Another 40 patients had deeper infiltration (> 1 mm) with exophytic warty-like or plaque tumours. These patients received neo-adjuvant vinblastine, bleomycin and methotrexate (VBM) chemotherapy, with cure achieved in 33 (82%) patients. Of 18 (15%) relapsed patients, only eight (7%) needed penile amputation or radiotherapy (level of evidence: 2b). An alternative treatment of glans resurfacing (9) has shown promising results for preinvasive lesions (level of evidence: 2a).

8.1.3 Category T1G2-3

For patients who can guarantee they will attend for regular follow-up, a penis-preserving strategy is strongly recommended using wide local laser excision plus reconstructive surgery (10, 11) or glansctomy (12-14) (level of evidence: 2a). Treatment choice is influenced by tumour size and position on the glans and the side-effects of treatment. Meticulous follow-up is essential to enable immediate treatment of any local disease recurrence.

There is no difference in the local recurrence rate (15% or more) between external radiation therapy, interstitial brachytherapy (BRT) laser therapy and wide local excision. Glansctomy has the lowest recurrence rate of 2% (13). Pathological assessment of surgical margins is essential when using these procedures to reduce the rate of local recurrence (12, 13, 15) (level of evidence: 2b).

Generally, early diagnosis of local recurrence does not have a negative impact on survival (16) (level of evidence: 3).

8.1.4 *Category T2 (of the glans)*

A conservative strategy of total glansectomy, with or without resurfacing of the corporeal heads, is recommended (5, 14) (level of evidence: 2a). Partial glansectomy is an alternative in very carefully selected patients with tumours that include less than half of the glans and in whom close follow-up is possible (17) (level of evidence: 2b). Consider partial amputation in patients unfit for more conservative reconstructive surgery (13).

8.1.5 *Category T2 (of the corpora) and T3*

For tumours involving the tips of the corpora, partial amputation is standard treatment (18, 19) (level of evidence : 2a) . Reconstructive surgery with negative margins at frozen section analysis is an alternative in carefully selected patients (level of evidence: 2b). For large tumours involving more than the distal corpora, partial or radical amputation is standard (level of evidence: 2a).

Traditionally, partial amputation has required removal of 2-cm tumour-free margins. This is almost certainly more than is necessary. However, it is essential to achieve tumour-free margins with pathological confirmation. A surgical margin of 5-10 mm is safe (15, 20, 21) (level of evidence: 2b).

8.1.6 *Category T4*

Deeply infiltrating tumours involving adjacent structures are often associated with disseminated disease at presentation and a short life expectancy. Palliative care may be most appropriate. In selected cases, down-staging with chemotherapy may be considered prior to total penectomy. Alternatives include surgery with adjuvant external beam irradiation (level of evidence: 3).

8.1.7 *Local disease recurrence*

For local recurrence after conservative therapy, a second conservative procedure is strongly advised if there is no corpora cavernosa invasion (22) (level of evidence: 2b). However, if there is a large or deep infiltrating recurrence, partial or total amputation is strongly recommended. The incidence of local recurrence increases with penis preservation, but can be treated in most cases. Local recurrence after penile amputation has a poor prognosis (23). Combined chemotherapy and radiotherapy as for advanced head and neck cancer has not yet been tried.

8.1.8 *Technical aspects of surgery*

8.1.8.1 *Conservative surgery*

The most important factors in the choice of conservative management are simplicity, morbidity of the procedure and the surgeon's experience. Small areas of ablated/excised epithelium can heal without grafting. For a larger area, a skin graft provides a better cosmetic result in a shorter time (level of evidence: 3).

8.1.8.2 *Partial/total amputation*

Stenosis of the neo-meatus or perineal urethrostomy is seen in approximately 7-10% and can be prevented by a spatulated repair. Orchidectomy should not be performed routinely (level of evidence: 3).

8.1.9 *Radiotherapy*

External beam irradiation (ERT), brachytherapy (BRT) or both techniques together can be used. The ERT treatment is delivered with high-energy photons (4-6 MV) and uses CT scanning to define the target volume and to optimise dosage distribution. Different types of BRT can be used including external isotope mould, low-dose rate BRT, pulse-dose rate BRT or high-dose rate BRT.

Primary tumour radiotherapy is an alternative organ-preserving approach with excellent results in selected patients with T1-2 lesions less than 4 cm in diameter (level of evidence: 2a). There have been no prospective studies or randomised trials to evaluate the different modalities of radiation treatment.

A local control rate of about 60% has been reported using ERT, while BRT has achieved better control rates ranging from 70% to 90% (24-28). However, it is difficult to compare results using ERT and BRT because patients with large volume lesions (> 4 cm) are excluded from BRT. In addition, the different dosages used in different retrospective studies, even within the same institution, make it very difficult to compare results and side-effects.

Local failure rates after radiotherapy were higher than after adequate partial penectomy, but salvage surgery can restore local control (28, 29). The high doses of radiation needed to achieve local control can cause iatrogenic complications. Urethral stenosis (20-35%), glans necrosis (10-20%) and late fibrosis are the most serious types of tissue damage and can result in a non-functioning penis.

The penile preservation rate after radiotherapy is approximately 80%. The local control rate after BRT was recently reported as 90%, with an actuarial penile preservation rate of 87% at 5 years (29). Because of post-radiation changes (necrosis, scars, ulcers), it may be difficult to differentiate radiation sequelae from persistent or recurrent tumour and very close follow-up is recommended.

8.1.9.1 Recommendations for radiation therapy

Radiotherapy should be considered in two groups of patients with two different aims:

- Organ-preserving treatment: in men with T1-2 glans or coronal sulcus lesions (< 4 cm), who are compliant for close follow-up. Both ERT combined with a BRT boost, or BRT alone, may be used to deliver the prescribed dose (> 60 Gy).
- Palliative radiotherapy: in men with advanced or metastatic disease requiring palliative local treatment, the treatment of choice is ERT (40-50 Gy).

8.1.10 Guidelines for treatment strategies in primary tumour

Primary tumour		LE	GR
Category: Tis and Ta	Conservative therapy: CO ₂ or Nd:YAG lasers surgery are recommended	2a	B
• Multifocal lesions and HPV-16 infection	Total glans resurfacing and circumcision are strongly recommended to prevent multiple recurrences	2a	B
Category T1G1	T1G1 tumours are suitable for conservative surgery	2a	B
	For glans lesions, CO2 laser surgery or resurfacing are appropriate	2a	B
	For lesions of foreskin and sulcus, wide local excision with circumcision are appropriate with assessment of surgical margins	2a	B
	Deeper infiltration may need adjuvant chemotherapy	2a	B
Category T1G2-3	Penile-preserving treatment with wide local laser excision for complying patients with follow-up, or glansectomy are indicated	2a	B
	Assessment of surgical margins reduces rate of local recurrence	2b	B
	In these cases early diagnosis of local recurrence does not have an adverse impact on survival	2b	C
Category T2 (of glans)	Total glansectomy, with or without resurfacing of corporeal heads	2a	B
	Partial glansectomy is an alternative in very carefully selected patients with tumours less than half the glans and suitable for follow-up	2b	B
	Consider partial amputation in patients unfit for follow-up	2b	B
Category T2 (of the corpora) and T3	Moderate partial amputation for tumours involving only tips of the corpora	2a	B
	Partial or total amputation for larger tumours involving more than the distal corpora	2a	B
	Traditionally, partial amputation has required removal of 2-cm tumour-free margins. A surgical margin of 5-10 mm is safe with pathological confirmation	2b	B
Category T4	Deeply infiltrating tumours involving adjacent structures are often associated with disseminated disease at presentation. For patients in poor conditions with short life expectancy, palliative radiotherapy may be most appropriate	2a	C
	Some patients may be suitable for down-staging with chemotherapy prior to surgery. Alternatives include adjuvant external beam irradiation if surgery is not possible.	2a	B
Local disease recurrence after conservative therapy	Local recurrence is more likely with penis preservation but it is usually treatable	2a	B
	Second conservative procedure is strongly advised in absence of corpora cavernosa invasion	2a	B
	Partial or total amputation is strongly recommended for large or deep infiltrating recurrence	2a	B

	Local recurrence after penile amputation has a poor prognosis	2a	B
Main uses of radiotherapy	Organ-preserving treatment in selected patients with T1-2 glans or coronal sulcus lesions < 4 cm	2b	B
	Palliative in advanced or metastatic disease not responsive to chemotherapy	2b	B

8.2 Treatment of regional lymph nodes

Lymphadenectomy is the necessary surgical procedure for patients with inguinal lymph node metastases. Bilateral LAD is often followed by prolonged lymph leakage, which can result in leg and scrotal lymphoedema. Other surgical complications include skin flap necrosis, wound infection and haemorrhage from exposed femoral vessels.

The procedure requires careful skin flap management, meticulous lymph node dissection, prophylactic antibiotics, compressive stoking and early ambulation. These complications occur in 30-70% of patients. Lymphadenectomy should therefore preferably only be performed in a therapeutic setting, where removal of lymph node metastases is indisputable.

8.2.1 Management of patients with non-palpable inguinal nodes

8.2.1.1 Surveillance

In the past, patients with low-stage tumours and clinically unaffected inguinal nodes have often undergone surveillance strategies. The 2004 EAU guidelines 'strongly' recommended surveillance only in patients with superficial and well-differentiated tumours: Tis, TaG1-2, T1G1 and T1G2 with superficial growth and no vascular invasion (30). This approach was criticised following a study that found 82% of 100 consecutive patients had undergone unnecessary prophylactic LAD (31).

8.2.1.2 Prognostic factors

For a long time, urologists have been oriented to look at pathological risk factors for metastases and pT3-T4 and all G3 patients were unequivocal candidates for bilateral LAD. In an old series (32), nodal metastases were found in 100% of pT3-T4, in 82% of pT2 and 23% of pT1. In particular, 16.5% of metastases were found in pT1G1 and 60% in pT1G2-3. No metastases were found in Ta or Tis. In a very recent series (33), lymph node metastases were found in 12% of pT1G2, a category that has therefore been defined as 'intermediate risk'. A high histological grade and perineural invasion (21) or depth of invasion (34) are significant predictors of lymph node metastases. A nomogram (34) has identified palpable groin lymph nodes and vascular and/or lymphatic invasion as the most important predictors of lymph node metastases. A new nomogram with a larger international series of patients is ongoing (level of evidence: 2b).

8.2.1.3 Sentinel node biopsy (SNB)

Catalona's SNB (35) was a failure, but dynamic SNB appears very promising (36-39). The concept behind dynamic SNB assumes there is a stepwise and orderly progression of the primary node (the so-called sentinel node) to secondary lymph nodes. There may be more than one sentinel node. To identify the sentinel node(s), ^{99m}Tc-nanocolloid is injected around the penile tumour intradermally the day before surgery. The sentinel lymph node(s) are detected intra-operatively with a gamma X-ray detection probe and patent blue dye staining before being dissected and removed. If there is a positive histology, either on frozen section or definitive histology, a formal complete inguinal LAD is performed.

The technique has been extensively studied in a few specialised centres. The Netherlands Cancer Institute group initially reported a high rate of false-negative cases (36). However, following modification of the technique, they reported a markedly reduced false-negative rate of 4.8% (39). However, the technique has been criticised for its steep learning curve and the need for the surgeon to perform a minimal number of 20 procedures per year (40) (level of evidence: 2a).

8.2.2 Management of patients with palpable inguinal nodes

In patients with penile cancer, moderately enlarged palpable inguinal nodes, which are not fixed, may or may not signify metastatic disease. The rate of false-positive nodes has been reported as high as 50% (41), but recently much lower figures of 30% have been reported (42). Ultrasound with fine-needle aspiration biopsy provides an excellent, rapid and easy way to detect metastatic involvement. Of course this is only reliable in tumour-positive patients. In suspected cases with tumour-negative findings, fine-needle aspiration biopsy should be repeated. Dynamic SNB is not reliable in this group of patients and should not be used (43, 44).

Thus, in all tumour-positive patients, early LAD should be performed (45, 46); bilateral LAD is the standard

procedure. In contralateral non-palpable lymph nodes, surgical staging is recommended either by dynamic SNB or lymph node dissection (level of evidence: 2a).

8.2.2.1 Inguinal LAD

Significant morbidity has been described including wound infection, skin necrosis, wound dehiscence, lymphoedema and lymphocele (47, 48). Optimal skin handling and careful dissection of skin flaps are two of the most important factors in preventing complications. Skin rotation flaps and myocutaneous flaps should be used for primary wound closure in advanced cases (49) (level of evidence: 2b).

8.2.2.2 Modified inguinal LAD

This procedure is associated with less morbidity than standard LAD (50, 51). The rate of early complications was 6.8% (vs 41.4%) and the rate of late complications was 3.4% (vs 43.1%) for patients with modified LAD (51). However, reducing the field of dissection increased the possibility of false-negative cases (level of evidence: 2b).

The high false-negative rate described by Lopes et al. (52) should be considered in the light of recent findings concerning lymphatic drainage to the lateral superior Daseler's zone, which was not dissected in this approach (53, 54). Current knowledge of lymphatic drainage at the penis suggests that a contemporary modified LAD should dissect the central and both superior Daseler's zones of the inguinal region (grade of recommendation: B).

8.2.2.3 The role of pelvic LAD

There is no direct lymphatic drainage from penile cancer to the pelvic lymph nodes (54, 55). Thus, if there is no involvement of inguinal nodes, pelvic LAD is not warranted. In contrast, if the Cloquet node or other two inguinal nodes are involved on one side, a contemporary pelvic lymph node dissection must be performed through an upward muscle-splitting incision. Pathological predictors for the potential involvement of pelvic nodes in patients with involved inguinal nodes are the number of positive inguinal lymph nodes and extracapsular extent of metastatic disease (56) (level of evidence: 2a).

Pelvic LAD may be necessary as a secondary procedure. If bilateral dissection is indicated, it can be performed through a midline suprapubic extraperitoneal incision. The rate of positive pelvic nodes was 23% in cases with no more than two positive inguinal nodes and 56% for more than two positive inguinal nodes or if there is extracapsular extent in at least one inguinal node (57-59).

If very aggressive histological subtypes of penile cancer (i.e. basaloid) are present, or there is strong expression of p53, pelvic lymph node dissection should be considered if any inguinal node is involved (60) (grade of recommendation: B).

8.2.2.4 Video-endoscopic inguinal and pelvic LAD

This recently described technique is derived from laparoscopic surgery and has been evaluated only in small pilot studies (61, 62). It seems to carry a lower risk of skin complications, but a higher risk of lymphocele formation compared to an open approach; the reported overall complication rate was 23% (63). The reliability of this technique has not yet been assessed (level of evidence: 4).

Laparoscopic pelvic node dissection for bilateral pelvic lymph node removal, following positive bilateral inguinal LAD, is a rational approach, but only if the dissection can be performed with similar accuracy as open surgery.

8.2.3 Adjuvant chemotherapy

Adjuvant chemotherapy after resection of nodal metastases has been reported in a few series. There has been only one study group who reported consistent results with adjuvant post-operative chemotherapy in N+ patients (64, 65). Twenty-five consecutive patients with resected lymph node metastases from SCC of the penis received 12 weekly courses of adjuvant VBM (vincristine, bleomycin, methotrexate) chemotherapy between 1979 and 1990. All patients underwent ilioinguinal lymph node dissection and received adjuvant chemotherapy. Only four (16%) patients relapsed, and the other 21 had a long-term disease-free survival of 84%. These results compared favourably with a previous series of 31 patients, who underwent ilioinguinal lymph node dissection, alone or with adjuvant radiotherapy, between 1960 and 1978. The 5-year disease-free survival was only 37%. Among these 31 patients, only the involvement of a single, intranodal inguinal node metastasis was associated with good prognosis. In contrast, in the series of 25 patients treated with adjuvant chemotherapy (VBM), only bilateral and/or pelvic node involvement were significantly associated with poor prognosis, with 4 of 8 patients dying of penile cancer (level of evidence: 2a).

Since 1991, pN2-N3 patients have been treated with three courses of adjuvant cisplatin and 5-fluorouracil (PF) with only two relapses (6.7%) in the first 30 treated patients (65) (level of evidence: 2a).

8.2.4 *Management of patients with fixed or relapsed inguinal nodes*

Fourteen patients were treated with locally advanced or metastatic penile cancer with cisplatin, methotrexate and bleomycin (BMP) chemotherapy on days 2 to 5 (66). Toxicity was severe. Only three of the eight partial responders underwent surgery, while another two entered complete remission. In a confirmatory study by the Southwest Oncology Group (SWOG) (67), only six of 40 evaluable patients completed chemotherapy. Five complete and eight partial remissions were achieved, but at the cost of 11% treatment-related mortality and 17% life-threatening toxicity.

Another study (68) of BMP chemotherapy in 13 patients reported one death from treatment-related toxicity and no complete remissions (level of evidence: 2a).

A review was performed of 20 patients who had received neo-adjuvant chemotherapy, including BMP, for unresectable lymph node metastases during the period 1972 to 2005 (69). Twelve of 19 evaluable patients showed an objective tumour response. Five different chemotherapeutic regimens were used. Nine responders underwent subsequent surgery, of whom eight became long-term survivors without evidence of recurrent disease. Chemotherapy-related toxicity was fatal in three out of 10 patients treated with BMP (level of evidence: 2b).

At the MD Anderson Cancer Center (Houston, TX, USA) (70), 10 patients were treated with surgical consolidation following a stable, partial, or complete response to four to five courses of the following chemotherapeutic regimens: paclitaxel, ifosfamide and cisplatin (ITP) in five patients, paclitaxel and carboplatin (PC) in two patients, and BMP in three patients. Three of the five patients treated with ITP had a pathologically documented complete remission and two of them are long-term survivors. The two patients treated with PC became disease-free with post-chemotherapy surgery. All three patients treated with BMP suffered severe toxicity and died of the disease.

Systematic use of post-chemotherapy surgery in responsive patients was of main importance in the latter two studies (69, 70) (level of evidence: 2a).

In addition, a preliminary report (71) on taxol combined with PF (TPF) chemotherapy in six consecutive patients with unresectable or relapsed inguinopelvic lymph node metastases from SCC of the penis suggests that TPF could have improved activity compared to PF alone in this clinical situation (65), as has been demonstrated in SCC of the head and neck in three randomised trials (72-74).

In conclusion, adjuvant chemotherapy is strongly recommended in pN2-3 patients, and neo-adjuvant chemotherapy with taxanes seems to be active in unresectable or recurrent lymph node metastases (level of evidence: 2a, grade of recommendation: B).

8.2.5 *The role of radiotherapy*

Prophylactic radiotherapy in clinical N0 patients is not recommended for the following reasons:

- radiotherapy fails to prevent the development of metastatic lymph nodes (75)
- complications of radiotherapy (76)
- follow-up is more difficult due to fibrotic changes.

Pre-operative radiotherapy in patients with fixed nodes can make the nodes operable, but it is not known whether node fixation is an inflammatory reaction or malignant growth (75, 76). Adjuvant radiotherapy may improve loco-regional control in patients with extensive metastases and/or extranodal spread. However, severe side-effects include oedema and pain (75).

8.2.6 Guidelines for treatment strategies for nodal metastases

Regional lymph nodes	Management of regional lymph nodes is fundamental in the treatment of penile cancer	LE	GR
No palpable inguinal nodes	Tis, Ta G1, T1G1: surveillance	2a	B
	> T1G2: DSNB (NB: Inguinal LAD if histology is positive.)	2a	B
	If DSNB not available: risk factors / nomogram decision-making	3	C
Palpable inguinal nodes	Ultrasound-guided FNAB (NB: DSNB is unsuitable for palpable nodes) Negative biopsy: surveillance (repeat biopsy) Positive biopsy: inguinal LAD on positive side (NB: Modified LAD must include the central zone and both superior Daseler's zones.)	2a	B
Pelvic nodes	Pelvic LAD if there are: extranodal metastases; Cloquet node involved; > 2 inguinal node metastases	2a	B
	Unilateral pelvic LAD if unilateral lymph node metastases with prolonged inguinal incision	2b	B
	Bilateral pelvic LAD if bilateral inguinal metastases	2a	B
Adjuvant chemotherapy	In patients with > 1 intranodal metastasis (pN2 pN3) after radical LAD, survival is improved by adjuvant chemotherapy (2 or 3 courses of cisplatin, fluorouracil (PF) chemotherapy)	2b	B
Patients with fixed or relapsed inguinal nodes	Neo-adjuvant chemotherapy is strongly recommended in patients with unresectable or recurrent lymph node metastases. Taxanes seems to improve the efficacy of standard PF chemotherapy	2a	B
Radiotherapy	Curative radiotherapy may be used for primary tumours of the glans penis and sulcus < 4 cm or for palliation	2a	B
	Prophylactic radiotherapy in clinical N0 patients is not indicated	2a	B

LE = level of evidence; GR = grade of recommendation; LAD = lymphadenectomy; FNAB = fine-needle aspiration biopsy; DSNB = sentinel node biopsy.

8.3 REFERENCES

- Goette DK, Carson TE. Erythroplasia of Queyrat: treatment with topical 5-fluorouracil. *Cancer* 1976;38(4):1498-502.
<http://www.ncbi.nlm.nih.gov/pubmed/991073>
- Taliaferro SJ, Cohen GF. Bowen's disease of the penis treated with topical imiquimod 5% cream. *J Drugs Dermatol* 2008;7(5):483-5.
<http://www.ncbi.nlm.nih.gov/pubmed/18505144>
- van Bezooijen BP, Horenblas S, Meinhardt W, Newling DW. Laser therapy for carcinoma in situ of the penis. *J Urol* 2001;166(5):1670-1.
<http://www.ncbi.nlm.nih.gov/pubmed/11586199>
- Bandieramonte G, Colecchia M, Mariani L, Lo Vullo S, Pizzocaro G, Piva L, Nicolai N, Salvioni R, Lezzi V, Stefanon B, De Palo G. Penoscopically controlled CO2 laser excision for conservative treatment of in situ and T1 penile carcinoma: report on 224 patients. *Eur Urol* 2008;54(4):875-84.
<http://www.ncbi.nlm.nih.gov/pubmed/18243513>
- Paoli J, Ternesten Bratel A, Löwhagen GB, Stenquist B, Forslund O, Wennberg AM. Penile intraepithelial neoplasia: results of photodynamic therapy. *Acta Derm Venereol* 2006;86(5):418-21.
<http://www.ncbi.nlm.nih.gov/pubmed/16955186>
- Hatzichristou DG, Apostolidis A, Tzortzis V, Hatzimouratidis K, Ioannides E, Yannakoyorgos K. Glansectomy: an alternative surgical treatment for Buschke-Löwenstein tumors of the penis. *Urology* 2001;57(5):966-9.
<http://www.ncbi.nlm.nih.gov/pubmed/11337304>
- Shindel AW, Mann MW, Lev RY, Sengelmann R, Petersen J, Hruza GJ, Brandes SB. Mohs micrographic surgery for penile cancer: management and long-term followup. *J Urol* 2007;178(5):1980-5.
<http://www.ncbi.nlm.nih.gov/pubmed/17869306>

8. Penile Cancer Treatment (PDQ®) Health Professional Version. National Cancer Institute, US National Institutes of Health, 2008, pp. 6-7.
<http://www.cancer.gov/cancertopics/pdq/treatment/penile/healthprofessional/allpages/print>
9. Hadway P, Corbishley CM, Watkin NA. Total glans resurfacing for premalignant lesions of the penis: initial outcome data. *BJU Int* 2006;98(3):532-6.
<http://www.ncbi.nlm.nih.gov/pubmed/16925748>
10. Frimberger D, Hungerhuber E, Zaak D, Waidelich R, Hofstetter A, Schneede P. Penile carcinoma. Is Nd:YAG laser therapy radical enough?. *J Urol* 2002;168(6):2418-21.
<http://www.ncbi.nlm.nih.gov/pubmed/12441930>
11. Windahl T, Andersson SO. Combined laser treatment for penile carcinoma: results after long-term follow up. *J Urol* 2003;169(6):2118-21.
<http://www.ncbi.nlm.nih.gov/pubmed/12771731>
12. Bissada NK, Yakout HH, Fahmy WE, Gayed MS, Touijer AK, Greene GF, Hanash KA. Multiinstitutional long-term experience with conservative surgery for invasive penile carcinoma. *J Urol* 2003;169(2):500-2.
<http://www.ncbi.nlm.nih.gov/pubmed/12544296>
13. Smith Y, Hadway P, Biedrzycki, Perry MJA, Corbishley C, Watkin NA. Reconstructive surgery for invasive squamous cell carcinoma of the glans penis. *Eur Urol* 2007;52(4):1179-85.
<http://www.ncbi.nlm.nih.gov/pubmed/17349734>
14. Davis JW, Schellhammer PF, Schlossberg SM. Conservative surgical therapy for penile and urethral carcinoma. *Urology* 1999;53(2):386-92.
<http://www.ncbi.nlm.nih.gov/pubmed/9933060>
15. Algaba F, Arce Y, López-Beltán A, Montironi R, Mikuz G, Bono AV. Intraoperative frozen section diagnosis in Urological Oncology. *Eur Urol* 2005;47(2):129-36.
<http://www.ncbi.nlm.nih.gov/pubmed/15661406>
16. Gotsadze D, Matveev B, Zak B, Mamaladze V. Is conservative organ-sparing treatment of penile carcinoma justified? *Eur Urol* 2000;38(3):306-12.
<http://www.ncbi.nlm.nih.gov/pubmed/10940705>
17. Minhas S, Kayes O, Hegarty P, Kumar P, Freeman A, Ralph D. What surgical resection margins are required to achieve oncological control in men with primary penile cancer? *BJU Int* 2005;96(7):1040-3.
<http://www.ncbi.nlm.nih.gov/pubmed/16225525>
18. Ornellas AA, Seixas ALC, Marota A, Wisnesky A, Campos F, de Moraes JR. Surgical treatment of invasive squamous cell carcinoma of the penis: retrospective analysis of 350 cases. *J Urol* 1994;151(5):1244-9.
<http://www.ncbi.nlm.nih.gov/pubmed/7512656>
19. Lont AP, Gallee MP, Meinhardt W, van Tinteren H, Horenblas S. Penis conserving treatment for T1 and T2 penile carcinoma: clinical implications of a local recurrence. *J Urol* 2006;176(2):575-80;discussion 580.
<http://www.ncbi.nlm.nih.gov/pubmed/16813892>
20. Velázquez EF, Soskin A, Bock A, Cudas R, Barreto JE, Cubilla AL. Positive resection margins in partial penectomies. Sites of involvement and proposal of local routes of spread of penile squamous cell carcinoma. *Am J Surg Pathol* 2004;28(3):384-9.
<http://www.ncbi.nlm.nih.gov/pubmed/15104302>
21. Horenblas S, Van Tinteren H, Delemarre JFM, Boon TA, Moonen LMF, Lustig V. Squamous cell carcinoma of the penis. II. Treatment of the primary tumor. *J Urol* 1992;147(6):1533-8.
<http://www.ncbi.nlm.nih.gov/pubmed/1593683>
22. Koch MO, Smith JA Jr. Local recurrence of squamous cell carcinoma of the penis. *Urol Clin North Am* 1994;21(4):739-43.
<http://www.ncbi.nlm.nih.gov/pubmed/7974902>
23. Gotsadze D, Matveev B, Zak B, Mamaladze V. Is conservative organ-sparing treatment of penile carcinoma justified? *Eur Urol* 2000;38(3):306-12.
<http://www.ncbi.nlm.nih.gov/pubmed/10940705>
24. Sarin R, Norman AR, Steel GG. Treatment results and prognostic factors in 101 men treated for squamous carcinoma of the penis. *Int J Radiat Oncol Biol Phys* 1997;38(4):713-22.
<http://www.ncbi.nlm.nih.gov/pubmed/9240637>
25. Kiltie AE, Elwell C, Close A, Ash DV. Iridium-192 implantation for node-negative carcinoma of the penis: The Cookridge Hospital Experience. *Clin Oncol (R Coll Radiol)* 2000;12(1):25-31.
<http://www.ncbi.nlm.nih.gov/pubmed/10749016>

26. Azrif M, Logue GP, Swindell R, Cowan RA, Wylie JP, Livsey JE. External-beam radiotherapy in T1-2 N0 penile carcinoma. *Clin Oncol (R Coll Radiol)* 2006;18(4):320-5.
<http://www.ncbi.nlm.nih.gov/pubmed/16703750>
27. Rozan R, Albuissou E, Giraud B, Donnarieix D, Delannes M, Pigneux J, Hoffstetter S, Gerbaulet A, Chinet-Charrot P, Goupil A, et al. Interstitial brachytherapy for penile carcinoma: a multicentric survey (259 patients). *Radiother Oncol* 1995;36(2):83-93.
<http://www.ncbi.nlm.nih.gov/pubmed/7501816>
28. Zouhair A, Coucke PA, Jeanneret W, Douglas P, Do HP, Jichilinski P, Mirimanoff RO, Ozsahin M. Radiation therapy alone or combined surgery and radiation therapy in squamous-cell carcinoma of the penis? *Eur J Cancer* 2001;37(2):198-203.
<http://www.ncbi.nlm.nih.gov/pubmed/11166146>
29. Crook JM, Grimard L, Esche B, Pond G. Penile brachytherapy: results for 60 patients. *Brachytherapy* 2007;6:82.
30. Solsona E, Algaba F, Horenblas S, Pizzocaro G, Windahl T. EAU Guidelines on Penile Cancer. *Eur Urol* 2004;46(1):1-8.
<http://www.ncbi.nlm.nih.gov/pubmed/15183542>
31. Hegarty PK, Kayes O, Freeman A, Christopher N, Ralph DJ, Minhas S. A prospective study of 100 cases of penile cancer managed according to European Association of Urology guidelines. *BJU Int* 2006;98(3):526-31.
<http://www.ncbi.nlm.nih.gov/pubmed/16925747>
32. Pizzocaro G, Piva L, Nicolai N. [Treatment of lymphatic metastases for squamous cell carcinoma of the penis: experience at the National Tumor Institute of Milan.] *Arch Ital Urol Androl* 1996;68(3):169-72. [article in Italian]
<http://www.ncbi.nlm.nih.gov/pubmed/8767505>
33. Hughes B, Leijte J, Shabbir M, et al. Lymphnode metastasis in intermediate risk penile squamous cell cancer. A multicentre experience. *Eur Urol Suppl* 2008;7(3):110 (abstract 160).
34. Ficarra V, Zattoni F, Artibani W, Cunico SC, Fandella A, Martignoni G, Novara G, Galetti TP, Zattoni F; GUONE Penile Cancer Project Members. Nomogram predictive of pathological inguinal lymph nodes involvement in patients with squamous cell carcinoma of the penis. *J Urol* 2006;175(6):1700-5.
<http://www.ncbi.nlm.nih.gov/pubmed/16697813>
35. Catalona WJ. Modified inguinal lymphadenectomy for carcinoma of the penis with preservation of saphenous vein: technique and preliminary results. *J Urol* 1988;140(2):306-10.
<http://www.ncbi.nlm.nih.gov/pubmed/3398125>
36. Horenblas S, Jansen L, Meinhardt W, Hoefnagel CA, de Jong D, Nieweg OE. Detection of occult metastasis in squamous cell carcinoma of the penis using a dynamic sentinel node procedure. *J Urol* 2000;163(1):100-4.
<http://www.ncbi.nlm.nih.gov/pubmed/10604324>
37. Perdonà S, Autorino R, Gallo L, Di Lorenzo G, Cascini GL, Lastoria F, Marra L, De Sio M, Damiano R, Gallo A. Role of dynamic sentinel node biopsy in penile cancer: our experience. *J Surg Oncol* 2006;93(3):181-5.
<http://www.ncbi.nlm.nih.gov/pubmed/16482606>
38. Kroon BK, Horenblas S, Estourgie SH, Lont AP, Valdes Olmos RA, Nieweg OE. How to avoid false-negative dynamic sentinel node procedures in penile carcinoma. *J Urol* 2004;171(6 Pt 1):2191-4.
<http://www.ncbi.nlm.nih.gov/pubmed/15126783>
39. Leijte JAP, Kroon BK, Valdes Olmos RD, Nieweg OE, Horenblas S. Reliability and safety of current dynamic sentinel node biopsy for penile carcinoma. *Eur Urol* 2007;52(1):170-7.
<http://www.ncbi.nlm.nih.gov/pubmed/17316967>
40. Ficarra V, Galfano A. Should the dynamic sentinel node biopsy (DSNB) be considered the gold standard in the evaluation of lymph node status in patients with penile carcinoma?. *Eur Urol* 2007;52(1):17-19; discussion 20-1. Epub 2007.
<http://www.ncbi.nlm.nih.gov/pubmed/17376585>
41. Persky L, deKernion J. Carcinoma of the penis. *CA Cancer J Clin* 1986;36(5):258-73.
<http://www.ncbi.nlm.nih.gov/pubmed/3093013>
42. Velasquez EF, Ayala C, Liu H, Chau A, Zanotti M, Torres J, Cho SI, Barreto JE, Soares F, Cubilla AL. Histologic grade and perineal invasion are more important than tumor thickness as predictor of nodal metastases in penile squamous cell carcinoma invading 5 to 10 mm. *Am J Surg Pathol* 2008;32(7):974-9.
<http://www.ncbi.nlm.nih.gov/pubmed/18460979>

43. Horenblas S. Lymphadenectomy for squamous cell carcinoma of the penis. Part 1: diagnosis of lymph node metastasis. *BJU Int* 2001;88:467-72.
<http://www.ncbi.nlm.nih.gov/pubmed/11589659>
44. Preis E, Jakse G. [The significance of inguinal lymphadenectomy in carcinoma of the penis.] *Urologe A* 2006;45(Suppl 04):176-80. [article in German]
<http://www.ncbi.nlm.nih.gov/pubmed/16933120>
45. Kroon BK, Horenblas S, Estourgie SH, Lont AP, Valdes Olmos RA, Nieweg OE. How to avoid falsenegative dynamic sentinel node procedures in penile carcinoma. *J Urol* 2004;171(6 Pt 1):2191-4.
<http://www.ncbi.nlm.nih.gov/pubmed/15126783>
46. Hungerhuber E, Schlenker B, Frimberger D, Linke R, Karl A, Stief CG, Schneede P. Lymphoscintigraphy in penile cancer: limited value of sentinel node biopsy in patients with clinically suspicious lymph nodes. *World J Urol* 2006;24(3):319-24.
<http://www.ncbi.nlm.nih.gov/pubmed/16688459>
47. Kroon BK, Horenblas S, Lont AP, Tanis PJ, Gallee MP, Nieweg OE. Patients with penile carcinoma benefit from immediate resection of clinically occult lymph node metastases. *J Urol* 2005;173(3):816-9
<http://www.ncbi.nlm.nih.gov/pubmed/15711276>
48. Wein AJ, Kavoussi LR, Novick AC, Partin AW, Peters CA (eds). *Campbell-Walsh Urology*. 9th edn. Philadelphia, PA: Saunders Elsevier, 2007.
49. Horenblas S. Lymphadenectomy for squamous cell carcinoma of the penis. Part 2: the role and technique of lymph node dissection. *BJU Int* 2001;88(5):473-83.
<http://www.ncbi.nlm.nih.gov/pubmed/11589660>
50. Bevan-Thomas R, Slaton JW, Pettaway CA. Contemporary morbidity from lymphadenectomy for penile squamous cell carcinoma: the MD Anderson Cancer Center Experience. *J Urol* 2002;167(4):1638-42.
<http://www.ncbi.nlm.nih.gov/pubmed/11912379>
51. Bouchot O, Rigaud J, Maillet F, Hetet JF, Karam G. Morbidity of inguinal lymphadenectomy for invasive penile carcinoma. *Eur Urol* 2004;45(6):761-5; discussion 765-6.
<http://www.ncbi.nlm.nih.gov/pubmed/15149749>
52. Lopes A, Rossi BM, Fonseca FP, Morini S. Unreliability of modified inguinal lymphadenectomy for clinical staging of penile carcinoma. *Cancer* 1996;77(10):2099-102.
<http://www.ncbi.nlm.nih.gov/pubmed/8640676>
53. Daseler EH, Anson BJ, Reimann AF. Radical excision of inguinal and iliac lymph glands: a study based upon 450 anatomical dissections and upon supportive clinical observations. *Surg Gynecol Obstet* 1948;87(6):679-94.
<http://www.ncbi.nlm.nih.gov/pubmed/18120502>
54. Leijte JAP, Valdés Olmos RA, Nieweg OE, Horenblas S. Anatomical mapping of lymphatic drainage in penile cancer with SPECT-TC: implications for the extent of inguinal lymph node dissection. *Eur Urol* 2008;54(4):885-90.
<http://www.ncbi.nlm.nih.gov/pubmed/18502024>
55. Cabanas RM. An approach for treatment of penile carcinoma. *Cancer* 1977;39(2):456-66.
<http://www.ncbi.nlm.nih.gov/pubmed/837331>
56. Lont AP, Kroon BK, Gallee MP, van Tinteren H, Moonen LM, Horenblas S. Pelvic lymph node dissection for penile carcinoma: extent of inguinal lymph node involvement as an indicator for pelvic lymph node involvement and survival. *J Urol* 2007;177(3):947-52; discussion 952.
<http://www.ncbi.nlm.nih.gov/pubmed/17296384>
57. Ornellas AA, Seixas AL, Marota A, Wisnescky A, Campos F, de Moraes JR. Surgical treatment of invasive squamous cell carcinoma of the penis: retrospective analysis of 350 cases. *J Urol* 1994;151(5):1244-9.
<http://www.ncbi.nlm.nih.gov/pubmed/7512656>
58. Culkun DJ, Beer TM. Advanced penile carcinoma. *J Urol* 2003;170(2 Pt 1):359-65.
<http://www.ncbi.nlm.nih.gov/pubmed/12853775>
59. Lopes A, Bezerra AL, Serrano SV, Hidalgo GS. Iliac nodal metastases from carcinoma of the penis treated surgically. *BJU Int* 2000;86(6):690-3.
<http://www.ncbi.nlm.nih.gov/pubmed/11069378>
60. Zhu Y, Zhang SL, Ye DW, Yao XD, Jiang ZX, Zhou XY. Predicting pelvic lymph node metastases in penile cancer patients: a comparison of computed tomography, Cloquet's node, and disease burden of inguinal lymph nodes. *Onkologie* 2008;31(1-2):37-41.
<http://www.ncbi.nlm.nih.gov/pubmed/18268397>

61. Tobias-Machado M, Tavares A, Ornellas AA, Molina WR Jr, Juliano RV, Wroclawski ER. Video endoscopic inguinal lymphadenectomy: a new minimally invasive procedure for radical management of inguinal nodes in patients with penile squamous cell carcinoma. *J Urol* 2007;177(3):953-7;discussion 958.
<http://www.ncbi.nlm.nih.gov/pubmed/17296386>
62. Tobias-Machado M, Tavares A, Silva MN, Molina Jr WR, Forseto PH, Juliano RV, Wroclawski ER. Can video endoscopic inguinal lymphadenectomy achieve a lower morbidity than open lymph node dissection in penile cancer patients?. *J Endourol* 2008;22(8):1687-91.
<http://www.ncbi.nlm.nih.gov/pubmed/18657031>
63. Sotelo R, Sanchez-Salas R, Carmona O, Garcia A, Mariano M, Neiva G, Trujillo G, Novoa J, Cornejo F, Finelli A. Endoscopic lymphadenectomy for penile carcinoma. *J Endourol* 2007;21(4):364-7;discussion 367.
<http://www.ncbi.nlm.nih.gov/pubmed/17451323>
64. Pizzocaro G, Piva L. Adjuvant and neoadjuvant vincristine, bleomycin, and methotrexate for inguinal metastases from squamous cell carcinoma of the penis. *Acta Oncol* 1988;27(6b):823-4.
<http://www.ncbi.nlm.nih.gov/pubmed/2466471>
65. Pizzocaro G, Piva L, Bandieramonte G, Tana S. Up-to-date management of carcinoma of the penis. *Eur Urol* 1997;32(1):5-15.
<http://www.ncbi.nlm.nih.gov/pubmed/9266225>
66. Dexeus F, Logothetis C, Sella A, Amato R, Kilbourn R, Fitz K, Striegel A. Combination chemotherapy with methotrexate, bleomycin and cisplatin for advanced squamous cell carcinoma of the male genital tract. *J Urol* 1991;146(5):1284-7.
<http://www.ncbi.nlm.nih.gov/pubmed/1719241>
67. Haas G, Blumenstein B, Gagliano R, Russell CA, Rivkin SE, Culkin DJ, Wolf M, Crawford ED. Cisplatin, methotrexate and bleomycin for the treatment of carcinoma of the penis: a Southwest Oncology Group study. *J Urol* 1999;161(6):1823-5.
<http://www.ncbi.nlm.nih.gov/pubmed/10332445>
68. Hakenberg OW, Nippgen JB, Froehner M, Zastrow S, Wirth MP. Cisplatin, methotrexate and bleomycin for treating advanced penile carcinoma. *BJU Int* 2006;98(6):1225-7.
<http://www.ncbi.nlm.nih.gov/pubmed/17125480>
69. Lijte JA, Kerst JM, Bais E, Antonini N, Horenblas S. Neoadjuvant chemotherapy in advanced penile carcinoma. *Eur Urol* 2007;52(2):488-94.
<http://www.ncbi.nlm.nih.gov/pubmed/17316964>
70. Barmejo C, Busby JK, Spiess PE, Heller L, Pagliaro LC, Pettaway CA. Neoadjuvant chemotherapy followed by aggressive surgical consolidation for metastatic penile squamous cell carcinoma. *J Urol* 2007;177(4):1335-8.
<http://www.ncbi.nlm.nih.gov/pubmed/17382727>
71. Pizzocaro G, Nicolai N, Milani A. Taxanes in combination with cisplatin and fluorouracil for advanced penile cancer: preliminary results. *Eur Urol* 2008 Jul 14. [Epub ahead of print]
<http://www.ncbi.nlm.nih.gov/pubmed/18649992>
72. Hitt R, López-Pousa A, Martínez-Trufero J et al. Phase III study comparing cisplatin plus fluorouracil to paclitaxel, cisplatin, and fluorouracil induction chemotherapy followed by chemoradiotherapy in locally advanced head and neck cancer. *J Clin Oncol* 2005;23(34):8636-45.
<http://jco.ascopubs.org/cgi/content/full/23/34/8636>
73. Posner MR, Hershock DM, Blajman CR et al. Cisplatin and fluorouracil alone or with docetaxel in head and neck cancer. *N Engl J Med* 2007;357(17):1705-15.
<http://content.nejm.org/cgi/content/abstract/357/17/1705>
74. Vermorken JB, Remenar E, van Herpen C, et al. Cisplatin, fluorouracil, and docetaxel in unresectable head and neck cancer. *N Engl J Med* 2007;357(17):1695-704.
<http://content.nejm.org/cgi/content/abstract/357/17/1695>
75. Kulkarni JN, Kamat MR. Prophylactic bilateral groin node dissection versus prophylactic radiotherapy and surveillance in patients with N0 and N1-2A carcinoma of the penis. *Eur Urol* 1994;26(2):123-8.
<http://www.ncbi.nlm.nih.gov/pubmed/7957466>
76. Ravi R, Chaturvedi HK, Sastry DV. Role of radiation therapy in the treatment of carcinoma of the penis. *Br J Urol* 1994;74(5):646-51.
<http://www.ncbi.nlm.nih.gov/pubmed/7530129>

9. FOLLOW-UP

Follow-up in penile carcinoma is important for several reasons:

- It enables early detection of recurrence, which is important because most local and/or loco-regional recurrences are potentially curable
- It is the only way to assess treatment and anticipate early and late complications
- It is also important for patient (and physician) education.

A rational follow-up scheme requires an understanding of the patterns of recurrence. Preferably, follow-up should be introduced within the framework of a randomised study. Based on a retrospective study, a follow-up schedule for penis cancer has been published (1).

9.1 How to follow-up

The aim of follow-up is to detect local and/or regional recurrences because they may be cured. In contrast, metastases at distant sites are always fatal (2). Risk stratification for recurrence is also helpful. Traditional follow-up methods have been inspection and physical evaluation. Modern ultrasound imaging is a useful adjunct, with promising results from new imaging modalities, such as PET scan and laser-directed MRI (3).

9.2 When to follow-up

The follow-up interval and strategies for patients with penile cancer are directed by the initial treatment of the primary lesion and regional lymph nodes. In the above-mentioned multicentre study (1), during the first 2 years of follow-up, the following occurred:

- 74.3% of all recurrences
- 66.4% of local recurrences
- 86.1% of regional recurrences
- 100% of distant recurrences.

Of all recurrences, 92.2% occurred within the first 5 years (1). All recurrences after 5 years were local recurrences or new primaries. Thus, an intensive programme of follow-up during the first 2 years is rational with less intensive follow-up needed thereafter. In well-educated and motivated patients, follow-up can stop after 5 years, although they must continue to carry out regular self-examination.

9.3 Primary tumour

Local recurrence has been reported in up to 30% of patients treated with penile-preserving surgery, during the first 2 years following treatment. Local recurrence is more likely with all types of local therapy, i.e. local resection, laser therapy, BRT, Mohs' procedure, and associated therapies (1, 4). However, in contrast to regional recurrences, local recurrences do not impact on survival (1, 4).

Local recurrences are easily detected by the patient, his partner or doctor. Patient education is an important part of follow-up and the patient should be urged to visit a specialist if any changes are seen. Despite the fact that late local recurrences are well documented, it is reasonable to stop follow-up after 5 years, provided the patient will report local changes immediately (5). This is possible because life-threatening regional and distant metastases no longer occur, while recurrences that are local only are not life-threatening. The emphasis should be placed on patient self-examination.

In patients who are unlikely to self-examine, long-term follow-up may be necessary.

Following penile-preserving treatment, a follow-up visit every 3 months is advised in the first 2 years. We then advise a follow-up visit every half year, provided that the patient and partner have been well instructed to examine the penis regularly and to return if any abnormality is observed. It is important to stress that the patient must continue to carry out regular self-examination even after 5 years' follow-up.

After amputation, a less frequent time interval of every 6 months is advised. The risk of local recurrence is not more than 5% (1, 4).

9.4 Regional recurrences

Stringent follow-up is advised for the 2 years following surgery. This is because most regional recurrences occur within 2 years, whether a 'wait-and-see' policy has been followed or the patient has undergone SNB or inguinal LAD.

Previous follow-up recommendations have relied heavily on physical examination of the inguinal regions. However, experience with 'wait and see' and dynamic SNB have shown that, despite intensive follow-up, regional recurrences have shown up unexpectedly (6). Ultrasound and immediate fine-needle aspiration

have been encouraging in finding occult metastases (6, 7) and it seems reasonable to add ultrasound to a physical examination.

Patients managed with a 'wait-and-see' policy have a higher risk of recurrence (9%) than patients staged surgically (2.3%), whether staging has been performed by LAD or dynamic SNB. This finding only applies to patients without histopathological evidence of lymph node metastases.

Patients treated surgically because of lymph node metastases have an increased risk of recurrence (19%) (1). Based on these findings, a change in the follow-up scheme is proposed. For patients in a 'wait-and-see' programme and patients given LAD for proven lymph node metastases, follow-up should be every 3 months and should include ultrasound investigation of the groin. This intensive follow-up programme should be for 2 years, which is the period when recurrence is most likely. Imaging using CT has been replaced by ultrasound scanning with immediate fine-needle aspiration biopsy, although CT scans are still used in patients with a regional recurrence. So far, other imaging modalities have not proven reliable at detecting pelvic and retroperitoneal recurrences.

Bone scan and other tests are only recommended in symptomatic patients. The role of PET scan is unclear and therefore not advised as a routine procedure.

9.5 Guidelines for follow-up in penile cancer

Table 8 provides a follow-up schedule for penile cancer with grades of recommendation.

Table 8: Follow-up schedule for penile cancer

	Interval of follow-up		Examinations and Investigations	Maximum length of follow-up	GR
	Years 1 and 2	Years 3, 4 and 5			
<i>Recommendations for follow-up of primary tumour</i>					
Penile-preserving treatment	3 months	6 months	Regular physician or self-examination	5 years	C
Amputation	6 months	1 year	Regular physician or self-examination	5 years	C
<i>Recommendations for follow-up of the inguinal lymph nodes</i>					
'Wait-and-see'	3 months	6 months	Regular physician or self-examination Ultrasound with FNAB	5 years	C
pN0	6 months	1 year	Regular physician or self-examination Ultrasound with FNAB	5 years	C
pN+	3 months	6 months	Regular physician or self-examination Ultrasound with FNAB	5 years	C

GR = grade of recommendation; FNAB = fine-needle aspiration biopsy.

9.6 REFERENCES

1. Leijte JAP, Kirrander P, Antonini N, Windahl T, Horenblas S. Recurrence patterns of squamous cell carcinoma of the penis: recommendations for follow-up based on a two-centre analysis of 700 patients. *Eur Urol* 2008;54(1):161-8.
<http://www.ncbi.nlm.nih.gov/pubmed/18440124>
2. Horenblas S, van Tinteren H, Delamarre JFM, Moonen LM, Lustig V, van Waardenburg EW. Squamous cell carcinoma of the penis. III. Treatment of regional lymph nodes. *J Urol* 1993;149(3):492-7.
<http://www.ncbi.nlm.nih.gov/pubmed/8437253>.
3. Lont AP, Gallee MP, Meinhardt W, van Tinteren H, Horenblas S. Penis conserving treatment for T1 and T2 penile carcinoma: clinical implications of a local recurrence. *J Urol* 2006;176(2):575-80;discussion 580.
<http://www.ncbi.nlm.nih.gov/pubmed/16813892>

4. Horenblas S, Newling DW. Local recurrence tumour after penis-conserving therapy. A plea for longterm follow-up. *Br J Urol* 1993;72(6):976-9.
<http://www.ncbi.nlm.nih.gov/pubmed/8306171>
5. Kroon BK, Horenblas S, Lont AP, Tanis PJ, Gallee MP, Nieweg OE. Patients with penile carcinoma benefit from immediate resection of clinically occult lymph node metastases. *J Urol* 2005;173(3): 816-9.
<http://www.ncbi.nlm.nih.gov/pubmed/15711276>
6. Kroon BK, Horenblas S, Deurloo EE, Nieweg OE, Teertstra HJ. Ultrasonography-guided fine-needle aspiration cytology before sentinel node biopsy in patients with penile carcinoma. *BJU Int* 2005;95(4):517-21.
<http://www.ncbi.nlm.nih.gov/pubmed/15705071>
7. Krishna RP, Sistla SC, Smile R, Krishnan R. Sonography: An underutilized diagnostic tool in the assessment of metastatic groin nodes. *Clin Ultrasound* 2008;36(4):212-7.
<http://www.ncbi.nlm.nih.gov/pubmed/17960822>

10. QUALITY OF LIFE

10.1 Sexuality and fertility after cancer

As more people achieve long-term survival after cancer, sexual dysfunction and infertility are increasingly recognised as negative consequences affecting quality of life (1).

10.1.1 *Sexual activity and quality of life after penile cancer laser treatment*

A retrospective, face-to-face, structured interview study was carried out on Swedish patients treated with laser for localised penile carcinoma during 1986 to 2000 (2). Sixty-seven patients were treated, with 58 of them (mean age 63 years) still alive in 2006. Forty-six (79%) agreed to participate in the interview. Nearly all patients could recall their first symptom, with 37% reporting that they delayed seeking treatment for more than 6 months. Patients had a greater lifetime number of sexual partners and a greater lifetime prevalence of sexually transmitted infections than the comparable general Swedish population. Following laser treatment, there was a marked decrease in some sexual practices, such as manual stimulation or caressing and fellatio. Patient satisfaction with life overall was similar to that of the general population.

In conclusion, some patients delayed seeking treatment for a considerable period despite awareness of the first local symptoms. Men with laser-treated localised penile carcinoma resumed their sexual activities to a large extent. Except for satisfaction with somatic health, a similar (or higher) proportion of patients were satisfied with life overall and with other domains of life including sexual life.

10.1.2 *Sexual function after partial penectomy for penile cancer*

To compare sexual function and satisfaction before and after partial penectomy, 18 Brazilian patients were given a personal interview and answered the International Index of Erectile Function (IIEF) questionnaire to determine erectile function, orgasmic function, sexual desire, intercourse satisfaction and overall satisfaction with sexual life (3). The median patient age was 52 years. The medium penile length after partial penectomy was 4 cm in the flaccid state, with 55.6% of patients reporting erectile function that allowed sexual intercourse. The main reason given for not resuming sexual intercourse in 50% of sexually abstinent patients was feeling shame because of a small penis and the absence of the glans penis. Surgical complications also compromised resumption of sexual activity after amputation in 33.3% of these patients. However, 66.7% sustained the same frequency and level of sexual desire prior to surgery and 72.2% continued to have ejaculation and orgasm every time they had sexual stimulation or intercourse. Nevertheless, only 33.3% maintained their pre-operative sexual intercourse frequency and were satisfied with their sexual relationships with their partners and their overall sex life. In conclusion, the pre-operative and post-operative scores were statistically worse for all domains of sexual function after partial penectomy.

10.2 Sexual mutilation, relapse and death

Today, nearly 80% of penile cancer patients can be cured. Experience in management of this rare tumour is helpful (4). Referral to centers with experience is recommended.

Psychological support is very important for these patients. Penile-sparing surgery obviously allows a better quality of life than penile amputation and must be considered whenever feasible

10.3 REFERENCES

1. Schover LR. Sexuality and fertility after cancer. Hematology Am Soc Hematol Educ Program 2005;523-7.
<http://www.ncbi.nlm.nih.gov/pubmed/16304430>
2. Skeppner E, Windahl T, Andersson S, Fugl-Meyers KS. Treatment-seeking, aspects of sexual activity and life satisfaction in men with laser-treated penile carcinoma. Eur Urol 2008;54(3):631-9.
<http://www.ncbi.nlm.nih.gov/pubmed/18788122>
3. Romero FR, Romero KR, Mattos MA, Garcia CR, Fernandes Rde C, Perez MD. Sexual function after partial penectomy for penile cancer. Urology 2005;66(6):1292-5.
<http://www.ncbi.nlm.nih.gov/pubmed/16360459>
4. Leijte JA, Gallee M, Antonini N, Horenblas S. Evaluation of current TNM classification of penile carcinoma. J Urol 2008;180(3):933-8.
<http://www.ncbi.nlm.nih.gov/pubmed/18635216>

11. ABBREVIATIONS USED IN THE TEXT

This list is not comprehensive for the most common abbreviations.

BMP	cisplatin, methotrexate and bleomycin
BRT	brachytherapy
CT	computed tomography
DSNB	dynamic sentinel node biopsy
EAU	European Association of Urology
ERT	external beam irradiation
FDA	[US] Food and Drug Administration
FNAB	fine-needle aspiration biopsy
HDR	high-dose rate (brachytherapy)
HPV	human papillomavirus
IIEF	International Index of Erectile Function questionnaire
ITP	paclitaxel, ifosfamide and cisplatin
LAD	lymphadenectomy
LDR	low-dose rate (brachytherapy)
MRI	magnetic resonance imaging
NCI	National Cancer Institute
Nd-YAG	neodymium:yttrium-aluminum-garnet
PC	paclitaxel and carboplatin
PDQ	physician data query
PDR	pulse-dose rate (brachytherapy)
PET	positron emission tomography
PF	cisplatin and fluorouracil
PGE1	prostaglandin E1 (alprostadil)
SCC	squamous cell carcinoma
SNB	sentinel node biopsy
SWOG	Southwest Oncology Group
99mTC	technetium 99m
TNM	tumour, node, metastasis
TPF	taxanes combined with PF (cisplatin and fluorouracil)
VBM	vinblastine, bleomycin, methotrexate

Conflict of interest

All members of the Penile Cancer Guidelines writing panel have provided disclosure statements on all relationships that they have and that might be perceived to be a potential source of conflict of interest. This information is kept on file in the European Association of Urology Central Office database. This guidelines document was developed with the financial support of the European Association of Urology. No external sources of funding and support have been involved. The EAU is a non-profit organisation and funding is limited to administrative assistance and travel and meeting expenses. No honoraria or other reimbursements have been provided.

