

Guidelines on Paediatric Urology

S. Tekgül, H. Riedmiller, E. Gerharz, P. Hoebeke, R. Kocvara,
R. Nijman, Chr. Radmayr, R. Stein



TABLE OF CONTENTS

PAGE

1.	INTRODUCTION	6
1.1	Reference	6
2.	PHIMOSIS	6
2.1	Background	6
2.2	Diagnosis	7
2.3	Treatment	7
2.4	References	7
3.	CRYPTORCHIDISM	8
3.1	Background	8
3.2	Diagnosis	8
3.3	Treatment	9
3.3.1	Medical therapy	9
3.3.1.1	Medical therapy for testicular descent	9
3.3.1.2	Medical therapy for fertility potential	9
3.3.2	Surgery	9
	Palpable testis	9
	Non-palpable testis	9
3.4	Prognosis	10
3.5	References	10
4.	HYDROCELE	11
4.1	Background	11
4.2	Diagnosis	11
4.3	Treatment	11
4.4	References	12
5.	ACUTE SCROTUM IN CHILDREN	12
5.1	Background	12
5.2	Diagnosis	12
5.3	Treatment	13
5.3.1	Epididymitis	13
5.3.2	Testicular torsion	13
5.3.3	Surgical treatment	13
5.4	Prognosis	13
5.4.1	Fertility	13
5.4.2	Subfertility	14
5.4.3	Androgen levels	14
5.4.4	Testicular cancer	14
5.4.5	Nitric oxide	14
5.5	Perinatal torsion	14
5.6.	References	14
6.	HYPOSPADIAS	18
6.1	Background	18
6.1.1	Risk factors	18
6.2	Diagnosis	18
6.3	Treatment	18
6.3.1	Age at surgery	19
6.3.2	Penile curvature	19
6.3.3	Preservation of the well-vascularized urethral plate	19
6.3.4	Re-do hypospadias repairs	19
6.3.5	Urethral reconstruction	20
6.3.6	Urine drainage and wound dressing	20
6.3.7	Outcome	20
6.4	References	21

7.	CONGENITAL PENILE CURVATURE	22
7.1	Background	22
7.2	Diagnosis	22
7.3	Treatment	22
7.4	References	23
8.	VARICOCELE IN CHILDREN AND ADOLESCENTS	23
8.1	Background	23
8.2	Diagnosis	23
8.3	Therapy	24
8.4	References	24
9.	MICROPENIS	25
9.1	Background	25
9.2	Diagnosis	25
9.3	Treatment	26
9.4	References	26
10.	DAYTIME LOWER URINARY TRACT CONDITIONS	26
10.1	Background	26
10.2	Definition	27
10.2.1	Filling-phase dysfunctions	27
10.2.2	Voiding-phase (emptying) dysfunctions	27
10.3	Diagnosis	27
10.4	Treatment	28
10.4.1	Standard therapy	28
10.4.2	Specific interventions	28
10.5	References	28
11.	MONOSYMPTOMATIC ENURESIS	29
11.1	Background	29
11.2	Definition	30
11.3	Diagnosis	30
11.4	Treatment	30
11.4.1	Supportive treatment measures	30
11.4.2	Alarm treatment	30
11.4.3	Medication	30
11.5	References	31
12.	MANAGEMENT OF NEUROGENIC BLADDER IN CHILDREN	31
12.1	Background	31
12.2	Definition	32
12.3	Classification	32
12.4	Urodynamic studies	32
12.4.1	Method of urodynamic study	33
12.4.2	Uroflowmetry	33
12.4.3	Cystometry	33
12.5	Management	34
12.5.1	Investigations	34
12.5.2	Early management with clean intermittent catheterisation (CIC)	34
12.5.3	Medical therapy	34
12.5.3.1	Botulinum toxin injections	35
12.5.4	Management of bowel incontinence	35
12.5.5	Urinary tract infection	35
12.5.6	Sexuality	35
12.5.7	Bladder augmentation	35
12.5.8	Bladder outlet procedures	36
12.5.9	Continent stoma	36
12.5.10	Total bladder replacement	36

	12.5.11 Lifelong follow-up of neurogenic bladder patients	36
12.6	References	37
13.	DILATATION OF THE UPPER URINARY TRACT (URETEROPELVIC JUNCTION AND URETEROVESICAL JUNCTION OBSTRUCTION)	41
13.1	Background	41
13.2	Diagnosis	41
	13.2.1 Antenatal ultrasound	42
	13.2.2 Postnatal ultrasound	42
	13.2.3 Voiding cystourethrogram (VCUG)	42
	13.2.4 Diuretic renography	42
13.3	Treatment	43
	13.3.1 Prenatal management	43
	13.3.2 UPJ obstruction	43
13.4	Megaureter	43
13.5	Conclusion	43
13.6	References	43
14.	VESICoureteric Reflux (VUR)	44
14.1	Background	44
14.2	Classification	45
14.3	Diagnostic work-up	45
14.4	Treatment	46
	14.4.1 Conservative approach	46
	14.4.2 Interventional treatment	46
	14.4.2.1 Open surgery	46
	14.4.2.2 Laparoscopic reflux correction	46
	14.4.2.3 Endoscopic therapy	46
14.5	Follow-up	47
14.6	References	47
15.	URINARY STONE DISEASE	49
15.1	Background	49
15.2	Stone formation mechanism, diagnosis of causative factors and medical treatment for specific stone types	49
	15.2.1 Calcium stones	49
	Hypercalcuria	49
	Hyperoxaluria	50
	Hypocitraturia	50
	15.2.2 Uric acid stones	50
	15.2.3 Cystine stones	51
	15.2.4 Infection stones (struvite stones)	51
15.3	Clinical presentation	51
15.4	Diagnosis	51
	15.4.1 Imaging	51
	15.4.2 Metabolic evaluation	52
15.5	Management	52
	15.5.1 Extracorporeal shockwave lithotripsy (ESWL)	52
	15.5.2 Percutaneous nephrolithotomy	54
	15.5.3 Ureteroscopy	54
	15.5.4 Open stone surgery	54
15.6	References	55
16.	OBSTRUCTIVE PATHOLOGY OF RENAL DUPLICATION: URETEROCELE AND ECTOPIC URETER	59
16.1	Background	59
	16.1.1 Ureterocele	59
	16.1.2 Ectopic ureter	59
16.2	Classification	59
16.2.1	Ectopic ureterocele	60
	16.2.2 Orthotopic ureterocele	60

	16.2.3	Caecoureterocle	60
16.3		Diagnosis	60
	16.3.1	Ureterocele	60
	16.3.2	Ectopic ureter	60
16.4		Treatment	60
	16.4.1	Ureterocele	60
		16.4.1.1 Early diagnosis	61
		16.4.1.2 Re-evaluation	61
	16.4.2	Ectopic ureter	61
16.5		References	61
17.		DISORDERS OF SEX DEVELOPMENT	62
	17.1	Background	62
	17.2	The neonatal emergency	63
		17.2.1 Family history and clinical examination	63
		17.2.2 Choice of laboratory investigations	64
	17.3	Gender assignment	64
	17.4	Role of the paediatric urologist	64
		17.4.1 Diagnosis	64
		17.4.1.1 Clinical examination	64
		17.4.1.2 Investigations	65
	17.5	Management	65
		17.5.1 Feminizing surgery	65
		17.5.2 Masculinizing surgery	65
	17.6	REFERENCES	66
18.		POSTERIOR URETHRAL VALVES	67
	18.1	Background	67
	18.2	Classification	67
		18.2.1 Urethral valve	67
	18.3	Diagnosis	67
	18.4	Treatment	68
		18.4.1 Antenatal treatment	68
		18.4.2 Postnatal treatment	68
		Bladder drainage	68
		Valve ablation	68
		Vesicostomy	68
		High diversion	68
	18.5	References	70
19.		ABBREVIATIONS USED IN THE TEXT	72

1. INTRODUCTION

A collaborative working group consisting of members representing the European Society for Paediatric Urology (ESPU) and the European Association of Urology (EAU) has gathered in an effort to produce the current update of the paediatric urology guidelines. The aim of this close collaboration between a subspecialty group and its parent specialty is to make a document available that may help to increase the quality of care for children with urological problems.

The majority of urological clinical problems in children are distinct and in many ways different to those in adults. The aim of this work is to outline a practical and preliminary approach to paediatric urological problems. Complex and rare conditions that require special care with experienced doctors should be referred to designated centres where paediatric urology practice has been fully established and a multidisciplinary approach is available.

For quite some time, paediatric urology has informally developed, expanded, matured and established its diverse body of knowledge and expertise and may now be ready to distinguish itself from its parent specialties. Thus, paediatric urology has recently emerged in many European countries as a distinct subspecialty of both urology and paediatric surgery, and presents a unique challenge in the sense that it covers a large area with many different schools of thought and a huge diversity in management.

Knowledge gained by increasing experience, new technological advances and non-invasive diagnostic screening modalities has had a profound influence on treatment modalities in paediatric urology, a trend that is likely to continue in the years to come. We now have new techniques for the treatment of reflux, our techniques for the treatment of complex congenital anomalies have substantially improved and totally new technologies for bladder replacement and laparoscopic procedures have been developed. There is also an increasing body of knowledge in paediatric urology related to basic research.

Paediatric urology covers a huge field within urology. The scope and complexity of paediatric urology practice continues to expand. Capturing the entire field of paediatric urology in a single guideline document was never an option, but we will keep on amending and adding on this document on a regular basis. This year there are two new chapters within the document and eight chapters have been revised.

The guidelines were compiled by the collaborative working group and based on current literature following a systematic review using MEDLINE. Application of a structured analysis of the literature was not possible in many conditions due to a lack of well-designed studies. Whenever possible, statements have been classified in terms of level of evidence and grade of recommendation (1). Due to the limited availability of large randomized controlled trials – influenced also by the fact that a considerable number of treatment options relate to surgical interventions on a large spectrum of different congenital problems – this document will therefore largely be a consensus document.

We hope that you will consider this document to be a valuable educational resource for your practice and that it will provide you with guidance in the care of your cases in paediatric urology.

1.1. REFERENCE

1. Oxford Centre for Evidence-based Medicine Levels of Evidence (May 2001). Produced by Bob Phillips, Chris Ball, Dave Sackett, Doug Badenoch, Sharon Straus, Brian Haynes, Martin Dawes since November 1998
<http://www.cebm.net/index.aspx?o=1025> [access date February 2009].

2. PHIMOSIS

2.1 Background

At the end of the first year of life, retraction of the foreskin behind the glandular sulcus is possible in only about 50% of boys; this rises to approximately 89% by the age of 3 years. The incidence of phimosis is 8% in 6 to 7-year-olds and just 1% in males aged 16-18 years (1). The phimosis is either primary (physiological) with no sign of scarring, or secondary (pathological) to a scarring such as balanitis xerotica obliterans. Phimosis has to

be distinguished from normal agglutination of the foreskin to the glans, which is a physiological phenomenon (2).

The paraphimosis must be regarded as an emergency situation: retraction of a too narrow prepuce behind the glans penis into the glanular sulcus may constrict the shaft and lead to oedema. It interferes with perfusion distally from the constrictive ring and brings a risk of consecutive necrosis.

2.2 Diagnosis

The diagnosis of phimosis and paraphimosis is made by physical examination.

If the prepuce is not retractable or only partly retractable and shows a constrictive ring on drawing back over the glans penis, a disproportion between the width of the foreskin and the diameter of the glans penis has to be assumed. In addition to the constricted foreskin, there may be adhesions between the inner surface of the prepuce and the glanular epithelium and/or a fraenum breve. A fraenum breve leads to a ventral deviation of the glans once the foreskin is retracted. If the tip remains narrow and glanular adhesions were separated, than the space is filled with urine during voiding causing the foreskin to balloon outward.

The paraphimosis is characterized by retracted foreskin with the constrictive ring localized at the level of the sulcus, which prevents replacement of the foreskin over the glans.

2.3 Treatment

Treatment of phimosis in children is dependent on the parents' preferences and can be plastic or radical circumcision after completion of the second year of life. Plastic circumcision has the objective of achieving a wide foreskin circumference with full retractability, while the foreskin is preserved (dorsal incision, partial circumcision). However, this procedure carries the potential for recurrence of the phimosis. In the same session, adhesions are released and an associated fraenum breve is corrected by fraenulotomy. Meatoplasty is added if necessary.

An absolute indication for circumcision is secondary phimosis. The indications in primary phimosis are recurrent balanoposthitis and recurrent urinary tract infections in patients with urinary tract abnormalities (3-6) (level of evidence: 2, grade B recommendation). Simple ballooning of the foreskin during micturition is not a strict indication for circumcision.

Routine neonatal circumcision to prevent penile carcinoma is not indicated. Contraindications for circumcision are coagulopathy, an acute local infection and congenital anomalies of the penis, particularly hypospadias or buried penis, because the foreskin may be required for a reconstructive procedure (7, 8). Childhood circumcision has an appreciable morbidity and should not be recommended without a medical reason (9-12) (level of evidence: 2, grade B recommendation). As a conservative treatment option of the primary phimosis, a corticoid ointment or cream (0.05-0.1%) can be administered twice a day over a period of 20-30 days (13-16) (level of evidence: 1, grade A recommendation). This treatment has no side effects and the mean bloodspot cortisol levels are not significantly different from an untreated group of patients (17) (level of evidence: 1). Agglutination of the foreskin does not respond to steroid treatment (14) (level of evidence: 2).

Treatment of paraphimosis consists of manual compression of the oedematous tissue with a subsequent attempt to retract the tightened foreskin over the glans penis. Injection of hyaluronidase beneath the narrow band may be helpful to release it (18) (level of evidence: 4, grade C recommendation). If this manoeuvre fails, a dorsal incision of the constrictive ring is required. Depending on the local findings, a circumcision is carried out immediately or can be performed in a second session.

2.4 REFERENCES

1. Gairdner D. The fate of the foreskin: a study of circumcision. *Br Med J* 1949;2(4642):1433-7.
<http://www.ncbi.nlm.nih.gov/pubmed/15408299>
2. Oster J. Further fate of the foreskin. Incidence of preputial adhesions, phimosis, and smegma among Danish schoolboys. *Arch Dis Child* 1968;43(288):200-3.
<http://www.ncbi.nlm.nih.gov/pubmed/5689532>
3. Wiswell TE. The prepuce, urinary tract infections, and the consequences. *Pediatrics* 2000;105(4 Pt 1): 860-2.
<http://www.ncbi.nlm.nih.gov/pubmed/10742334>
4. Hiraoka M, Tsukahara H, Ohshima Y, Mayumi M. Meatus tightly covered by the prepuce is associated with urinary tract infection. *Pediatr Int* 2002;44(6):658-62.
<http://www.ncbi.nlm.nih.gov/pubmed/12421265>
5. To T, Agha M, Dick PT, Feldman W. Cohort study on circumcision of newborn boys and subsequent risk of urinary tract infection. *Lancet* 1998;352(9143):1813-6.
<http://www.ncbi.nlm.nih.gov/pubmed/9851381>
6. Herndon CDA, McKenna PH, Kolon TF, Gonzales ET, Baker LA, Docimo SG. A multicenter outcomes analysis of patients with neonatal reflux presenting with prenatal hydronephrosis. *J Urol* 1999;162(3 Pt 2):1203-8.
<http://www.ncbi.nlm.nih.gov/pubmed/10458467>

7. Thompson HC, King LR, Knox E, Korones SB. Report of the ad hoc task force on circumcision. *Pediatrics* 1975;56(4):610-1.
<http://www.ncbi.nlm.nih.gov/pubmed/1174384>
8. American Academy of Pediatrics. Report of the Task Force on Circumcision. *Pediatrics* 1989;84:388-91. Erratum in: *Pediatrics* 1989;84(2):761.
<http://www.ncbi.nlm.nih.gov/pubmed/2664697>
9. Griffiths DM, Atwell JD, Freeman NV. A prospective study of the indications and morbidity of circumcision in children. *Eur Urol* 1985;11(3):184-7.
<http://www.ncbi.nlm.nih.gov/pubmed/4029234>
10. Christakis DA, Harvey E, Zerr DM, Feudtner C, Wright JA, Connell FA. A trade-off analysis of routine newborn circumcision. *Pediatrics* 2000;105(1 Pt 3):246-9.
<http://www.ncbi.nlm.nih.gov/pubmed/10617731>
11. Ross JH. Circumcision: Pro and con. In: Elder JS, ed. *Pediatric urology for the general urologist*. New York: Igaku-Shoin, 1996, pp. 49-56.
12. Hutcheson JC. Male neonatal circumcision: indications, controversies and complications. *Urol Clin N Amer* 2004;31(3):461-7.
<http://www.ncbi.nlm.nih.gov/pubmed/15313055>
13. Monsour MA, Rabinovitch HH, Dean GE. Medical management of phimosis in children: our experience with topical steroids. *J Urol* 1999;162(3 Pt 2):1162-4.
<http://www.ncbi.nlm.nih.gov/pubmed/10458456>
14. Chu CC, Chen KC, Diau GY. Topical steroid treatment of phimosis in boys. *J Urol* 1999;162(3 Pt 1):861-3.
<http://www.ncbi.nlm.nih.gov/pubmed/10458396>
15. ter Meulen PH, Delaere KP. A conservative treatment of phimosis on boys. *Eur Urol* 2001;40(2):196-9; discussion 200.
<http://www.ncbi.nlm.nih.gov/pubmed/11528198>
16. Elmore JM, Baker LA, Snodgrass WT. Topical steroid therapy as an alternative to circumcision for phimosis in boys younger than 3 years. *J Urol* 2002;168(4 Pt 2):1746-7; discussion 1747.
<http://www.ncbi.nlm.nih.gov/pubmed/12352350>
17. Golubovic Z, Milanovic D, Vukadinovic V, Rakic I, Perovic S. The conservative treatment of phimosis in boys. *Br J Urol* 1996;78(5):786-8.
<http://www.ncbi.nlm.nih.gov/pubmed/8976781>
18. DeVries CR, Miller AK, Packer MG. Reduction of paraphimosis with hyaluronidase. *Urology* 1996;48(3):464-5.
<http://www.ncbi.nlm.nih.gov/pubmed/8804504>

3. CRYPTORCHIDISM

3.1 Background

At the age of 1 year, almost 1% of all full-term male infants are affected by this most common congenital anomaly associated with the genitalia of newborn males (1). Because knowledge of the location and existence of the testis directly influences clinical management, it seems appropriate to categorise the testes into palpable and non-palpable.

Retractile testes do not need any form of treatment except observation as they can become ascendant. Retractile testes have completed their descent but may be found in the groin because of a strong cremasteric reflex (2).

In the case of bilateral non-palpable testes and any suggestion of sexual differentiation problems, such as hypospadias, urgent endocrinological and genetic evaluation is mandatory (3) (level of evidence: 3, grade of recommendation: B).

3.2 Diagnosis

A physical examination is the only method of differentiating between palpable or non-palpable testes. There is no additional benefit in performing ultrasound, computed tomography (CT), magnetic resonance imaging (MRI) or angiography.

Clinical examination includes a visual description of the scrotum and an examination of the child while supine and in crossed-leg position. The examiner should inhibit the cremasteric reflex with his non-dominant hand right above the symphysis in the groin region before touching, or reaching for, the scrotum. The groin

region may be 'milked' towards the scrotum in an attempt to move the testis into the scrotum. This manoeuvre also makes it possible to differentiate between an inguinal testis and enlarged lymph nodes that could give the impression of an undescended testis.

A retractile testis can generally be brought into the scrotum, where it will remain until a cremasteric reflex (touching the inner thigh skin) will retract it again into the groin (4).

A unilateral non-palpable testis and an enlarged contralateral testis may suggest testicular absence or atrophy, but this finding is not specific and does not preclude surgical exploration. Specific visual attention should be given to the femoral, penile and perineal region in the case of an inguinal non-palpable testis to exclude an ectopic testis.

There is no reliable examination to confirm or exclude an intra-abdominal, inguinal and absent/vanishing testis (non-palpable testis), except for diagnostic laparoscopy (5) (level of evidence: 1b, grade of recommendation: A). Before instigating laparoscopic assessment, an examination under general anaesthesia is recommended because some originally non-palpable testes are palpable under anaesthetic conditions.

3.3 Treatment

If a testis has not descended by the age of 1 year, there is no benefit in waiting for a spontaneous descent. To prevent histological deterioration, treatment should be carried out and finished before 12-18 months of age (6).

3.3.1 Medical therapy

3.3.1.1 Medical therapy for testicular descent

Medical therapy using human chorionic gonadotrophin (hCG) or gonadotrophin-releasing hormone (GnRH) is based on the hormonal dependence of testicular descent with success rates of a maximum of 20% (level of evidence: 1, grade of recommendation: C) (7, 8). Hormonal therapy for testicular descent has lower success rates the higher the undescended testis is located. Human chorionic gonadotrophin is used in a total dosage of 6.000-9.000 IU, given in four dosages within 2 to 3 weeks depending on weight and age and GnRH in a dosage of 1.2 mg/day divided into three dosages per day for 4 weeks using a nasal spray, respectively.

3.3.1.2 Medical therapy for fertility potential

Medical treatment can be beneficial before (dosage as described above), or after (low intermittent dosages) surgical orchidolysis and orchidopexy (14) in terms of increasing the fertility index, which may act as a predictor for fertility later on in life (level of evidence 1b, grade of recommendation A). However, data from the long-term follow-up of the impact of hormonal treatment on fertility potential is still lacking.

3.3.2 Surgery

Palpable testis. Surgery for the palpable testis includes orchidofuniculolysis and orchidopexy, via an inguinal approach, with success rates of up to 92% (9). It is important to remove and dissect all cremasteric fibres to prevent secondary retraction. Associated problems, such as an open processus vaginalis, must be carefully dissected and closed. It is recommended that the testis is placed in a subdartos pouch. With regard to sutures, there should either be no fixation sutures or they should be made between the tunica vaginalis and the dartos musculature.

The lymph drainage of a testis that has undergone surgery for orchidopexy has been changed from iliac drainage to iliac and inguinal drainage (important in the event of later malignancy).

Non-palpable testis. In the situation of a non-palpable testis, inguinal surgical exploration with the possibility of performing laparoscopy should be attempted. There is a significant chance of finding the testis via an inguinal incision, but in rare cases, it is necessary to search into the abdomen if there are no vessels or vas deferens in the groin. Laparoscopy is the most appropriate way of examining the abdomen for a testis. In addition, either removal or orchidolysis and orchidopexy can be performed via laparoscopic access (10). Before starting diagnostic laparoscopy, it is recommended that the child be examined again under general anaesthesia since a previous non-palpable testis might now be palpable under anaesthetic conditions.

An intra-abdominal testis in a 10-year-old boy or older with a normal contralateral testis should be removed. In bilateral intra-abdominal testes, or in a boy younger than 10 years, a one-stage or two-stage Fowler-Stephens procedure can be performed. In the event of a two-stage procedure, the spermatic vessels are either laparoscopically clipped or coagulated proximal to the testis to allow development of the collateral vasculature (11). The second-stage procedure, in which the testis is brought directly over the symphysis and next to the bladder into the scrotum, can also be performed by laparoscopy 6 months later. The testicular survival rate in a one-stage procedure varies between 50% and 60%, with success rates rising up to 90% in a two-stage procedure (12). Microvascular autotransplantation can also be performed with 90% testicular survival rate. However, the procedure requires a very skilful and experienced surgical technique (13).

3.4 Prognosis

Boys with one undescended testis have a lower fertility rate but the same paternity rate as boys with bilateral descended testes. Boys with bilateral undescended testes have both a lower fertility and paternity rate.

Boys with an undescended testis have a 20-fold higher chance of developing testicular malignancy, a risk which is uninfluenced by any kind of treatment. Screening both during and after puberty is therefore recommended for these boys. A recent Swedish study followed up a cohort of nearly 17,000 men treated surgically for undescended testis for a total of almost 210,000 person-years. The study revealed that treatment for undescended testis before puberty decreases the risk of testicular cancer. The relative risk of testicular cancer among those who underwent orchiopexy before reaching 13 years of age was 2.23 as compared with the Swedish general population; for those treated at 13 years of age or older, the relative risk was 5.40 (15). In addition, an American group has published a systematic review and meta-analysis of the literature and concluded similarly that prepubertal orchiopexy may indeed decrease the risk of testicular cancer and that early surgical intervention is indicated in children with cryptorchidism (16).

Boys with retractile testes do not need medical or surgical treatment but require close follow-up until puberty.

Due to the lack of spontaneous testicular descent after the age of 1 year, and because of the potential loss of testicular quality, it is recommended that surgical orchidolysis and orchidopexy are performed at the latest by 12-18 months of age. To date, it seems that pre- or post-operative hormonal treatment may have a beneficial effect on fertility later in life.

3.5 REFERENCES

1. Berkowitz GS, Lapinski RH, Dolgin SE, Gazella JG, Bodian CA, Holzman IR. Prevalence and natural history of cryptorchidism. *Pediatrics* 1993;92(1):44-9.
<http://www.ncbi.nlm.nih.gov/pubmed/8100060>
2. Caesar RE, Kaplan GW. The incidence of the cremasteric reflex in normal boys. *J Urol* 1994;152(2 Pt 2):779-80.
<http://www.ncbi.nlm.nih.gov/pubmed/7912745>
3. Rajfer J, Walsh PC. The incidence of intersexuality in patients with hypospadias and cryptorchidism. *J Urol* 1976;116(6):769-70.
<http://www.ncbi.nlm.nih.gov/pubmed/12377>
4. Rabinowitz R, Hulbert WC Jr. Late presentation of cryptorchidism: the etiology of testicular re-ascent. *J Urol* 1997;157(5):1892-4.
<http://www.ncbi.nlm.nih.gov/pubmed/9112557>
5. Cisek LJ, Peters CA, Atala A, Bauer SB, Diamond DA, Retik AB. Current findings in diagnostic laparoscopic evaluation of the nonpalpable testis. *J Urol* 1998;160(3 Pt 2):1145-9; discussion 1150.
<http://www.ncbi.nlm.nih.gov/pubmed/9719296>
6. Huff DS, Hadziselimovic F, Snyder HM 3rd, Blythe B, Duckett JW. Histologic maldevelopment of unilaterally cryptorchid testes and their descended partners. *Eur J Pediatr* 1993;152 Suppl:S11-S14.
<http://www.ncbi.nlm.nih.gov/pubmed/8101802>
7. Rajfer J, Handelsman DJ, Swerdloff RS, Hurwitz R, Kaplan H, Vandergast T, Ehrlich RM. Hormonal therapy of cryptorchidism. A randomized, double-blind study comparing human chorionic gonadotropin and gonadotropin-releasing hormone. *N Engl J Med* 1986;314(8):466-70.
<http://www.ncbi.nlm.nih.gov/pubmed/2868413>
8. Pyorala S, Huttunen NP, Uhari M. A review and meta-analysis of hormonal treatment of cryptorchidism. *J Clin Endocrinol Metab* 1995;80(9):2795-9.
<http://www.ncbi.nlm.nih.gov/pubmed/7673426>
9. Docimo SG. The results of surgical therapy for cryptorchidism: a literature review and analysis. *J Urol* 1995;154:1148-52.
<http://www.ncbi.nlm.nih.gov/pubmed/7637073>
10. Jordan GH, Winslow BH. Laparoscopic single stage and staged orchiopexy. *J Urol* 1994;152(4):1249-52.
<http://www.ncbi.nlm.nih.gov/pubmed/7915336>
11. Bloom DA. Two-step orchiopexy with pelviscopic clip ligation of the spermatic vessels. *J Urol* 1991;145(5):1030-3.
<http://www.ncbi.nlm.nih.gov/pubmed/1673160>
12. Radmayr C, Oswald J, Schwentner C, Neururer R, Peschel R, Bartsch G. Long-term outcome of laparoscopically managed nonpalpable testes. *J Urol* 2003;170(6 Pt 1):2409-11.
<http://www.ncbi.nlm.nih.gov/pubmed/14634439>

13. Wacksman J, Billmire DA, Lewis AG, Sheldon CA. Laparoscopically assisted testicular autotransplantation for management of the intraabdominal undescended testis. *J Urol* 1996;156(2 Pt 2):772-4.
<http://www.ncbi.nlm.nih.gov/pubmed/8683780>
14. Schwentner C, Oswald J, Kreczy A, Lunacek A, Bartsch G, Deibl M, Radmayr C. Neoadjuvant gonadotropin releasing hormone therapy before surgery may improve the fertility index in undescended testes – a prospective randomized trial. *J Urol* 2005;173(3): 974-7.
<http://www.ncbi.nlm.nih.gov/pubmed/15711353>
15. Pettersson A, Richiardi L, Nordenskjold A, Kaijser M, Akre O. Age at surgery for undescended testis and risk of testicular cancer. *N Engl J Med* 2007;356(18):1835-41.
<http://www.ncbi.nlm.nih.gov/pubmed/17476009>
16. Walsh T, Dall'Era M, Croughan M, Carroll P, Turek P. Prepubertal orchiopexy for cryptorchidism may be associated with a lower risk of testicular cancer. *J Urol* 2007;178: 1440-6; discussion 1446.
<http://www.ncbi.nlm.nih.gov/pubmed/17706709>

4. HYDROCELE

4.1 Background

Hydrocele is defined as a collection of fluid between the parietal and visceral layer of tunica vaginalis (1). Pathogenesis of hydrocele is based on an imbalance between the secretion and reabsorption of this fluid. This is in contrast with inguinal hernia, which is defined as the protrusion of a portion of organs or tissues through the abdominal wall (2). Incomplete obliteration of the processus vaginalis peritonei results in formation of various types of communicating hydrocele alone or connected with other intrascrotal pathology (hernia). The exact time of obliteration of processus vaginalis is not known. It persists in approximately 80-94% of newborns and in 20% of adults (3). If complete obliteration of processus vaginalis occurs with patency of midportion, a hydrocele of the cord occurs. Scrotal hydroceles without associated patency of the processus vaginalis are encountered in newborns as well (4). Non-communicating hydroceles are found secondary to minor trauma, testicular torsion, epididymitis, varicocele operation or may appear as a recurrence after primary repair of a communicating hydrocele.

4.2 Diagnosis

The classic description of a communicating hydrocele is that of a hydrocele that vacillates in size, and is usually related to activity. It may be diagnosed by history; physical investigation and transillumination of the scrotum make the diagnosis in the majority of cases (5). If the diagnosis is that of a hydrocele, there will be no history of reducibility and no associated symptoms; the swelling is translucent, smooth and usually non-tender. If there are any doubts about the character of an intrascrotal mass, scrotal ultrasound should be performed and has nearly 100% sensitivity in detecting intrascrotal lesions. Doppler ultrasound studies help to distinguish hydroceles from varicocele and testicular torsion, although these conditions may also be accompanied by a hydrocele.

4.3 Treatment

In the majority of infants, the surgical treatment of hydrocele is not indicated within the first 12-24 months because of the tendency for spontaneous resolution (level of evidence: 4, grade C recommendation). Early surgery is indicated if there is suspicion of a concomitant inguinal hernia or underlying testicular pathology (6). The question of contralateral disease should be addressed by both history and examination at the time of initial consultation (5). Persistence of a simple scrotal hydrocele beyond 24 months of age may be an indication for surgical correction. However, there is no evidence that this type of hydrocele risks testicular damage. In the paediatric age group, the operation consists of ligation of patent processus vaginalis via inguinal incision and the distal stump is left open, whereas in hydrocele of the cord the cystic mass is excised or unroofed (1,5,6) (level of evidence: 4, grade C recommendation). In expert hands, the incidence of testicular damage during hydrocele or inguinal hernia repair is very low (0.3%) (level of evidence: 3, grade B recommendation). Sclerosing agents should not be used because of the risk of chemical peritonitis in communicating processus vaginalis peritonei (5,6) (level of evidence: 4, grade C recommendation). The scrotal approach (Lord or Jaboulay technique) is used in the treatment of a secondary non-communicating hydrocele.

4.4 REFERENCES

1. Kapur P, Caty MG, Glick PL. Pediatric hernias and hydroceles. *Pediatric Clin North Am* 1998;45(4): 773-89.
<http://www.ncbi.nlm.nih.gov/pubmed/9728185>
2. Barthold JS, Kass EJ. Abnormalities of the penis and scrotum. In: Belman AB, King LR, Kramer SA, eds. *Clinical pediatric urology*. 4th edn. London: Martin Dunitz, 2002, pp. 1093-1124.
3. Schneck FX, Bellinger MF. Abnormalities of the testes and scrotum and their surgical management. In: Walsh PC, Retik AB, Vaughan ED, Wein AJ, eds. *Campbell's urology*. 8th edn. Philadelphia: WB Saunders, 2002, pp. 2353-94.
4. Rubenstein RA, Dogra VS, Seftel AD, Resnick MI. Benign intrascrotal lesions. *J Urol* 2004;171(5): 1765-72.
<http://www.ncbi.nlm.nih.gov/pubmed/15076274>
5. Skoog SJ. Benign and malignant pediatric scrotal masses. *Pediatr Clin North Am* 1997;44(5):1229-50.
<http://www.ncbi.nlm.nih.gov/pubmed/9326960>
6. Stringer MD, Godbole PP. Patent processus vaginalis. In: Gearhart JP, Rink RC, Mouriouand PD, eds. *Pediatric urology*. Philadelphia: WB Saunders, 2001, pp. 755-762.

5. ACUTE SCROTUM IN CHILDREN

5.1 Background

Acute scrotum is a paediatric urology emergency case, most commonly caused by torsion of the testis, torsion of the appendix testis and epididymitis/epididymo-orchitis (1-6). Other causes of acute scrotal pain are idiopathic scrotal oedema, mumps orchitis, varicocele, scrotal haematoma, incarcerated hernia, appendicitis or systemic disease (Henoch-Schönlein purpura) (7-19).

Torsion of the testis occurs most often in the neonatal period and around puberty, while torsion of the appendix testes occurs over a wider age range. Acute epididymitis affects two age groups: below the age of 1 year and between 12 and 15 years (5, 20, 21). Acute epididymitis was found most often (37-64.6%) in boys with acute scrotum (1-4). One study predicted the incidence of epididymitis as about 1.2 per 1,000 male children per year (22).

5.2 Diagnosis

Patients usually present with scrotal pain. The duration of symptoms is shorter in testicular torsion (69% present within 12 hours) compared to torsion of the appendix testes (62%) and acute epididymitis (31%) (5, 6, 20).

In the early phase, location of the pain can lead to the diagnosis. Patients with acute epididymitis experience a tender epididymitis, while patients with testicular torsion are more likely to have a tender testicle and patients with torsion of the appendix testis feel isolated tenderness of the superior pole of the testis (20).

An abnormal position of the testis was more frequent in testicular torsion than in patients with epididymitis (20). Looking for the absence of the cremasteric reflex is a simple method with a sensitivity of 100% and specificity of 66% for the presence of testicular torsion (21, 23) (Level of evidence: 3; Grade of recommendation: C).

Fever occurs often in epididymitis (11-19%). The classical sign of a 'blue dot' was found only in 10-23% patients with torsion of the appendix testis (4, 6, 21, 24).

In many cases, it is not easy to determine the cause of acute scrotum based on history and physical examination alone (1-6, 21, 24).

A positive urine culture is only found in a few patients with epididymitis (3, 21, 24, 25). It should be remembered that a normal urinalysis does not exclude epididymitis. Similarly, an abnormal urinalysis does not exclude testicular torsion.

Doppler ultrasound is useful to evaluate an acute scrotum, with a sensitivity of 63.6-100% and a specificity of 97-100%, and a positive predictive value of 100% and negative predictive value 97.5% (26-31) (Level of evidence: 3; Grade of recommendation: C). The use of Doppler ultrasound may reduce the number of patients with acute scrotum undergoing scrotal exploration, but it is operator-dependent and can be difficult to perform in prepubertal patients (29, 32). It may also show a misleading arterial flow in the early phases of torsion and in partial or intermittent torsion: persistent arterial flow does not exclude testicular torsion. In a multicentre study of 208 boys with torsion of the testis, 24% patients had normal or increased testicular vascularization (29). Better results were reported using high-resolution ultrasonography (HRUS) for direct visualization of the spermatic cord twist with a sensitivity of 97.3% and a specificity of 99% (29, 33) (Level of

evidence: 2; Grade of recommendation: C).

Scintigraphy and, more recently, dynamic contrast-enhanced subtraction MRI of the scrotum also provide a comparable sensitivity and specificity to ultrasound (34-37). These investigations may be used when diagnosis is less likely and if torsion of the testis still cannot be excluded from history and physical examination. This should be done without inordinate delays for emergent intervention (24).

The diagnosis of acute epididymitis in boys is mainly based on clinical judgement and adjunctive investigation. However, it should be remembered that findings of secondary inflammatory changes in the absence of evidence of an extra-testicular nodule by Doppler ultrasound might suggest an erroneous diagnosis of epididymitis in children with torsion of appendix testes (38).

Prepubertal boys with acute epididymitis have an incidence of underlying urogenital anomalies of 25-27.6%. Complete urological evaluation in all children with acute epididymitis is still debatable (3, 21, 22).

5.3 Treatment

5.3.1 Epididymitis

In prepubertal boys, the aetiology is usually unclear, with an underlying pathology of about 25%. A urine culture is usually negative, and unlike in older boys, a sexually transmitted disease is very rare.

Antibiotic treatment, although often started, is not indicated in most cases unless urinalysis and urine culture show a bacterial infection (22,39). Epididymitis is usually self-limiting and with supportive therapy (i.e. minimal physical activity and analgesics) heals without any sequelae (Level of evidence: 3; Grade of recommendation: C). However, bacterial epididymitis can be complicated by abscess or necrotic testis and surgical exploration is required (40).

Torsion of the appendix testis can be managed conservatively (Level of evidence: 4; Grade of recommendation: C). During the six-week-follow-up, clinically and with ultrasound, no testicular atrophy was revealed. Surgical exploration is done in equivocal cases and in patients with persistent pain (27).

5.3.2 Testicular torsion

Manual detorsion of the testis is done without anaesthesia. It should initially be done by outwards rotation of the testis unless the pain increases or if there is obvious resistance. Success is defined as the immediate relief of all symptoms and normal findings at physical examination (41) (Level of evidence: 3; Grade of recommendation: C). Doppler ultrasound may be used for guidance (42).

Bilateral orchiopexy is still required after successful detorsion. This should not be done as an elective procedure, but rather immediately following detorsion. One study reported residual torsion during exploration in 17 out of 53 patients, including 11 patients who had reported pain relief after manual detorsion (41, 43).

5.3.3 Surgical treatment

Testicular torsion is an urgent condition, which requires prompt surgical treatment. The two most important determinants of early salvage rate of the testis are the time between onset of symptoms and the detorsion and degree of twisting of the cord (44). Severe testicular atrophy occurred after torsion for as little as 4 hours when the turn was more than 360°. In cases of incomplete torsion (180° to 360°), with symptom duration up to 12 hours, no atrophy was observed. However, an absent or severely atrophied testis was found in all cases of torsion of more than 360° and symptom duration of more than 24 hours (45).

Early surgical intervention with detorsion (mean torsion time < 13 hours) was found to preserve fertility (46). Urgent surgical exploration is mandatory in all cases of testicular torsion within 24 hours of the onset of symptoms.

In those patients with testicular torsion of more than 24 hours, semi-elective exploration is necessary (44,45) (Level of evidence: 3; Grade of recommendation: C). Until now, there is still controversy to carry out detorsion and to preserve the ipsilateral testis, or to perform an orchiectomy, in order to preserve contralateral function and fertility after testicular torsion of long duration (> 24 hours).

A recent study in humans found that sperm quality was preserved in both orchiectomy and orchiopexy groups in comparison to control normal men, although orchiectomy resulted in better sperm morphology (47).

During exploration, fixation of the contralateral testis is also performed. Recurrence after orchiopexy is rare (4.5%) and may occur several years after operation. There is no common recommendation about the preferred type of fixation and suture material; however, many urologists currently use a Dartos pouch orchiopexy (48).

External cooling before exploration and several medical treatments seem effective in reducing ischaemia-reperfusion injury and preserving the viability of the torsed testis and the contralateral testis (49-53).

5.4 Prognosis

5.4.1 Fertility

The results vary and are conflicting. In one study, unilateral torsion of the testis seriously intervened with

subsequent spermatogenesis in about 50% of the patients and produced borderline impairment in another 20%.

5.4.2 Subfertility

Subfertility is found in 36-39% of the patients after torsion. Semen analysis may be normal in only 5-50% in long-term follow-up (44). Early surgical intervention (mean torsion time < 13 hours) with detorsion was found to preserve fertility, but prolonged torsion periods (mean torsion time of 70 hours) followed by orchiectomy jeopardizes fertility (46).

One study identified antisperm antibodies in the semen of patients with testicular torsion and correlated antibody levels with infertility, while other studies have failed to confirm these results (44,47). Anderson et al. found pre-existing contralateral testis abnormalities in biopsies performed at the time of surgery and did not detect any case of antisperm antibodies after testicular torsion (46).

5.4.3 Androgen levels

A study in rats showed a long-term reduction in testicular androgen production after testicular torsion. This effect was considered to be caused by reperfusion/ oxidative stress in the testis (45). Even though the levels of FSH, LH and testosterone are higher in patients after testicular torsion compared to normal controls, endocrine testicular function remains in the normal range in patients after testicular torsion (47).

5.4.4 Testicular cancer

There may be a 3.2-fold increased risk of developing a testis tumour 6-13 years after torsion. However, two of nine reported cases had torsion of a tumour-bearing testis and four had a tumour in the contralateral testis to the torsed testicle (44).

5.4.5 Nitric oxide

A study in rats found that spermatic cord torsion did not lead to impairment in nitric oxide-mediated relaxant responses of the isolated penile bulb (54).

5.5 Perinatal torsion

Perinatal torsion of the testis most often occurs prenatally. After birth, perinatal torsion occurs in 25%, with bilateral perinatal torsion comprises 11-21% of all perinatal torsions (55). Most cases are extravaginal torsion in contrast to the usual intravaginal torsion, which occurs during puberty.

Intrauterine torsion may present as:

- Patients with a testicular nubbin
- Patients with a small and hard testis
- Patients with a normal-sized and hard testis
- Patients with an acute scrotum.

Torsion occurring in the postnatal period within the first month of life presents with signs of an acute scrotum. The clinical signs correlate well with surgical and histological findings and thus define the need and the urgency to explore the history (56). Doppler ultrasound can be an additional diagnosis tool. The sensitivity for diagnosis of torsion of the testis is high, though the specificity is unknown for neonates. Doppler ultrasound may also be used to exclude congenital testicular neoplasm (57). Neonates with acute scrotal signs as well as bilateral cases should be treated as surgical emergencies (56, 58).

In cases of postnatal torsion, one study reported 40% of testes were salvaged with emergency exploration (59). The contralateral scrotum should also be explored because of the risk of asynchronous contralateral testicular torsion in as many as 33% of cases (58).

5.6. References

1. Varga J, Zivkovic D, Grebeldinger S, Somer D. Acute scrotal pain in children—ten years' experience. *Urol Int* 2007;78(1):73-7.
<http://www.ncbi.nlm.nih.gov/pubmed/17192737>
2. Cavusoglu YH, Karaman A, Karaman I, Erdogan D, Aslan MK, Varlikli O, Cakmak O. Acute scrotum—etiology and management. *Indian J Pediatr* 2005;72(3):201-3.
<http://www.ncbi.nlm.nih.gov/pubmed/15812112>
3. Sakellaris GS, Charissis GC. Acute epididymitis in Greek children: a 3-year retrospective study. *Eur J Pediatr* 2007;5. [Epub ahead of print].
<http://www.ncbi.nlm.nih.gov/pubmed/17786475>

4. Klin B, Zlotkevich L, Horne T, Efrati Y, Serour F, Lotan G. Epididymitis in childhood: a clinical retrospective study over 5 years. *IMAJ* 2001;3:833-35.
<http://www.ima.org.il/imag/dynamic/web/showArt.asp?id=543&nMonth=11&nYear=2001&sCat=Origin&a%201%20Articles&sJur=Vol%203.h>
5. McAndrew HF, Pemberton R, Kikiros CS, Gollow I. The incidence and investigation of acute scrotal problems in children. *Pediatr Surg Int* 2002; 18(5-6): 435-7.
<http://www.ncbi.nlm.nih.gov/pubmed/12415374>
6. Makela E, Lahdes-Vasama T, Rajakorpi H, Wikstrom S. A 19-year review of paediatric patients with acute scrotum. *Scan J Surg* 2007;96(1):62-6.
<http://www.ncbi.nlm.nih.gov/pubmed/17461315>
7. Klin B, Lotan G, Efrati Y, Zlotkevich L, Strauss S. Acute idiopathic scrotal edema in children—revisited. *J Pediatr Surg* 2002;37(8);1200-2.
<http://www.ncbi.nlm.nih.gov/pubmed/12149702>
8. van Langen AM, Gal S, Hulsmann AR, de Nef JJ. Acute idiopathic scrotal oedema: four cases and short review. *Eur J Pediatr* 2001;160(7):455-6.
<http://www.ncbi.nlm.nih.gov/pubmed/11475590>
9. Hara Y, Tajiri T, Matsuura K, Hasegawa A. Acute scrotum caused by Henoch-Schonlein purpura. *Int J Urology* 2004;11(7):578-80.
<http://www.ncbi.nlm.nih.gov/pubmed/15242376>
10. Singh S, Adivarekar P, Karmarkar SJ. Acute scrotum in children: a rare presentation of acute, nonperforated appendicitis. *Pediatr Surg Int* 2003;19(4):298-9.
<http://www.ncbi.nlm.nih.gov/pubmed/12682749>
11. Bingol-Kologlu M, Fedakar M, Yagmurlu A, Dindar H, Gokcora IH. An exceptional complication following appendectomy: acute inguinal and scrotal suppuration. *Int Urol Nephrol* 2006;38(3-4):663-5.
<http://www.ncbi.nlm.nih.gov/pubmed/17160451>
12. Ng KH, Chung YFA, Wilde CC, Chee C. An unusual presentation of acute scrotum after appendicitis. *Singapore Med J* 2002;43(7):365-6.
<http://www.ncbi.nlm.nih.gov/pubmed/12437045>
13. Dayanir YO, Akdilli A, Karaman CZ, Sonmez F, Karaman G. Epididymoorchitis mimicking testicular torsion in Henoch-Schonlein purpura. *Eur Radiol* 2001;11(11):2267-9.
<http://www.ncbi.nlm.nih.gov/pubmed/11702171>
14. Krause W. Is acute idiopathic scrotal edema in children a special feature of neutrophilic eccrine hidradenitis? *Dermatology* 2004;208(1):86.
<http://www.ncbi.nlm.nih.gov/pubmed/14730248>
15. Diamond DA, Borer JG, Peters CA, Cilento BG Jr, Sorcini A, Kaefer M, Paltiel HJ. Neonatal scrotal haematoma: mimicker of neonatal testicular torsion. *BJU Int* 2003; 91:675-7.
<http://www.ncbi.nlm.nih.gov/pubmed/12699483>
16. Vlazakis S, Vlahakis I, Kakavelakis KN, Charissis G. Right acute hemiscrotum caused by insertion of an inflamed appendix. *BJU Int* 2002;89(9):967-8.
<http://www.ncbi.nlm.nih.gov/pubmed/12010250>
17. Ha TS, Lee JS. Scrotal involvement in childhood Henoch-Schonlein purpura. *Acta Paediatr* 2007;96(4):552-5.
<http://www.ncbi.nlm.nih.gov/pubmed/17306010>
18. Myers JB, Lovell MA, Lee RS, Furness PD 3rd, Koyle M. Torsion of an indirect hernia sac causing acute scrotum. *J Pediatr Surg* 2004;39(1):122-3.
<http://www.ncbi.nlm.nih.gov/pubmed/14694389>
19. Matsumoto A, Nagatomi Y, Sakai M, Oshi M. Torsion of the hernia sac within a hydrocele of the scrotum in a child. *Int J Urol* 2004;11(9):789-91.
<http://www.ncbi.nlm.nih.gov/pubmed/15379947>
20. Sauvat F, Hennequin S, Slimane MAA, Gauthier F. [Age for testicular torsion?] *Arch Pediatr* 2002;9(12):1226-9. [article in French]
<http://www.ncbi.nlm.nih.gov/pubmed/12536102>
21. Kadish HA, Bolte RG. A retrospective review of pediatric patients with epididymitis, testicular torsion, and torsion of testicular appendages. *Pediatrics* 1998;102(1 Pt 1):73-6.
<http://www.ncbi.nlm.nih.gov/pubmed/9651416>
22. Somekh E, Gorenstein A, Serour F. Acute epididymitis in boys: evidence of a post-infectious etiology. *J Urol* 2004;171(1):391-4.
<http://www.ncbi.nlm.nih.gov/pubmed/14665940>

23. Nelson CP, Williams JF, Bloom DA. The cremaster reflex: a useful but imperfect sign in testicular torsion. *J Pediatr Surg* 2003; 38(8):1248-9.
<http://www.ncbi.nlm.nih.gov/pubmed/12891505>
24. Mushtaq I, Fung M, Glasson MJ. Retrospective review of pediatric patients with acute scrotum. *ANZ J Surg* 2003;73(1-2):55-8.
<http://www.ncbi.nlm.nih.gov/pubmed/12534742>
25. Murphy FL, Fletcher L, Pease P. Early scrotal exploration in all cases is the investigation and intervention of choice in the acute paediatric scrotum. *Pediatr Surg Int* 2006;22(5):413-6.
<http://www.ncbi.nlm.nih.gov/pubmed/16602024>
26. Baker LA, Sigman D, Mathews RI, Benson J, Docimo SG. An analysis of clinical outcomes using color doppler testicular ultrasound for testicular torsion. *Pediatrics* 2000;105(3 Pt 1):604-7.
<http://www.ncbi.nlm.nih.gov/pubmed/10699116>
27. Schalamon J, Ainoedhofer H, Schleef J, Singer G, Haxhija EQ, Hollwarth ME. Management of acute scrotum in children—the impact of Doppler ultrasound. *J Pediatr Surg* 2006;41(8):1377-80.
<http://www.ncbi.nlm.nih.gov/pubmed/16863840>
28. Gunther P, Schenk JP, Wunsch R, Holland-Cunz S, Kessler U, Troger J Waag KL. Acute testicular torsion in children: the role of sonography in the diagnostic workup. *Eur Radiol* 2006;16(11):2527-32.
<http://www.ncbi.nlm.nih.gov/pubmed/16724203>
29. Kalfa N, Veyrac C, Lopez M, Lopez C, Maurel A, Kaselas C, Sibai S, Arena F, Vaos G, Breaud J, Merrot T, Kalfa D, Khochman I, Mironescu A, Minaev S, Averous M, Galifer RB. Multicenter assessment of ultrasound of the spermatic cord in children with acute scrotum. *J Urol* 2007;177(1):297-301.
<http://www.ncbi.nlm.nih.gov/pubmed/17162068>
30. Karmazyn B, Steinberg R, Kornreich L, Freud E, Grozovski S, Schwarz M, Ziv N, Livne P. Clinical and sonographic criteria of acute scrotum in children: a retrospective study of 172 boys. *Pediatr Radiol* 2005(3);35:302-10.
<http://www.ncbi.nlm.nih.gov/pubmed/15503003>
31. Lam WW, Yap TL, Jacobsen AS, Teo HJ. Colour Doppler ultrasonography replacing surgical exploration for acute scrotum: myth or reality? *Pediatr Radiol* 2005;35(6):597-600.
<http://www.ncbi.nlm.nih.gov/pubmed/15761770>
32. Pepe P, Panella P, Pennisi M, Aragona F. Does color Doppler sonography improve the clinical assessment of patients with acute scrotum? *Eur J Radiol* 2006;60(1):120-4.
<http://www.ncbi.nlm.nih.gov/pubmed/16730939>
33. Kalfa N, Veyrac C, Baud C, Couture A, Averous M, Galifer RB. Ultrasonography of the spermatic cord in children with testicular torsion: impact on the surgical strategy. *J Urol* 2004;172(4 Pt 2):1692-5.
<http://www.ncbi.nlm.nih.gov/pubmed/15371792>
34. Yuan Z, Luo Q, Chen L, Zhu J, Zhu R. Clinical study of scrotum scintigraphy in 49 patients with acute scrotal pain: a comparison with ultrasonography. *Ann Nucl Med* 2001;15(3):225-9.
<http://www.ncbi.nlm.nih.gov/pubmed/11545192>
35. Nussbaum Blask, Bulas D, Shalaby-Rana E, Rushton G, Shao C, Majd M. Color Doppler sonography and scintigraphy of the testis: a prospective, comparative analysis in children with acute scrotal pain. *Pediatr Emerg Care* 2002;18(2):67-71.
<http://www.ncbi.nlm.nih.gov/pubmed/11973493>
36. Paltiel HJ, Connolly LP, Atala A, Altie AD, Zurakowski D, Treves ST. Acute scrotal symptoms in boys with an indeterminate clinical presentation: comparison of color Doppler sonography and scintigraphy. *Radiology* 1998;207:223-31.
<http://radiology.rsnajnl.org/cgi/content/abstract/207/1/223>
37. Terai A, Yoshimura K, Ichioka K, Ueda N, Utsunomiya N, Kohei N, Arai Y, Watanabe Y. Dynamic contrast-enhanced subtraction magnetic resonance imaging in diagnostics of testicular torsion. *Urology* 2006;67(6):1278-82.
<http://www.ncbi.nlm.nih.gov/pubmed/16765192>
38. Karmazyn B, Steinberg R, Livne P, Kornreich L, Grozovski S, Schwarz M, Nitza Z, Freud E. Duplex sonographic findings in children with torsion of the testicular appendages: overlap with epididymitis and epididymoorchitis. *J Pediatr Surg* 2006;41(3):500-4.
<http://www.ncbi.nlm.nih.gov/pubmed/16516624>
39. Lau P, Anderson PA, Giacomantonio JM, Schwarz RD. Acute epididymitis in boys: are antibiotics indicated? *Br J Urol* 1997;79(5):797-800.
<http://www.ncbi.nlm.nih.gov/pubmed/9158522>

40. Abul F, Al-Sayer H, Arun N. The acute scrotum: a review of 40 cases. *Med Princ Pract* 2005;14(3): 177-81.
<http://www.ncbi.nlm.nih.gov/pubmed/15863992>
41. Cornel EB, Karthaus HF. Manual derotation of the twisted spermatic cord. *BJU Int* 1999;83(6): 672-4.
<http://www.ncbi.nlm.nih.gov/pubmed/10233577>
42. Garel L, Dubois J, Azzie G, Filiatrault D, Grignon A, Yazbeck S. Preoperative manual detorsion of the spermatic cord with Doppler ultrasound monitoring in patients with intravaginal acute testicular torsion. *Pediatr Radiol* 2000;30(1):41-4.
<http://www.ncbi.nlm.nih.gov/pubmed/10663509>
43. Sessions AE, Rabinowitz R, Hulbert WC, Goldstein MM, Mevorach RA. Testicular torsion: direction, degree, duration and disinfection. *J Urol* 2003;169(2):663-5.
<http://www.ncbi.nlm.nih.gov/pubmed/12544339>
44. Visser AJ, Heyns CF. Testicular function after torsion of the spermatic cord. *BJU Int* 2003;92(3):200-3.
<http://www.ncbi.nlm.nih.gov/pubmed/12887467>
45. Tryfonas G, Violaki A, Tsikopoulos G, Avtzioglou P, Zioutis J, Limas C, Gregoriadis G, Badouraki M. Late postoperative results in males treated for testicular torsion during childhood. *J Pediatr Surg* 1994;29(4):553-6.
<http://www.ncbi.nlm.nih.gov/pubmed/8014814>
46. Anderson MJ, Dunn JK, Lishultz LI, Coburn M. Semen quality and endocrine parameters after acute testicular torsion. *J Urol* 1992;147(6):1545-50.
<http://www.ncbi.nlm.nih.gov/pubmed/1593686>
47. Arap MA, Vicentini FC, Cocuzza M, Hallak J, Athayde K, Lucon AM, Arap S, Srougi M. Late hormonal levels, semen parameters, and presence of antisperm antibodies in patients treated for testicular torsion. *J Androl* 2007;28(4):528-32.
<http://www.ncbi.nlm.nih.gov/pubmed/17287456>
48. Mor Y, Pinthus JH, Nadu A, Raviv G, Golomb J, Winkler H, Ramon J. Testicular fixation following torsion of the spermatic cord- does it guarantee prevention of recurrent torsion events? *J Urol* 2006;175(1):171-4.
<http://www.ncbi.nlm.nih.gov/pubmed/16406900>
49. Haj M, Shasha SM, Loberant N, Farhadian H. Effect of external scrotal cooling on the viability of the testis with torsion in rats. *Eur Surg Res* 2007;39(3):160-9.
<http://www.ncbi.nlm.nih.gov/pubmed/17341878>
50. Aksoy H, Yapanoglu T, Aksoy Y, Ozbey I, Turhan H, Gursan N. Dehydroepiandrosterone treatment attenuates reperfusion injury after testicular torsion and detorsion in rats. *J Pediatr Surg* 2007;42(10):1740-4.
<http://www.ncbi.nlm.nih.gov/pubmed/17923206>
51. Akcora B, Altug ME, Kontas T, Atik E. The protective effect of darbepoetin alfa on experimental testicular torsion and detorsion injury. *Int J Urol* 2007;14(9):846-50.
<http://www.ncbi.nlm.nih.gov/pubmed/17760753>
52. Yazihan N, Ataoglu H, Koku N, Erdemli E, Sargin AK. Protective role of erythropoietin during testicular torsion of the rats. *World J Urol* 2007;25(5):531-6.
<http://www.ncbi.nlm.nih.gov/pubmed/17690891>
53. Unal D, Karatas OF, Savas M, Yeni E, Keser BS, Verit A, Erel O, Bitiren M. Protective effects of trimetazidine on testicular ischemia-reperfusion injury in rats. *Urol Int* 2007;78(4):356-62.
<http://www.ncbi.nlm.nih.gov/pubmed/17495496>
54. Dokmeci D, Kanter M, Inan M, Aydogdu N, Basaran UN, Yalcin O, Turan FN. Protective effects of ibuprofen on testicular torsion/detorsion-induced ischemia/reperfusion injury in rats. *Arch Toxicol* 2007;81(9):655-63.
<http://www.ncbi.nlm.nih.gov/pubmed/17345063>
55. Turner TT, Bang HJ, Lysiak JJ. Experimental testicular torsion: reperfusion blood flow and subsequent testicular venous plasma testosterone concentration. *Urology* 2005;65(2):390-4.
<http://www.ncbi.nlm.nih.gov/pubmed/15708073>
54. Ozkan MH, Vural IM, Moralioglu S, Uma S, Sarioglu Y. Torsion/detorsion of the testis does not modify responses to nitric oxide in rat isolated penile bulb. *Basic Clin Pharmacol Toxicol* 2007;101(2):117-20.
<http://www.ncbi.nlm.nih.gov/pubmed/17651313>
55. Yerkes EB, Robertson FM, Gitlin J, Kaefer M, Cain M, Rink RC. Management of perinatal torsion: today, tomorrow or never? *J Urol* 2005;174(4 Pt 2): 1579-83.
<http://www.ncbi.nlm.nih.gov/pubmed/16148656>

56. Cuervo JL, Grillo A, Vecchiarelli C, Osio C, Prudent L. Perinatal testicular torsion: a unique strategy. *J Pediatr Surg* 2007;42:699-703.
<http://www.ncbi.nlm.nih.gov/pubmed/17448769>
57. van der Sluijs JW, den Hollander JC, Lequin MH, Nijman RM, Robben SG. Prenatal testicular torsion: diagnosis and natural course. An ultrasonographic study. *Eur Radiol* 2004;14(2):250-5.
<http://www.ncbi.nlm.nih.gov/pubmed/12955451>
58. Baglaj M, Carachi R. Neonatal bilateral testicular torsion: a plea for emergency exploration. *J Urol* 2007;177(6):2296-9.
<http://www.ncbi.nlm.nih.gov/pubmed/17509343>
59. Sorensen MD, Galansky SH, Striegl AM, Mevorach R, Koyle MA. Perinatal extravaginal torsion of the testis in the first month of life is a salvageable event. *Urology* 2003;62(1):132-4.
<http://www.ncbi.nlm.nih.gov/pubmed/12837441>

6. HYPOSPADIAS

6.1 Background

Hypospadias can be defined as hypoplasia of the tissues forming the ventral aspect of the penis beyond the division of the corpus spongiosum. Hypospadias are usually classified based on the anatomical location of the proximally displaced urethral orifice:

- Distal-anterior hypospadias (located on the glans or distal shaft of the penis and the most common type of hypospadias)
- Intermediate-middle (penile)
- Proximal-posterior (penoscrotal, scrotal, perineal).
The pathology may be much more severe after skin release.

6.1.1 Risk factors

Risk factors associated with hypospadias are likely to be genetic, placental and/or environmental (1) (Level of evidence: 2b):

- Endocrine disorders can be detected in a very few cases.
- Babies of young or old mothers and babies with a low birth weight have a higher risk of hypospadias.
- A significant increase in the incidence of hypospadias over the last 20 years suggests a role for environmental factors (hormonal disruptors and pesticides) (2-5).

The use of oral contraceptives prior to pregnancy has not been associated with an increased risk of hypospadias in the offspring (6) (Level of evidence: 2a; Grade of recommendation; B).

6.2 Diagnosis

Patients with hypospadias should be diagnosed at birth (except for the megameatus intact prepuce variant).

Diagnosis includes a description of the local findings:

- Position, shape and width of the orifice
- Presence of atretic urethra and division of corpus spongiosum
- Appearance of the preputial hood and scrotum
- Size of the penis
- Curvature of the penis on erection.

The diagnostic evaluation also includes an assessment of associated anomalies, which are:

- Cryptorchidism (in up to 10% of cases of hypospadias)
- Open processus vaginalis or inguinal hernia (in 9-15%).

Severe hypospadias with unilaterally or bilaterally impalpable testis, or with ambiguous genitalia, require a complete genetic and endocrine work-up immediately after birth to exclude intersexuality, especially congenital adrenal hyperplasia.

Urine trickling and ballooning of the urethra requires exclusion of meatal stenosis.

The incidence of anomalies of the upper urinary tract does not differ from the general population, except in very severe forms of hypospadias (2, 3).

6.3 Treatment

Differentiation between functionally necessary and aesthetically feasible operative procedures is important for therapeutic decision-making.

The functional indications for surgery are:

- Proximally located meatus
- Ventrally deflected urinary stream
- Meatal stenosis
- Curved penis.

The cosmetic indications, which are strongly linked to the psychology of the parent or future patient's psychology, are:

- Abnormally located meatus
- Cleft glans
- Rotated penis with abnormal cutaneous raphe
- Preputial hood
- Penoscrotal transposition
- Split scrotum.

As all surgical procedures carry the risk of complications, thorough pre-operative counselling of the parents is crucial.

The therapeutic objectives are to correct the penile curvature, to form a neo-urethra of an adequate size, to bring the neomeatus to the tip of the glans, if possible, and to achieve an overall acceptable cosmetic appearance of the boy's genitalia (2,3) (Level of evidence: 4; Grade of recommendation; C) (Figure 1).

The use of magnifying spectacles and special fine synthetic absorbable suture materials (6/0-7/0) is required. As in any penile surgery, an exceptional prudence should be adopted with the use of cautery. Knowledge of a variety of surgical reconstructive techniques, wound care and post-operative treatment are essential for a satisfactory outcome. Pre-operative hormonal treatment with local or parenteral application of testosterone, dihydrotestosterone or beta-chorionic gonadotropin can be helpful in patients with a small penis or for repeat surgery.

6.3.1 *Age at surgery*

The age at surgery for primary hypospadias repair is usually 6-18 (7) months (2) (Level of evidence: 4; Grade of recommendation; C). However, earlier repair between 4 and 6 months of age has been reported recently (Level of evidence: 3; Grade of recommendation; B) (8).

6.3.2 *Penile curvature*

If present, penile curvature is often released by degloving the penis (skin chordee) and by excision of the connective tissue of the genuine chordee on the ventral aspect of the penis. The urethral plate has well-vascularized connective tissue and does not cause curvature in most cases. The residual chordee (curvature) is caused by corporeal disproportion and requires straightening of the penis, mostly using dorsal orthoplasty (modification of Nesbit dorsal corporeal plication) (9) (Level of evidence: 3; Grade of recommendation; B).

6.3.3 *Preservation of the well-vascularized urethral plate*

The mainstay of hypospadias repair is preservation of the well-vascularized urethral plate and its use for urethral reconstruction has become the mainstay of hypospadias repair (10).

If the urethral plate is wide, it can be tubularized following the Thiersch-Duplay technique. If the plate is too narrow to be simply tubularized, it is recommended that a midline-relaxing incision of the plate, followed by reconstruction according to the Snodgrass-Orkiszewski technique, is performed in distal hypospadias, as well as in proximal hypospadias (though the complication rate is higher) (7, 11-15).

The onlay technique is preferred in proximal hypospadias and in cases of a plate that is unhealthy or too narrow. For distal forms of hypospadias, a range of other techniques is available (e.g. Mathieu, urethral advancement, etc) (12, 16) (Level of evidence: 2b; Grade of recommendation; B).

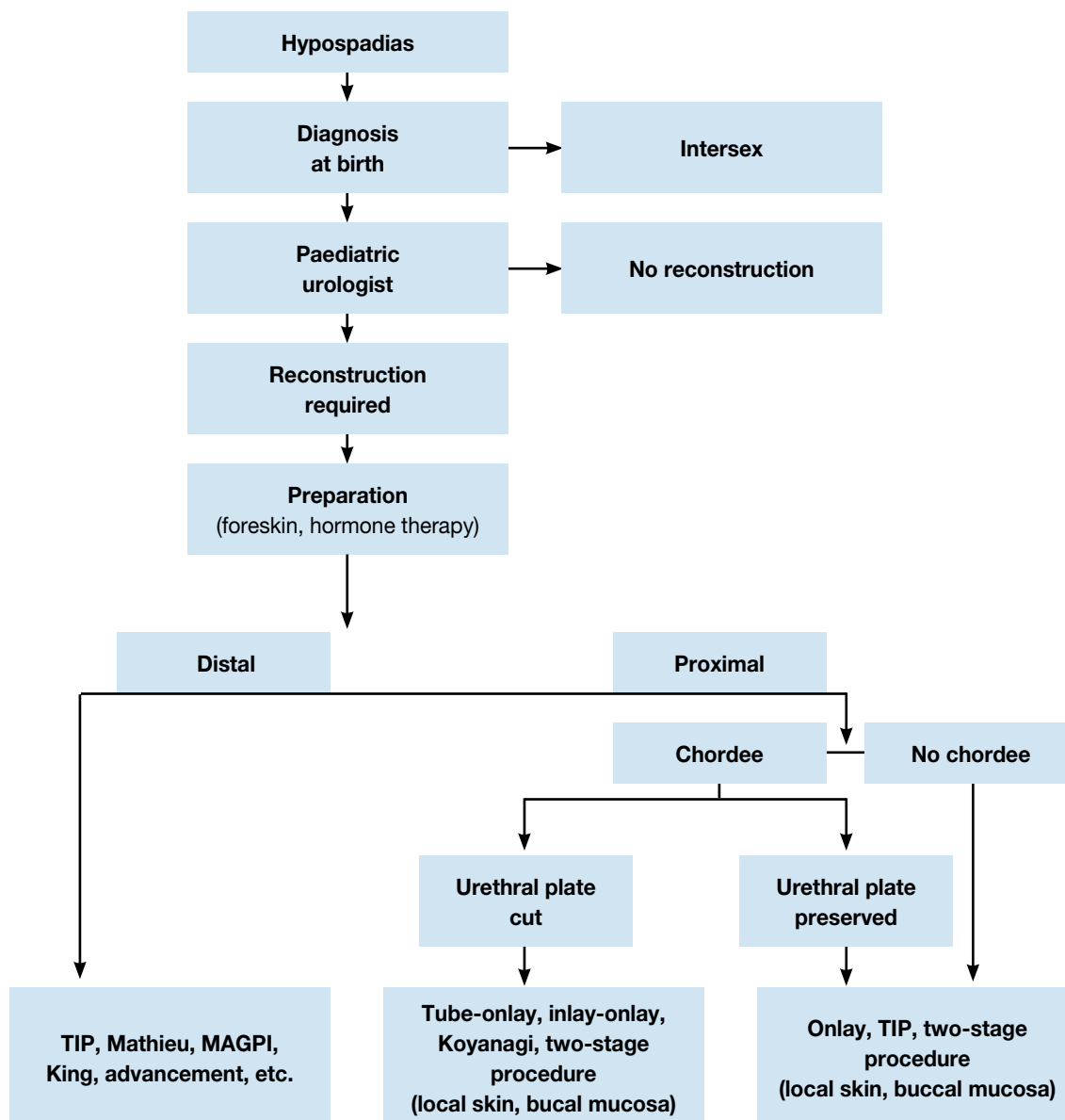
If the continuity of the urethral plate cannot be preserved, a modification of the tubularized flap, such as a tube-onlay or an inlay-onlay flap, is used to prevent urethral stricture (17, 18) (Level of evidence: 3; Grade of recommendation; C). In this situation, as well as in severe scrotal or penoscrotal hypospadias, the Koyanagi technique or two-stage procedure may be an option (19-21).

If preputial or penile skin is not available, or has signs of balanitis xerotica obliterans, a buccal mucosa graft is used in an onlay or two-stage repair (22-25) (Level of evidence: 3; Grade of recommendation; C). The use of inlay skin grafts may allow an increased number of single-stage repairs to be performed (26, 27).

6.3.4 *Re-do hypospadias repairs*

For re-do hypospadias repairs, no definitive guidelines can be given. All the above-mentioned procedures are used in different ways and are often modified according to the individual needs of the patient.

Figure 1: Algorithm for the management of hypospadias



TIP = tubularized incised plate urethroplasty; MAGPI = meatal advancement and granuloplasty.

6.3.5 Urethral reconstruction

Following formation of the neo-urethra, the procedure is completed by glansplasty and by reconstruction of the penile skin. If there is a shortage of skin covering, the preputial double-face technique or placement of the suture line into the scrotum may be used. In countries where circumcision is not routinely performed, preputial reconstruction can be considered. However, in the TIP repair, the parents should be advised that use of a preputial dartos flap reduces the fistula rate (11) (Level of evidence: 2; Grade of recommendation: B).

6.3.6 Urine drainage and wound dressing

Urine is drained with a transurethral dripping stent, or with a suprapubic tube. Some surgeons use no drainage after distal hypospadias repair. Circular dressing with slight compression, as well as prophylactic antibiotics, are established procedures.

A large variety of duration of stenting and dressing is described. No recommendation can be given due to the low level of evidence.

6.3.7 Outcome

Adolescents, who have undergone hypospadias repair in childhood, have a slightly higher rate of dissatisfaction with penile size, but their sexual behaviour is not different from that in control subjects (28) (Level of evidence: 2a).

6.4 References

1. Morera A, Valmalle A, Asensio M, Chossegros L, Chauvin M, Durand P, Mouriquand P. A study of risk factors for hypospadias in the Rhône-Alpes region (France). *J Ped Urol* 2006;2(3):169-77.
<http://www.ncbi.nlm.nih.gov/pubmed/18947603>
2. Belman AB. Hypospadias and chordee. In: Belman AB, King LR, Kramer SA, eds. *Clinical Pediatric Urology*. 4th edn. London, Martin Dunitz, 2002, pp. 1061-1092.
3. Mouriquand OD, Mure PY. Hypospadias. In: Gearhart J, Rink R, Mouriquand PDE, eds. *Pediatric Urology*, Philadelphia, WB Saunders, 2001, pp. 713-728.
4. Wang Z, Liu BC, Lin GT, Lin CS, Lue TF, Willingham E, Baskin LS. Up-regulation of estrogen responsive genes in hypospadias: microarray analysis. *J Urol* 2007;177(5):1939-46.
<http://www.ncbi.nlm.nih.gov/pubmed/17437852>
5. Weidner IS, Moller H, Jensen TK, Skakkebaek NE. Risk factors for cryptorchidism and hypospadias. *J Urol* 1999;161(5):1606-9.
<http://www.ncbi.nlm.nih.gov/pubmed/10210427>
6. Wogelius P, Horvath-Puho E, Pedersen L, Norgaard M, Czeizel AE, Sorensen HT. Maternal use of oral contraceptives and risk of hypospadias—a population-based case-control study. *Eur J Epidemiol* 2006;21(10):777-81.
<http://www.ncbi.nlm.nih.gov/pubmed/17077991>
7. Snodgrass WT, Yucel S. Tubularized incised plate for mid shaft and proximal hypospadias repair. *J Urol* 2007;177(2):698-702.
<http://www.ncbi.nlm.nih.gov/pubmed/17222659>
8. Perlmutter AE, Morabito R, Tarry WF. Impact of patient age on distal hypospadias repair: a surgical perspective. *Urology* 2006;68(3):648-51.
<http://www.ncbi.nlm.nih.gov/pubmed/16979730>
9. Baskin LS, Duckett JW, Ueoka K, Seibold J, Snyder HM 3rd. Changing concepts of hypospadias curvature lead to more onlay island flap procedures. *J Urol* 1994;151(1):191-6.
<http://www.ncbi.nlm.nih.gov/pubmed/8254812>
10. Hollowell JG, Keating MA, Snyder HM 3rd, Duckett JW. Preservation of the urethral plate in hypospadias repair: extended applications and further experience with the onlay island flap urethroplasty. *J Urol* 1990;143(1): 98-100; discussion 100-1.
<http://www.ncbi.nlm.nih.gov/pubmed/2294275>
11. El-Sherbiny MT, Hafez AT, Dawaba MS, Shorrah AA, Bazeed MA. Comprehensive analysis of tubularized incised-plate urethroplasty in primary and re-operative hypospadias. *BJU Int* 2004;93(7):1057-61.
<http://www.ncbi.nlm.nih.gov/pubmed/15142164>
12. Germiyanoglu C, Nuhoglu B, Ayyildiz A, Akgul KT. Investigation of factors affecting result of distal hypospadias repair: comparison of two techniques. *Urology* 2006;68(1):182-5.
<http://www.ncbi.nlm.nih.gov/pubmed/16806428>
13. Orkiszewski M, Leszniewski J. Morphology and urodynamics after longitudinal urethral plate incision in proximal hypospadias repairs: long-term results. *Eur J Pediatr Surg* 2004;14(1):35-8.
<http://www.ncbi.nlm.nih.gov/pubmed/15024677>
14. Riccabona M, Oswald J, Koen M, Beckers G, Schrey A, Lusuardi L. Comprehensive analysis of six years experience in tubularized incised plate urethroplasty and its extended application in primary and secondary hypospadias repair. *Eur Urol* 2003;44(6):714-9.
<http://www.ncbi.nlm.nih.gov/pubmed/14644125>
15. Snodgrass W, Koyle M, Manzoni G, Hurwitz R, Caldamone A, Ehrlich R. Tubularized incised plate hypospadias repair: results of a multicenter experience. *J Urol* 1996;156(2 Pt 2):839-41.
<http://www.ncbi.nlm.nih.gov/pubmed/8683797>
16. Meyer-Junghanel L, Petersen C, Mildenerger H. Experience with repair of 120 hypospadias using Mathieu's procedure. *Eur J Pediatr Surg* 1995;5(6):355-7.
<http://www.ncbi.nlm.nih.gov/pubmed/8773227>
17. Kocvara R, Dvoracek J. Inlay-onlay flap urethroplasty for hypospadias and urethral stricture repair. *J Urol* 1997;158(6):2142-5.
<http://www.ncbi.nlm.nih.gov/pubmed/9366331>
18. Perovic S, Vukadinovic V. Onlay island flap urethroplasty for severe hypospadias: a variant of the technique. *J Urol* 1994;151(3):711-4.
<http://www.ncbi.nlm.nih.gov/pubmed/8308994>
19. Bracka A. Hypospadias repair: the two-stage alternative. *Br J Urol* 1995;76 (Suppl 3):31-41.
<http://www.ncbi.nlm.nih.gov/pubmed/8535768>

20. Hayashi Y, Kojima Y, Mizuno K, Nakane A, Kurokawa S, Maruyama T, Kohri K. Neo-modified Koyanagi technique for the single-stage repair of proximal hypospadias. *J Ped Urol* 2007;3(3):239-42.
<http://www.ncbi.nlm.nih.gov/pubmed/18947743>
21. Lam P.N., Greenfield S.P., Williot P. 2-stage repair in infancy for severe hypospadias with chordee: long-term results after puberty. *J Urol* 2005;174(4 Pt 2):1567-72.
<http://www.ncbi.nlm.nih.gov/pubmed/16148653>
22. Ahmed S, Gough DC. Buccal mucosal graft for secondary hypospadias repair and urethral replacement. *Br J Urol* 1997;80(2):328-30.
<http://www.ncbi.nlm.nih.gov/pubmed/9284210>
23. Amukele SA, Stock JA, Hanna MK. Management and outcome of complex hypospadias repairs. *J Urol* 2005;174(4 Pt 2):1540-2.
<http://www.ncbi.nlm.nih.gov/pubmed/16148648>
24. Caldamone AA, Edstrom LE, Koyle MA, Rabinowitz R, Hulbert WC. Buccal mucosal grafts for urethral reconstruction. *Urology* 1998;51(5A Suppl):15-9.
<http://www.ncbi.nlm.nih.gov/pubmed/9610551>
25. Mokhless IA, Kader MA, Fahmy N, Youssef M. The multistage use of buccal mucosa grafts for complex hypospadias: histological changes. *J Urol* 2007;177(4):1496-9; discussion 1499-500.
<http://www.ncbi.nlm.nih.gov/pubmed/17382762>
26. Asanuma H, Satoh H, Shishido S. Dorsal inlay graft urethroplasty for primary hypospadiac repair. *Int J Urol* 2007;14(1):43-7.
<http://www.ncbi.nlm.nih.gov/pubmed/17199859>
27. Schwentner C, Gozzi C, Lunacek A, Rehder P, Bartsch G, Oswald J, Radmayr C. Interim outcome of the single stage dorsal inlay skin graft for complex hypospadias reoperations. *J Urol* 2006;175(5):1872-1876; discussion 1876-7.
<http://www.ncbi.nlm.nih.gov/pubmed/16600785>
28. Moriya K, Kakizaki H, Tanaka H, Furuno T, Higashiyama H, Sano H, Kitta T, Nonomura K. Long-term cosmetic and sexual outcome of hypospadias surgery: norm related study in adolescence. *J Urol* 2006;176(4 Pt 2):1889-92; discussion 1892-3.
<http://www.ncbi.nlm.nih.gov/pubmed/16945681>

7. CONGENITAL PENILE CURVATURE

7.1 Background

Penile curvature may be ventral, dorsal or lateral. Most of ventral curvatures are associated with hypospadias due to chordee or ventral dysplasia of cavernous bodies (1). Similarly, the dorsal curvature is mostly associated with epispadias (2). Isolated penile curvature is not frequent with an incidence of 0.6 % (3) (Level of evidence: 2). The curvature is caused by asymmetry of the cavernous bodies (1, 4).

Curvature over 30 degrees is considered clinically significant; curvature over 60 degrees may interfere with satisfactory sexual intercourse in adulthood (5) (Level of evidence: 4).

7.2 Diagnosis

Diagnosis is made during hypospadias or epispadias repair using an artificial erection (6). The isolated anomaly is usually not recognized until later in childhood because the appearance of the penis is normal. The curvature is only observed during erections.

7.3 Treatment

The treatment is surgical. An artificial erection is used to determine the degree of curvature and to check the symmetry after the repair (6).

In hypospadias, chordee related to the tethering of the ventral skin and to the spongiosal pillars is first released. Only in a few cases the penile curvature is caused by a short urethral plate, which should be cut.

To repair the corporeal angulation in the isolated curvature or curvature associated with hypospadias, different techniques of plication of corpora cavernosa (orthoplasty) are used (5).

In epispadias, a combination of complete release of the urethral body from the corpora and a different kind of corporoplasty with or without corporotomy is usually necessary to achieve a straight penis (7, 8).

7.4 REFERENCES

1. Baskin LS, Duckett JW, Lue TF. Penile curvature. *Urology* 1996;48(3):347-56.
<http://www.ncbi.nlm.nih.gov/pubmed/8804484>
2. Baka-Jakubiak M. Combined bladder neck, urethral and penile reconstruction in boys with the exstrophy-epispadias complex. *BJU Int* 2000;86(4):513-8.
<http://www.ncbi.nlm.nih.gov/pubmed/10971283>
3. Yachia D, Beyar M, Aridogan IA, Dascalu S. The incidence of congenital penile curvature. *J Uro* 1993;150(5 Pt 1):1478-9.
<http://www.ncbi.nlm.nih.gov/pubmed/8411431>
4. Cendron M. Disorders of the penis and scrotum. In: Gearhart JP, Rink RC, Mouriquand PDE, eds. *Pediatric urology*. Philadelphia: WB Saunders, Philadelphia, 2001, pp. 729-37
5. Ebbelohj J, Metz P. Congenital penile angulation. *BJU Int* 1987;60(3):264-6.
<http://www.ncbi.nlm.nih.gov/pubmed/3676675>
6. Gittes RF, McLaughlin AP 3rd. Injection technique to induce penile erection. *Urology* 1974;4(4):473-4.
<http://www.ncbi.nlm.nih.gov/pubmed/4418594>
7. Woodhouse CRJ. The genitalia in exstrophy and epispadias. In: Gearhart JP, Rink RC, Mouriquand PDE, eds. *Pediatric urology*. Philadelphia: WB Saunders 2001, pp. 557-64.
8. Zaontz MR, Steckler RE, Shortliffe LM, Kogan BA, Baskin L, Tekgul S. Multicenter experience with the Mitchell technique for epispadias repair. *J Urol* 1998;160(1):172-6.
<http://www.ncbi.nlm.nih.gov/pubmed/9628644>

8. VARICOCELE IN CHILDREN AND ADOLESCENTS

8.1 Background

Varicocele is defined as an abnormal dilatation of testicular veins in the pampiniformis plexus caused by venous reflux. It is unusual in boys under 10 years of age and becomes more frequent at the beginning of puberty. It is found in 15-20% of adolescents, with a similar incidence during adulthood. It appears mostly on the left side (78-93% of cases). Right-sided varicoceles are least common; they are usually noted only when bilateral varicoceles are present and seldom occur as an isolated finding (1, 2).

Varicocele develops during accelerated body growth by a mechanism that is not clearly understood. Varicocele can induce apoptotic pathways because of heat stress, androgen deprivation and accumulation of toxic materials. Severe damage is found in 20% of adolescents affected, with abnormal findings in 46% of affected adolescents. Histological findings are similar in children or adolescents and in infertile men. In 70% of patients with grade II and III varicocele, left testicular volume loss was found. However, studies correlating a hypoplastic testicle with poor sperm quality have reported controversial results (3, 4).

Several authors reported on reversal of testicular growth after varicocelectomy in adolescents (level of evidence: 2) (5, 6). However, this may partly be attributable to testicular oedema associated with the division of lymphatic vessels (Level of evidence: 2) (7).

In about 20% of adolescents with varicocele, fertility problems will arise (8). The adverse influence of varicocele increases with time. Improvement in sperm parameters has been demonstrated after adolescent varicocelectomy (Level of evidence: 1) (3, 9).

8.2 Diagnosis

Varicocele is mostly asymptomatic, rarely causing pain at this age. It may be noticed by the patient or parents, or discovered by the paediatrician at a routine visit. The diagnosis depends upon the clinical finding of a collection of dilated and tortuous veins in the upright posture; the veins are more pronounced when the patient performs the Valsalva manoeuvre.

Varicocele is classified into 3 grades: Grade I - Valsalva positive (palpable at Valsalva manoeuvre only); Grade II - palpable (palpable without the Valsalva manoeuvre); Grade III - visible (visible at distance) (10). The size of both testicles should be evaluated during palpation to detect a smaller testis.

Venous reflux into the plexus pampiniformis is diagnosed using Doppler colour flow mapping in the supine and upright position (11). Venous reflux detected on ultrasound only is classified as subclinical varicocele. The ultrasound examination includes assessment of the testicular volume to discriminate testicular hypoplasia. In adolescents, a testis that is smaller by more than 2 mL compared to the other testis is considered to be hypoplastic (Level of evidence: 4) (1).

In order to assess testicular injury in adolescents with varicocele, supranormal follicle-stimulating hormone (FSH) and luteinizing hormone (LH) responses to the luteinizing hormone-releasing hormone (LHRH) stimulation test are considered reliable, as histopathological testicular changes have been found in these patients (9, 12).

8.3 Therapy

Surgical intervention is based on ligation or occlusion of the internal spermatic veins. Ligation is performed at different levels:

- inguinal (or subinguinal) microsurgical ligation
- suprainguinal ligation, using open or laparoscopic techniques (13-16).

The advantage of the former is the lower invasiveness of the procedure, while the advantage of the latter is a considerably lower number of veins to be ligated and safety of the incidental division of the internal spermatic artery at the suprainguinal level.

For surgical ligation, some form of optical magnification (microscopic or laparoscopic magnification) should be used because the internal spermatic artery is 0.5 mm in diameter at the level of the internal ring (13-15,17). The recurrence rate is usually less than 10%. Angiographic occlusion is based on retrograde or antegrade sclerotization of the internal spermatic veins (18, 19).

Lymphatic-sparing varicocelectomy is preferred to prevent hydrocele formation and testicular hypertrophy development and to achieve a better testicular function according to the LHRH stimulation test (Level of evidence: 2; Grade of recommendation: A) (7, 13, 16, 17, 20). The methods of choice are subinguinal or inguinal microsurgical (microscopic) repairs, or suprainguinal open or laparoscopic lymphatic-sparing repairs.

Angiographic occlusion of the internal spermatic veins also meets these requirements. However, although this method is less invasive, it appears to have a higher failure rate (Level of evidence: 2; Grade of recommendation: B) (1, 19).

There is no evidence that treatment of varicocele at paediatric age will offer a better andrological outcome than an operation performed later. The recommended indication criteria for varicocelectomy in children and adolescents are (1, 21):

- varicocele associated with a small testis
- additional testicular condition affecting fertility
- bilateral palpable varicocele
- pathological sperm quality (in older adolescents)
- varicocele associated with a supranormal response to LHRH stimulation test
- symptomatic varicocele.

Repair of a large varicocele physically or psychologically causing discomfort may be also considered. Other varicoceles should be followed-up until a reliable sperm analysis can be performed (Level of evidence: 4; Grade of recommendation: C).

8.4 REFERENCES

1. Kogan SJ. The pediatric varicocele. In: Gearhart JP, Rink RC, Mouriquand PDE, eds. Pediatric urology. Philadelphia: WB Saunders, 2001, pp. 763-773.
2. Oster J. Varicocele in children and adolescents. An investigation of the incidence among Danish school children. *Scand J Urol Nephrol*;1971;5(1):27-32.
<http://www.ncbi.nlm.nih.gov/pubmed/5093090>
3. Laven JS, Haans LC, Mali WP, te Velde ER, Wensing CJ, Eimers JM. Effects of varicocele treatment in adolescents: a randomized study. *Fertil Steril* 1992;58(4):756-62.
<http://www.ncbi.nlm.nih.gov/pubmed/1426322>
4. Pinto KJ, Kroovand RL, Jarow JP. Varicocele related testicular atrophy and its predictive effect upon fertility. *J Urol* 1994;152(2 Pt 2):788-90.
<http://www.ncbi.nlm.nih.gov/pubmed/8022015>
5. Kass EJ, Belman AB. Reversal of testicular growth failure by varicocele ligation. *J Urol* 1987;137(3):475-6.
<http://www.ncbi.nlm.nih.gov/pubmed/3820376>
6. Paduch DA, Niedzielski J. Repair versus observation in adolescent varicocele: a prospective study. *J Urol* 1997;158(3 Pt 2):1128-32.
<http://www.ncbi.nlm.nih.gov/pubmed/9258155>
7. Kocvara R, Dolezal J, Hampl R, Povysil C, Dvoracek J, Hill M, Dite Z, Stanek Z, Novak K. Division of lymphatic vessels at varicocelectomy leads to testicular oedema and decline in testicular function according to the LH-RH analogue stimulation test. *Eur Urol* 2003;43(4):430-5.
<http://www.ncbi.nlm.nih.gov/pubmed/12667726>

8. World Health Organization. The influence of varicocele on parameters of fertility in a large group of men presenting to infertility clinics. *Fertil Steril* 1992;57(6):1289-93.
<http://www.ncbi.nlm.nih.gov/pubmed/1601152>
9. Okuyama A, Nakamura M, Namiki M, Takeyama M, Utsunomiya M, Fujioka H, Itatani H, Matsuda M, Matsumoto K, Sdonoda T. Surgical repair of varicocele at puberty: preventive treatment for fertility improvement. *J Urol* 1988;139(3):562-4.
<http://www.ncbi.nlm.nih.gov/pubmed/3343743>
10. Dubin L, Amelar RD. Varicocele size and results of varicocelectomy in selected subfertile men with a varicocele. *Fertil Steril* 1970;21(8):606-9.
<http://www.ncbi.nlm.nih.gov/pubmed/5433164>
11. Tasci AI, Resim S, Caskurlu T, Dincel C, Bayraktar Z, Gurbuz G. Color Doppler ultrasonography and spectral analysis of venous flow in diagnosis of varicocele. *Eur Urol* 2001;39(3):316-21.
<http://www.ncbi.nlm.nih.gov/pubmed/11275726>
12. Aragona F, Ragazzi R, Pozzan GB, De Caro R, Munari PF, Milani C, Glazel GP. Correlation of testicular volume, histology and LHRH test in adolescents with idiopathic varicocele. *Eur Urol* 1994;26(1):61-6.
<http://www.ncbi.nlm.nih.gov/pubmed/7925532%2C7925635>
13. Goldstein M, Gilbert BR, Dicker AP, Dwosh J, Gnecco C. Microsurgical inguinal varicocelectomy with delivery of the testis: an artery and lymphatic sparing technique. *J Urol* 1992;148(6):1808-11.
<http://www.ncbi.nlm.nih.gov/pubmed/1433614>
14. Hopps CV, Lemer ML, Schlegel PN, Goldstein M. Intraoperative varicocele anatomy: a microscopic study of the inguinal versus subinguinal approach. *J Urol* 2003;170(6 Pt 1):2366-70.
<http://www.ncbi.nlm.nih.gov/pubmed/14634418>
15. Kocvara R, Dvoracek J, Sedlacek J, Dite Z, Novak K. Lymphatic-sparing laparoscopic varicocelectomy: a microsurgical repair. *J Urol* 2005;173(5):1751-4.
<http://www.ncbi.nlm.nih.gov/pubmed/15821575>
16. Riccabona M, Oswald J, Koen M, Lusuardi L, Radmayr C, Bartsch G. Optimizing the operative treatment of boys with varicocele: sequential comparison of 4 techniques. *J Urol* 2003;169(2):666-8.
<http://www.ncbi.nlm.nih.gov/pubmed/12544340>
17. Marmar J, Benoff S. New scientific information related to varicoceles. (Editorial). *J Urol* 2003;170(6 Pt 1):2371-3.
<http://www.ncbi.nlm.nih.gov/pubmed/14634419>
18. Mazzoni G, Minucci S, Gentile V. Recurrent varicocele: role of antegrade sclerotherapy as first choice treatment. *Eur Urol* 2002;41(6):614-8; discussion 618.
<http://www.ncbi.nlm.nih.gov/pubmed/12074778>
19. Thon WF, Gall H, Danz B, Bahren W, Sigmund G. Percutaneous sclerotherapy of idiopathic varicocele in childhood: a preliminary report. *J Urol* 1989;141(4):913-5.
<http://www.ncbi.nlm.nih.gov/pubmed/2926889>
20. Minevich E, Wacksman J, Lewis AG, Sheldon CA. Inguinal microsurgical varicocelectomy in the adolescent: technique and preliminary results. *J Urol* 1998;159(3):1022-4.
<http://www.ncbi.nlm.nih.gov/pubmed/9474223>
21. Kass EJ, Reitelman C. The adolescent with a varicocele: who needs repair? *Probl Urol* 1994;8:507-17.

9. MICROPENIS

9.1 Background

Micropenis is a small but otherwise normally formed penis with a stretched length of less than 2.5 SD below the mean (1-3).

Besides an idiopathic micropenis, two major causes of abnormal hormonal stimulation have been identified:

- Hypogonadotropic hypogonadism (due to an inadequate secretion of GnRH)
- Hypergonadotropic hypogonadism (due to failure of the testes to produce testosterone).

9.2 Diagnosis

The penis is measured on the dorsal aspect, while stretching the penis, from the pubic symphysis to the tip of the glans (1). The corpora cavernosa are palpated, the scrotum is often small, and the testes may be small and descended. Micropenis should be distinguished from buried and webbed penis, which is usually of normal size.

The initial evaluation has to define whether the aetiology of the micropenis is central (hypothalamic/pituitary) or testicular. A paediatric endocrinology work-up has to be carried out immediately. Karyotyping is mandatory in all patients with a micropenis.

Endocrine testicular function is assessed (baseline and stimulated testosterone, LH and FSH serum levels). Stimulated hormone levels may also give an idea of the growth potential of the penis. In patients with non-palpable testes and hypogonadotropic hypogonadism, laparoscopy should be carried out to confirm vanishing testes syndrome or intra-abdominal undescended hypoplastic testes. This investigation can be delayed until the age of 1 year (2).

9.3 Treatment

Pituitary or testicular insufficiency are treated by the paediatric endocrinologist. In patients with testicular failure and proven androgen sensitivity, androgen therapy is recommended during childhood and at puberty to stimulate the growth of the penis (Level of evidence: 2; Grade of recommendation: B) (4-7). In the presence of androgen insensitivity, good outcome of sexual function is questioned and gender conversion can be considered (8-10).

9.4 REFERENCES

1. Feldman KW, Smith DW. Fetal phallic growth and penile standards for newborn male infants. *J Pediatr* 1975;86(3):395-8.
<http://www.ncbi.nlm.nih.gov/pubmed/1113226>
2. Aaronson IA. Micropenis; medical and surgical implications. *J Urol* 1994;152:4-14.
<http://www.ncbi.nlm.nih.gov/pubmed/8201683>
3. Gonzales JR. Micropenis. *AUA Update Series* 1983;2:1.
4. Burstein S, Grumbach MM, Kaplan SL. Early determination of androgen-responsiveness is important in the management of micropenis. *Lancet* 1979;2(8150):983-6
<http://www.ncbi.nlm.nih.gov/pubmed/91775>
5. Choi SK, Han SW, Kim DH, de Lignieres B. Transdermal dihydrotestosterone therapy and its effects on patients with micropenis. *J Urol* 1993;150(2 Pt 2):657-60.
<http://www.ncbi.nlm.nih.gov/pubmed/8326617>
6. Diamond M. Pediatric management of ambiguous and traumatized genitalia. *J Urol* 1999;162(3 Pt 2):1021-8.
<http://www.ncbi.nlm.nih.gov/pubmed/10458424>
7. Bin-Abbas B, Conte FA, Grumbach MM, Kaplan SL. Congenital hypogonadotropic hypogonadism and micropenis: effect of testosterone treatment on adult penile size. Why sex reversal is not indicated. *J Pediatr* 1999;134(5):579-83.
<http://www.ncbi.nlm.nih.gov/pubmed/10228293>
8. Calikoglu AS. Should boys with micropenis be reared as girls? *J Pediatr* 1999;134(5):537-8.
<http://www.ncbi.nlm.nih.gov/pubmed/10228285>
9. Reilly JM, Woodhouse CR. Small penis and the male sexual role. *J Urol* 1989;142(2 Pt 2):569-71.
<http://www.ncbi.nlm.nih.gov/pubmed/2746779>
10. Husmann DA. The androgen insensitive micropenis: long-term follow-up into adulthood. *J Pediatr Endocrinol Metab* 2004;17(8):1037-41.
<http://www.ncbi.nlm.nih.gov/pubmed/15379413>

10. DAYTIME LOWER URINARY TRACT CONDITIONS

10.1 Background

Following the new terminology document by the ICCS, 'daytime LUT conditions' is the new term used to group together functional incontinence problems in children (1). After any possible underlying uropathy or neuropathy has been excluded, a problem of incontinence in children is grouped into the category of 'daytime LUT conditions'. Night-time wetting is known as 'enuresis'.

Although exact data are unavailable, it is clear that the incidence of daytime LUT conditions is increasing. The changes in toilet training and toilet habits associated with a modern lifestyle have been blamed for the increase in incidence, but with little evidence. Rather, it is that modern life and higher hygiene standards have probably resulted in incontinence problems receiving more attention, so that an increase in prevalence

could be probably be attributed to an increased awareness. There exists a wide variation in reported prevalence ranging from 2% to 20% (2-6). This wide variation might reflect the variation in definitions used.

10.2 Definition

Daytime LUT conditions are conditions that present with lower urinary tract symptoms (LUTS), including urge, incontinence, weak stream, hesitancy, frequency and urinary tract infections, but without overt uropathy or neuropathy.

Normal bladder storage and voiding involves low pressure and adequate bladder volume filling. This is followed by a continuous detrusor contraction, which results in complete bladder emptying, associated with an adequate relaxation of the sphincter complex. Normal urine storage by the bladder and evacuation are controlled by a complex interaction between the spinal cord, brain stem, midbrain and higher cortical structures, associated with a complex integration of sympathetic, parasympathetic and somatic innervations (7).

It is understandable that this complex control mechanism is likely to be susceptible to developing different types of dysfunction. Various functional disorders of the detrusor-sphincter complex may occur during the sophisticated early development of normal mechanisms of micturition control. Voiding dysfunction is therefore thought to be the expression of incomplete or delayed maturation of the bladder sphincter complex.

Normal daytime control of bladder function matures between 2 and 3 years of age, while night-time control is normally achieved between 3 and 7 years of age (8). There are two main groups of voiding dysfunction, namely, filling-phase dysfunctions and voiding-phase dysfunctions.

10.2.1 Filling-phase dysfunctions

In filling-phase dysfunctions, the detrusor can be overactive, as in **overactive bladder (OAB) and urge syndrome**, or underactive, as in **underactive or highly compliant bladder** (formerly known as 'lazy bladder'). Some children habitually postpone micturition leading to **voiding postponement**.

10.2.2 Voiding-phase (emptying) dysfunctions

In voiding-phase (emptying) dysfunctions, interference with the sphincter and pelvic floor during detrusor contraction is the main dysfunction. The general term for this condition is **dysfunctional voiding**. Different degrees of dysfunction are described, depending on the strength of interference with the sphincter and pelvic floor. Weak interference results in staccato voiding, while stronger interference results in interrupted voiding and straining, due to an inability to relax during voiding.

Bladder sphincter dysfunction is often associated with bowel dysfunction such as obstipation and soiling. Sometimes, secondary anatomical changes are observed, such as trabeculation, diverticulae and vesicoureteral reflux.

10.3 Diagnosis

A non-invasive screening, consisting of history-taking, clinical examination, uroflow, ultrasound and voiding diary, is essential to reach a diagnosis.

In the paediatric age group, where the history is taken from both the parents and child together, a structured approach is recommended using a questionnaire. Many signs and symptoms related to voiding and wetting will be unknown to the parents and should be specifically requested, using the questionnaire as a checklist. A voiding diary is mandatory to determine the child's voiding frequency and voided volumes as well as the child's drinking habits. History-taking should also include assessment of bowel function. Some dysfunctional voiding scores have recently been developed and validated (9, 10).

Upon clinical examination, genital inspection and observation of the lumbosacral spine and the lower extremities is necessary to exclude obvious uropathy and neuropathy. Uroflow with post-void residual evaluates the emptying ability, while an upper urinary tract ultrasound screens for secondary anatomical changes. A voiding diary provides information about storage function and incontinence frequency, while a pad test can help to quantify the urine loss.

In the case of resistance to initial treatment, or in the case of former failed treatment, re-evaluation is warranted and further video-urodynamic studies may be considered. Sometimes, there are minor, underlying, urological or neurological problems, which can only be suspected using video-urodynamics.

In the case of anatomical problems, such as urethral valve problems, syringocoeles, congenital obstructive posterior urethral membrane (COPUM) or Moormann's ring, it may be necessary to perform further cystoscopy with treatment. If neuropathic disease is suspected, MRI of the lumbosacral spine and medulla can help to exclude tethered cord, lipoma or other rare conditions.

Psychological screening may be useful for children or families with major psychological problems associated with the voiding dysfunction.

10.4 Treatment

Treatment of voiding dysfunction consists of lower urinary tract rehabilitation, mostly referred to as urotherapy. Urotherapy means non-surgical, non-pharmacological, treatment of lower urinary tract (LUT) function. It is a very broad therapy field, incorporating many treatments used by urotherapists and other healthcare professionals (11). Urotherapy can be divided into standard therapy and specific interventions.

10.4.1 Standard therapy

Standard urotherapy is defined as non-surgical, non-pharmacological, treatment for LUT malfunction. It includes the following components:

- Information and demystification, which includes explanation about normal LUT function and how a particular child deviates from normal function.
- Instruction about what to do about the problem, i.e. regular voiding habits, sound voiding posture, avoiding holding manoeuvres, etc.
- Lifestyle advice, regarding fluid intake, prevention of constipation, etc
- Registration of symptoms and voiding habits using bladder diaries or frequency-volume charts
- Support and encouragement via regular follow-up by the caregiver.

A success rate of 80% has been described for urotherapy programmes, independent of the components of the programme. However, the evidence level is low as most studies of urotherapy programmes are retrospective and non-controlled.

10.4.2 Specific interventions

As well as urotherapy, there are some specific interventions, including physiotherapy (e.g. pelvic floor exercises), biofeedback, alarm therapy and neurostimulation. Although good results with these treatment modalities have been reported, there have been no randomised controlled treatment trials (RCTs), so that the level of evidence is low (11-15).

In some cases, pharmacotherapy may be added. Antispasmodics and anticholinergics have been shown to be effective, though the level of evidence was low. More recently, a few RCTs have been published. One trial on tolterodine showed safety but not efficacy (16), while another RCT on propiverine showed both safety and efficacy (17) (level of evidence: 1) (17). The difference in results is probably due to study design. Despite the low level of evidence for the use of anticholinergics and antimuscarinics, their use is recommended (grade of recommendation: B) because of the large number of studies reporting a positive effect on OAB symptoms.

Although alpha-blocking agents are used occasionally, an RCT showed no benefit (18). Botulinum toxin injection seems promising, but can only be used off-label (19).

10.5 REFERENCES

1. Neveus T, von Gontard A, Hoebeke P, Hjälmås K, Bauer S, Bower W, Jørgensen TM, Rittig S, Walle JV, Yeung CK, Djurhuus JC. The standardization of terminology of lower urinary tract function in children and adolescents: report from the Standardisation Committee of the International Children's Continence Society. *J Urol* 2006;176(1):314-24.
<http://www.ncbi.nlm.nih.gov/pubmed/16753432>
2. Hellström AL, Hanson E, Hansson S, Hjälmås K, Jodal U. Micturition habits and incontinence in 7-year-old Swedish school entrants. *Eur J Pediatr* 1990;149(6):434-7.
<http://www.ncbi.nlm.nih.gov/pubmed/2332015>
3. Bakker E, van Sprundel M, van der Auwera JC, van Gool JD, Wyndaele JJ. Voiding habits and wetting in a population of 4,332 Belgian schoolchildren aged between 10 and 14 years. *Scand J Urol Nephrol* 2002;36(5):354-62.
<http://www.ncbi.nlm.nih.gov/pubmed/12487740>
4. Söderstrom U, Hoelcke M, Alenius L, Söderling AC, Hjern A. Urinary and faecal incontinence: a population-based study. *Acta Paediatr* 2004;93(3):386-9.
<http://www.ncbi.nlm.nih.gov/pubmed/15124844>
5. Sureshkumar P, Jones M, Cumming R, Craig J. A population based study of 2,856 school-age children with urinary incontinence. *J Urol* 2009;181(2):808-15; discussion 815-6.
<http://www.ncbi.nlm.nih.gov/pubmed/19110268>
6. Sureshkumar P, Craig JC, Roy LP, Knight JF. Daytime urinary incontinence in primary school children: a population-based survey. *J Pediatr* 2000;137(6):814-8.
<http://www.ncbi.nlm.nih.gov/pubmed/11113838>
7. Franco I. Overactive bladder in children. Part 1: Pathophysiology. *J Urol* 2007;178(3 Pt 1):761-8; discussion 768.
<http://www.ncbi.nlm.nih.gov/pubmed/17631323>

8. Hellstrom AL, Hanson E, Hansson S, Hjälmarks K, Jodal U. Micturition habits and incontinence in 7-year-old Swedish school entrants. *Eur J Pediatr* 1990;149(6):434-7.
<http://www.ncbi.nlm.nih.gov/pubmed/2332015>
9. Akbal C, Genc Y, Burgu B, Ozden E, Tekgul S. Dysfunctional voiding and incontinence scoring system: quantitative evaluation of incontinence symptoms in pediatric population. *J Urol* 2005;173(3):969-73.
<http://www.ncbi.nlm.nih.gov/pubmed/15711352>
10. Farhat W, Bägli DJ, Capolicchio G, O'Reilly S, Merguerian PA, Khoury A, McLorie GA. The dysfunctional voiding scoring system: quantitative standardization of dysfunctional voiding symptoms in children. *J Urol* 2000;164(3 Pt 2):1011-5.
<http://www.ncbi.nlm.nih.gov/pubmed/10958730>
11. Hellstrom AL. Urotherapy in children with dysfunctional bladder. *Scand J Urol Nephrol Suppl* 1992;141:106-7.
<http://www.ncbi.nlm.nih.gov/pubmed/1609245>
12. Vijverberg MA, Elzinga-Plomp A, Messer AP, van Gool JD, de Jong TP. Bladder rehabilitation, the effect of a cognitive training programme on urge incontinence. *Eur Urol* 1997;31(1):68-72.
<http://www.ncbi.nlm.nih.gov/pubmed/9032538>
13. De Paepe H, Hoebeke P, Renson C, Van Laecke E, Raes A, Van Hoecke E, Van Daele J, Vande Walle J. Pelvic-floor therapy in girls with recurrent urinary tract infections and dysfunctional voiding. *Br J Urol* 1998;81(Suppl 3):109-13.
<http://www.ncbi.nlm.nih.gov/pubmed/9634033>
14. De Paepe H, Renson C, Van Laecke E, Raes A, Vande Walle J, Hoebeke P. Pelvic-floor therapy and toilet training in young children with dysfunctional voiding and obstipation. *BJU Int* 2000;85(7):889-93.
<http://www.ncbi.nlm.nih.gov/pubmed/10792172>
15. Bower WF, Yeung CK. A review of non-invasive electro neuromodulation as an intervention for nonneurogenic bladder dysfunction in children. *Neurourol Urodyn* 2004;23(1):63-7.
<http://www.ncbi.nlm.nih.gov/pubmed/14694460>
16. Nijman RJ, Borgstein NG, Ellsworth P, Djurhuus JC. Tolterodine treatment for children with symptoms of urinary urge incontinence suggestive of detrusor overactivity: results from 2 randomized, placebo controlled trials. *J Urol* 2005;173(4):1334-9.
<http://www.ncbi.nlm.nih.gov/pubmed/15758796>
17. Marschall-Kehrel D, Feustel C, Persson de Geeter C, Stehr M, Radmayr C, Sillén U, Strugala G. Treatment with propiverine in children suffering from nonneurogenic overactive bladder and urinary incontinence: results of a randomized placebo-controlled phase 3 clinical trial. *Eur Urol* 2008 May 7. [Epub ahead of print]
<http://www.ncbi.nlm.nih.gov/pubmed/18502028>
18. Kramer SA, Rathbun SR, Elkins D, Karnes RJ, Husmann DA. Double-blind placebo controlled study of alpha-adrenergic receptor antagonists (doxazosin) for treatment of voiding dysfunction in the pediatric population. *J Urol* 2005;173(6):2121-4; discussion 2124.
<http://www.ncbi.nlm.nih.gov/pubmed/15879863>
19. Hoebeke P, De Caestecker K, Vande Walle J, Dehoorne J, Raes A, Verleyen P, Van Laecke E. The effect of botulinum-A toxin in incontinent children with therapy resistant overactive detrusor. *J Urol* 2006;176(1):328-30; discussion 330-1.
<http://www.ncbi.nlm.nih.gov/pubmed/16753434>

11. MONOSYMPTOMATIC ENURESIS

11.1 Background

Enuresis is synonymous to intermittent nocturnal incontinence. It is a frequent symptom in children. With a prevalence of 5-10% at 7 years of age, it is one of the most prevalent conditions in childhood. With a spontaneous yearly cure rate of 15%, it is considered relatively benign (1, 2).

However, 7 out of 100 children wetting the bed at age 7 will take this condition into adulthood. As it is a stressful condition, which puts a high psychological burden on children resulting in low self-esteem, treatment is advised from the age of 6-7 years onwards. Treatment is unnecessary in younger children in whom spontaneous cure is likely. The child's mental status, family expectations, social issues and cultural background need to be considered before treatment can be started.

11.2 Definition

Enuresis is the condition describing the symptom of incontinence during night. Any wetting during sleep above the age of 5 years is enuresis. However, most importantly, there is a single symptom only. Children with other LUT symptoms and enuresis are said to have **non-monosymptomatic enuresis**. Thorough history-taking, excluding any other daytime symptoms, is mandatory before diagnosing **monosymptomatic enuresis**. Any associated urinary tract symptoms make the condition a '**daytime LUT condition**' (3).

The condition is described as 'primary' when the symptom has always existed and the patient has not been dry for a period longer than 6 months. The condition is described as 'secondary', when there has been a symptom-free interval of 6 months. Genetically, enuresis is a complex and heterogeneous disorder. Loci have been described on chromosomes 12, 13 and 22 (3).

Three factors play an important pathophysiological role:

- high night-time urine output
- night-time low bladder capacity or increased detrusor activity
- arousal disorder.

Due to an imbalance between night-time urine output and night-time bladder capacity, the bladder can become easily full at night and the child will either wake up to empty the bladder or will void during sleep if there is a lack of arousal from sleep (1-3).

11.3 Diagnosis

The diagnosis is obtained by history-taking. In a patient with monosymptomatic enuresis, no further investigations are needed. A voiding diary, which records daytime bladder function and night-time urine output, will help to guide the treatment. An estimate of night-time urine production can be obtained by weighing diapers (nappies) in the morning and adding the volume of the morning void. Measuring the daytime bladder capacity gives an estimate of bladder capacity compared to normal values for age (4).

In most children, bedwetting is a familial problem, with most affected children found to have a history of bedwetting within the family.

11.4 Treatment

Before using alarm treatment or medication, simple therapeutic interventions should be considered.

11.4.1 Supportive treatment measures

Explaining the condition to the child and his parents helps to demystify the problem. Eating and drinking habits should be reviewed, stressing normal fluid intake during day and reducing fluid intake in the hours before sleep. Keeping a chart depicting wet and dry nights has been shown to be successful.

Counselling, provision of information, positive reinforcement and increasing (and supporting) motivation of the child should be introduced first. There is a high level of evidence showing that supportive treatment is more successful than doing nothing, though the cure rate is not significantly high. However, supportive therapy as an initial management carries a high grade of recommendation (4).

If supportive measures have no success, further treatment modalities must be considered, of which pharmacological treatment and alarm treatment are the two most important.

11.4.2 Alarm treatment

Alarm treatment is the best form of treatment for arousal disorder (level of evidence: 1) (grade of recommendation: A). Initial success rates of 80% with low relapse rates are realistic, especially when night-time diuresis is not too high and bladder capacity is not too low (5).

11.4.3 Medication

In the case of high night-time diuresis, success rates of 70% can be obtained with desmopressin (DDAVP), either as tablets, 200-400 µg or as sublingual desmopressin oral lyophilisate, 120-240 µg. A nasal spray is no longer recommended due to an increased risk of overdosing (6) (level of evidence: 1) (grade of recommendation: A) (7). However, relapse rates are high after DDAVP discontinuation (4).

In the case of a small bladder capacity, treatments with antispasmodics or anticholinergics are possible (4). However, when these medications are necessary, the condition is no longer considered to be monosymptomatic.

Imipramine, which has been popular in the treatment of enuresis, achieves only a moderate response rate of 50% and has a high relapse rate. Furthermore, cardiotoxicity and death with overdose are described. Its use should therefore be discouraged (level of evidence: 1) (grade of recommendation: C) (8).

11.5 REFERENCES

1. Lackgren G, Hjalmas K, van Gool J, von Gontard A, de Gennaro M, Lottmann H, Terho P. Nocturnal enuresis: a suggestion for a European treatment strategy. *Acta Paediatr* 1999;88(6):679-90.
<http://www.ncbi.nlm.nih.gov/pubmed/10419258>
2. Neveus T, von Gontard A, Hoebeke P, Hjalmas K, Bauer S, Bower W, Jørgensen TM, Rittig S, Walle JV, Yeung CK, Djurhuus JC. The standardization of terminology of lower urinary tract function in children and adolescents: report from the Standardisation Committee of the International Children's Continence Society. *J Urol* 2006;176(1):314-24.
<http://www.ncbi.nlm.nih.gov/pubmed/16753432>
3. Neveus T, Lackgren G, Tuvemo T, Hetta J, Hjalmas K, Stenberg A. Enuresis—background and treatment. *Scand J Urol Nephrol Suppl* 2000;206:1-44.
<http://www.ncbi.nlm.nih.gov/pubmed/11196246>
4. Hjalmas K, Arnold T, Bower W, Caione P, Chiozza LM, von Gontard A, Han SW, Husman DA, Kawachi A, Lackgren G, Lottmann H, Mark S, Rittig S, Robson L, Walle JV, Yeung CK. Nocturnal enuresis: an international evidence based management strategy. *J Urol* 2004;171(6 Pt 2):2545-61.
<http://www.ncbi.nlm.nih.gov/pubmed/15118418>
5. Glazener CM, Evans JH, Peto RE. Alarm interventions for nocturnal enuresis in children. *Cochrane Database Syst Rev* 2005;(2):CD002911.
<http://www.ncbi.nlm.nih.gov/pubmed/15846643>
6. Dehoorne JL, Raes AM, van Laecke E, Hoebeke P, Vande Walle JG. Desmopressin toxicity due to prolonged half-life in 18 patients with nocturnal enuresis. *J Urol* 2006;176(2):754-7; discussion 757-8.
<http://www.ncbi.nlm.nih.gov/pubmed/16813936>
7. Glazener CMA, Evans JH. Desmopressin for nocturnal enuresis. *Cochrane Database Syst Rev* 2002;(3):CD002112.
<http://www.ncbi.nlm.nih.gov/pubmed/12137645>
8. Glazener CMA, Evans JHC, Peto R. Tricyclic and related drugs for nocturnal enuresis in children. *Cochrane Database Syst Rev* 2000;(2):CD002117.
<http://www.ncbi.nlm.nih.gov/pubmed/12917922>

12. MANAGEMENT OF NEUROGENIC BLADDER IN CHILDREN

12.1 Background

Neurogenic detrusor-sphincter dysfunction (NDSD) can develop as a result of a lesion at any level in the nervous system. This condition contributes to various forms of lower urinary tract dysfunction, which may lead to incontinence, urinary tract infections (UTIs), vesicoureteral reflux (VUR), and renal scarring. Surgery may be required to establish adequate bladder drainage. If not managed properly, NDSD can potentially cause renal failure, requiring dialysis or transplantation.

The management of neurogenic bladder sphincter dysfunction in children has undergone major changes over the years. Although nappies (diapers), permanent catheters, external appliances, Crede's manoeuvre and various forms of urinary diversion have been acceptable treatment methods, these are now reserved for only a small number of resistant patients. The introduction of clean intermittent catheterisation (IC) has revolutionised the management of children with neurogenic bladder. Not only has it made conservative management a very successful treatment option, but it has also made surgical creation of continent reservoirs a very effective treatment alternative, with a good outcome for quality of life and kidney protection (1-3).

Neurogenic bladder in children with myelodysplasia presents with various patterns of detrusor-sphincter dysfunction within a wide range of severity. About 15% of neonates with myelodysplasia have no signs of neurourological dysfunction at birth. However, there is a high chance of progressive changes in the dynamics of neurological lesions with time. Even babies with normal neurourological function at birth have a one in three risk of developing either detrusor sphincter dyssynergia or denervation by the time they reach puberty. At birth, the majority of patients have normal upper urinary tracts, but nearly 60% of them develop upper tract deterioration due to infections, bladder changes and reflux (4-7).

As our understanding of urodynamic studies has evolved, it has allowed us to understand the nature and

severity of problems and manage these patients in a more rational and individualised manner. Despite the remarkable changes of the last quarter of the 20th century, the main goals of treatment have remained the same, i.e. prevention of urinary tract deterioration and achievement of continence at an appropriate age.

12.2 Definition

The most common presentation is at birth with myelodysplasia. The term myelodysplasia includes a group of developmental anomalies that result from defects in neural tube closure. Lesions may include spina bifida occulta, meningocele, lipomyelomeningocele, or myelomeningocele. Myelomeningocele is by far the most common defect seen and the most detrimental. Traumatic and neoplastic spinal lesions of the cord are less frequent in children. Additionally, different growth rates between the vertebral bodies and the elongating spinal cord can introduce a dynamic factor to the lesion. Scar tissue surrounding the cord at the site of meningocele closure can tether the cord during growth.

In occult myelodysplasia, the lesions are not overt and often occur with no obvious signs of neurological lesion. In nearly 90% of patients, however, a cutaneous abnormality overlies the lower spine, and this condition can easily be detected by simple inspection of the lower back (8).

Total or partial sacral agenesis is a rare congenital anomaly that involves absence of part or all of one or more sacral vertebrae. This anomaly can be part of the caudal regression syndrome, and must be considered in any child presenting with anorectal malformation (ARM). Patients with cerebral palsy may also present with varying degrees of voiding dysfunction, usually in the form of uninhibited bladder contractions (often due to spasticity of the pelvic floor and sphincter complex) and wetting.

Bladder sphincter dysfunction is poorly correlated with the type and spinal level of the neurological lesion.

12.3 Classification

The purpose of any classification system is to facilitate the understanding and management of the underlying pathology. There are various systems of classification of neurogenic bladder.

Most systems of classification were formulated primarily to describe those types of dysfunction secondary to neurological disease or injury. Such systems are based on the localisation of the neurological lesion and the findings of the neurourological examination. These classifications have been of more value in adults, in whom neurogenic lesions are usually due to trauma and are more readily identifiable.

In children, the spinal level and extent of congenital lesion are poorly correlated with the clinical outcome. Urodynamic and functional classifications have therefore been more practical for defining the extent of the pathology and planning treatment in children.

The bladder and sphincter are two units working in harmony to make a single functional unit. The initial approach should be to evaluate the state of each unit and define the pattern of bladder dysfunction. According to the nature of the neurological deficit, the bladder and sphincter may be in either an overactive or inactive state:

- the bladder may be overactive with increased contractions, and low capacity and compliance, or inactive with no effective contractions
- the outlet (urethra and sphincter) may be independently overactive causing functional obstruction, or paralysed with no resistance to urinary flow
- these conditions may present in different combinations.

This is mainly a classification based on urodynamic findings. The understanding of the pathophysiology of disorders is essential to plan a rational treatment plan for each individual patient. In meningomyelocele, most patients will present with hyper-reflexive detrusor and dyssynergic sphincter, which is a dangerous combination as pressure is built up and the upper tract is threatened.

12.4 Urodynamic studies

Urodynamic studies enable the clinician to observe lower urinary tract function and its deviations from normal. Since the treatment plan mainly depends upon a good understanding of the underlying problem in the lower urinary tract, a well-performed urodynamic study is mandatory in the evaluation of each child with neurogenic bladder.

As the bony level often does not correspond with the neurological defect present, and as the effect of the lesion on bladder function cannot be entirely determined by radiographic studies or physical examination,

the information gained from a urodynamic study is priceless. A urodynamic study also provides the clinician with information about the response of the vesicourethral unit to therapy, as demonstrated by improvement or deterioration in follow-up.

It is important to determine several urodynamic parameters, including:

- the bladder capacity
- the intravesical filling pressure
- the intravesical pressure at the moment of urethral leakage
- the presence or absence of reflex detrusor activity
- the competence of the internal and external sphincteric mechanisms
- the degree of coordination of the detrusor and sphincteric mechanisms
- the voiding pattern
- the post-voiding residual urine volume.

12.4.1 *Method of urodynamic study*

There is very little comparative data evaluating the complexity and invasiveness of urodynamic testing for neurogenic bladders in children.

12.4.2 *Uroflowmetry*

As uroflowmetry is the least invasive of all urodynamic tests, it can be used as an initial screening tool. It provides an objective way of assessing the efficiency of voiding, and, together with an ultrasonographic examination, the residual urine volume can also be determined. Unlike in children with non-neurogenic voiding dysfunction, uroflowmetry will rarely be used as a single investigational tool in children with neurogenic bladders, as it does not provide information for bladder storage, yet it may be very practical to monitor emptying in the follow-up. The main limitation of a urodynamic study is the need for the child to be old enough to follow instructions and void on request.

The recording of pelvic floor or abdominal skeletal muscle activity by electromyography (EMG) during uroflowmetry can be used to evaluate coordination between detrusor and the sphincter. As it is a non-invasive test, combined uroflowmetry and EMG may be very useful in evaluating sphincter activity during voiding (9-12) (level of evidence: 3) (grade of recommendation: C).

12.4.3 *Cystometry*

Although moderately invasive and dependent on a cooperative child, cystometry in children provides valuable information regarding detrusor contractility and compliance. The amount of information obtained from each study is related to the degree of interest and care given to the test.

It is important to be aware of the alterations in filling and emptying detrusor pressures as the infusion rates change during cystometry. Slow fill cystometry (filling rate < 10 mL/min) is recommended by the International Children's Continence Society (ICCS) for use in children (13). However, it has been suggested that the infusion rate should be set according to the child's predicted capacity, based on age and divided by 10 (14).

Several clinical studies using conventional artificial fill cystometry to evaluate neurogenic bladder in children have reported that conventional cystometry provides useful information for diagnosis and follow-up of children with neurogenic bladder (15-20). All the studies were retrospective clinical series and lacked comparison with natural fill cystometry, so that the grade of recommendation for an artificial cystometry in children with neurogenic bladder is not high (level of evidence: 4). Additionally, there is evidence suggesting that natural bladder behaviour is altered during regular artificial filling cystometry (21, 22).

However, conventional cystometry in infants is useful for predicting future deterioration. Urodynamic parameters, such as low capacity and compliance and high leak-point pressures, are poor prognostic factors for future deterioration. Resolution of reflux is less likely to happen in such bladders (15, 20, 22) (level of evidence: 4).

During natural fill cystometry, the bladder is allowed to fill naturally and the bladder and abdominal pressures are recorded using microtransducer catheters. Theoretically, this allows investigation of bladder function in near-physiological conditions. Studies on natural fill cystometry in children report similar results to those of studies done in adults. Natural fill cystometry gives a lower detrusor pressure rise during filling, and lower voided volumes with higher voiding pressures. The incidence of bladder overactivity is higher with natural filling cystometry when compared with conventional artificial filling cystometry (21, 23, 24).

Although there are only a few studies on natural fill cystometry in children with neurogenic bladder, the results suggest that natural fill cystometry detects new findings compared with diagnoses delivered by conventional cystometry (21) (level of evidence: 3). However, the comparison between natural fill and artificial fill cystometry has not been performed against a gold standard, making it difficult to conclude which study is a true reflection of natural bladder behaviour. Findings in the non-neurogenic adult population have questioned the reliability of natural fill cystometry, as natural fill cystometry has shown a high incidence of bladder overactivity in totally normal asymptomatic volunteers (25).

The main disadvantage of natural fill cystometry is that it is labour-intensive and time-consuming. Moreover, because of the transurethral catheter used during this study, false-positive findings caused by the catheter are possible. Especially in children, the recording of events is difficult and there is an increased risk of artefacts, which makes interpretation of the huge amount of data even more difficult.

Natural fill cystometry remains a new technique in the paediatric population. More data need to be gathered in a standard way before it can be widely accepted (11).

12.5 Management

The medical care of children with myelodysplasia with a neurogenic bladder requires constant observation and adaptation to new problems. In the first years of life, the kidneys are highly susceptible to back-pressure and infection. During this period, the emphasis is on documenting the pattern of NDSD, and assessing the potential for functional obstruction and VUR.

12.5.1 Investigations

An abdominal ultrasound obtained as soon as possible after birth will detect hydronephrosis or other upper genitourinary tract pathology. Following ultrasound, a voiding cystourethrogram should be obtained to evaluate the lower urinary tract. Measurement of residual urine during both ultrasound and cystography should also be done. These studies provide a baseline for the appearance of the upper and lower urinary tracts, can facilitate the diagnosis of hydronephrosis or VUR, and can help identify children at risk for upper genitourinary tract deterioration and impairment of renal function.

A urodynamic evaluation can be done after some weeks, and needs to be repeated at regular intervals, in combination with evaluation of the upper tracts (26-28) (level of evidence: 3) (grade of recommendation: B).

12.5.2 Early management with intermittent catheterisation

Overwhelming experience gained over the years with early management of neurogenic bladder in infants has led to a consensus that children do not have upper tract deterioration when managed early with IC and anticholinergic medication. IC should be started soon after birth in all babies, especially in those with signs of possible outlet obstruction (26, 29-37) (level of evidence: 2) (grade of recommendation: B).

The early initiation of IC in the newborn period makes it easier for parents to master the procedure and for children to accept it as they grow older (38, 39).

Early management results in fewer upper tract changes, but also better bladder protection and lower incontinence rates. It has been suggested that increased bladder pressures due to detrusor sphincter dyssynergia cause secondary changes of the bladder wall. These fibroproliferative changes in the bladder wall may cause further loss of elasticity and compliance, resulting in a small non-compliant bladder with progressively elevated pressures.

Early institution of IC and anticholinergic drugs may prevent this in some patients (2, 37, 40) (level of evidence: 3). The retrospective evaluation of patients has also shown that significantly fewer augmentations were required in patients with an early start of IC (33, 34) (level of evidence: 4).

12.5.3 Medical therapy

At present, oxybutynin, tolterodine, trospium and propiverine are the most frequently used drugs, with oxybutynin being the most studied.

Two different forms of tolterodine have been investigated in children with neurogenic bladder. The extended release formulation of tolterodine has been found to be as efficient as the instant release form, with the advantages of being single dosage and less expensive. Although the clinical outcome is encouraging, the level of evidence is low for anticholinergic medication because there are no controlled studies (40, 41-47) (level of

evidence: 3) (grade of recommendation: B).

The use of medication to facilitate emptying in children with neurogenic bladder has not been well studied in the literature. A few studies investigating the use of α -adrenergic blockade in children with neurogenic bladder have reported a good response rate, but the studies lacked controls, and long-term follow-up is warranted (48) (level of evidence: 4) (grade of recommendation: C).

12.5.3.1 *Botulinum toxin injections*

In neurogenic bladders that are refractory to anticholinergics and remain in a small-capacity, high-pressure state, a novel treatment alternative is the injection of botulinum toxin into the detrusor. Initial promising results in adults have initiated its use in children. So far, studies of the clinical effect of botulinum toxin in children have been open trials, and there is a lack of prospective controlled trials. However, the injection of botulinum toxin in therapy-resistant bladders appears to be an effective and safe treatment alternative.

This treatment seems to be more effective in bladders with evidenced detrusor overactivity, while non-compliant bladders without obvious detrusor contractions are unlikely to respond to this treatment (49-52).

The dosage in children should be determined by body weight and minimum age, with caution with regard to total dose if it is also being used to treat spasticity. Currently, it is unclear how many times this treatment can be repeated, although repetitive treatment has been found to be safe in adults (53-55) (level of evidence: 3) (grade of recommendation: C).

In a single study, urethral sphincter botulinum-A toxin injection has been shown to be effective in decreasing urethral resistance and improve voiding. The evidence is still too low to recommend its routine use in decreasing outlet resistance, but it could be considered as an alternative in refractory cases (56).

12.5.4 *Management of bowel incontinence*

Children with neurogenic bladder have disturbances of bowel function as well as urinary function. Bowel incontinence in these children is frequently unpredictable. It is related to the turnover rate of faecal material in the anal area after evacuation, the degree of intactness of sacral cord sensation and motor function, and reflex reactivity of the external anal sphincter (57).

Bowel incontinence is managed most commonly with mild laxatives, such as mineral oil, combined with enemas to facilitate removal of bowel contents. A regular and efficient bowel emptying regimen is often necessary to maintain faecal continence, and may have to be started at a very young age. With antegrade or retrograde enemas, most of these children will have decreased constipation problems and may attain some degree of faecal continence (58-62) (level of evidence: 3).

Biofeedback training programmes to strengthen the external anal sphincter have not been shown to be more effective than a conventional bowel management programme in achieving faecal continence (63). Electrostimulation of the bowel may also offer a variable improvement in some patients (64) (level of evidence: 3) (grade of recommendation: C).

12.5.5 *Urinary tract infection*

UTIs are common in children with neurogenic bladders. In the absence of reflux, UTIs should be treated symptomatically. There is strong evidence for not prescribing antibiotics to patients who have bacteriuria but no clinical symptoms. Although bacteriuria is seen in more than half of children on clean IC, patients who are asymptomatic do not need treatment (65-67) (level of evidence: 3). Patients with VUR should usually be placed on prophylactic antibiotics to reduce the incidence of pyelonephritis, which can potentially lead to renal damage (68, 69).

12.5.6 *Sexuality*

Sexuality, while not an issue in childhood, becomes progressively more important as the patient gets older. This issue has historically been overlooked in individuals with myelodysplasia. However, patients with myelodysplasia do have sexual encounters. Studies indicate that at least 15-20% of males are capable of fathering children and 70% of females can conceive and carry a pregnancy to term. It is therefore important to counsel patients about sexual development in early adolescence.

12.5.7 *Bladder augmentation*

Children with a good response to anticholinergic treatment and an overactive sphincter may be continent

between catheterisations. Bladder pressure and development of the upper urinary tract will determine whether additional treatment is necessary.

Therapy-resistant overactivity of the detrusor, or small capacity and poor compliance, will usually need to be treated by bladder augmentation. A simple bladder augmentation using intestine may be carried out if there is any bladder tissue, a competent sphincter and/or bladder neck, and a urethra that can be catheterised. Stomach is rarely used as an augmenting patch because of the associated complications (70). Ileal or colonic patches are frequently used for augmenting the bladder, with either intestinal segment appearing to be equally useful. Despite some advantages (e.g. avoiding mucus, decreased malignancy rate and fewer complications), alternative urothelium-preserving techniques, such as autoaugmentation and seromuscular cystoplasty, have not proven to be as successful as standard augmentation with intestine (71, 72).

A range of applications of engineered bladder tissues are at different stages of development. There have been a few in pre-clinical trials; recent progress suggests that engineered bladder tissues may have an expanded clinical application in the future (73).

12.5.8 Bladder outlet procedures

Children with detrusor overactivity, but with underactive sphincters, will be better for protecting their upper tracts, although they will be severely incontinent. Initial treatment is IC (as it might reduce the degree of incontinence and offers much better control over UTIs) with anticholinergic drugs. At a later age, the outlet resistance will be increased in order to render them continent. No medical treatment available has been validated to increase bladder outlet resistance. Alpha-receptor stimulation of the bladder neck has not been very effective (74-79).

When conservative measures fail, surgical procedures need to be considered for maintaining continence. Although a simple augmentation is sufficient for most low-capacity, high-pressure bladders, augmentation with additional bladder outlet procedures is required when both the bladder and outlet are deficient. Bladder outlet procedures include bladder neck reconstruction or other forms of urethral reconstruction.

Various procedures can be used on the bladder neck to increase resistance, but all of them may complicate transurethral catheterisation. Augmentation with surgical closure of the bladder neck may be required primarily, or as a secondary procedure in certain rare clinical situations. In this situation, a continent stoma will be required. However, most surgeons prefer to leave the bladder neck and urethra patent as a safety precaution.

12.5.9 Continent stoma

Augmentation with an additional continent stoma is utilised primarily after failure of previous bladder outlet surgery. It is also advisable when an inability to catheterise transurethrally is likely. An abdominal wall continent stoma may be particularly beneficial to wheelchair-bound spina bifida patients, who often have difficulty with urethral catheterisation or are dependent on others to catheterise the bladder. For continence with augmentation and an abdominal wall stoma, an adequate bladder outlet mechanism is essential to maintain continence.

12.5.10 Total bladder replacement

Total bladder replacement in anticipation of normal voiding in children is very rare, as there are infrequent indications for a total cystectomy, with preservation of the bladder outlet and a competent urethral sphincter. This type of bladder replacement is much more common in adult urological reconstruction. Any type of major bladder and bladder outlet construction should be performed in centres with sufficient experience of the surgical technique, and with experienced healthcare personnel to carry out post-operative follow-up (80-82).

12.5.11 Lifelong follow-up of neurogenic bladder patients

Neurogenic bladder patients require lifelong supervision, and the monitoring of renal function is extremely important. Periodic investigation of upper tract changes, renal function and bladder status is mandatory. Repeat urodynamic tests are therefore needed more frequently (every year) in younger children and less frequently in older children. From the urological viewpoint, a repeat urodynamic study is warranted when the patient has a change in symptoms or undergoes any neurosurgical procedure. In the case of any apparent changes in the upper and lower urinary tract, or changes in neurological symptoms, a more detailed examination including urodynamics and spinal magnetic resonance imaging is indicated.

Renal failure can progress slowly or occur with startling speed in these children. Patients who have undergone reconstructive procedures using intestine should be regularly followed-up for complications such as infection,

stone formation, reservoir rupture, metabolic changes, and malignancy (83).

12.6 REFERENCES

1. Bauer SB. The management of the myelodysplastic child: a paradigm shift. *BJU Int* 2003;92(Suppl 1):23-8.
<http://www.ncbi.nlm.nih.gov/pubmed/12969005>
2. Retik AB, Perlmutter AD, Gross RE. Cutaneous ureteroileostomy in children. *N Eng J Med* 1967;277(5):217-22.
<http://www.ncbi.nlm.nih.gov/pubmed/4226464>
3. Lapidus J, Diokno AC, Silber SJ, Lowe BS. Clean, intermittent self-catheterization in the treatment of urinary tract disease. 1972. *J Urol* 2002;167(2 Pt 2):1131-3; discussion 1134.
<http://www.ncbi.nlm.nih.gov/pubmed/11905887>
4. Bauer SB. The management of spina bifida from birth onwards. In: Whitaker RH, Woodard JR, eds. *Paediatric urology*. London: Butterworths, 1985, pp. 87-112.
5. Bauer SB. Early evaluation and management of children with spina bifida. In: King LR (ed). *Urologic surgery in neonates and young infants*. Philadelphia: WB Saunders, 1988, pp. 252-264.
6. Wilcock AR, Emery JL. Deformities of the renal tract in children with meningomyelocele and hydrocephalus, compared with those of children showing no such deformities. *Br J Urol* 1970;42(2):152-7.
<http://www.ncbi.nlm.nih.gov/pubmed/5420153>
7. Hunt GM, Whitaker RH. The pattern of congenital renal anomalies associated with neural-tube defects. *Dev Med Child Neurol* 1987;29(1):91-5.
<http://www.ncbi.nlm.nih.gov/pubmed/3556803>
8. Pierre-Kahn A, Zerah M, Renier D, Cinalli G, Sainte-Rose C, Lellouch-Tubiana A, Brunelle F, Le Merrer M, Giudicelli Y, Pichon J, Kleinknecht B, Nataf F. Congenital lumbosacral lipomas. *Childs Nerv Syst*. 1997;13(6):298-334; discussion 335.
<http://www.ncbi.nlm.nih.gov/pubmed/9272285>
9. Aoki H, Adachi M, Banya Y, Sakuma Y, Seo K, Kubo T, Ohori T, Takagane H, Suzuki Y. [Evaluation of neurogenic bladder in patients with spinal cord injury using a CMG.EMG study and CMG.UFM.EMG study.] *Hinyokika Kyo* 1985;31(6):937-48. [article in Japanese]
<http://www.ncbi.nlm.nih.gov/pubmed/4061211>
10. Casado JS, Virseda Chamorro M, Leva Vallejo M, Fernandez Lucas C, Aristizabal Agudelo JM, de la Fuente Trabado M. [Urodynamic assessment of the voiding phase in childhood.] *Arch Esp Urol* 2002;55(2):177-89. [article in Spanish]
<http://www.ncbi.nlm.nih.gov/pubmed/12014050>
11. Wen JG, Yeung CK, Djurhuus JC. Cystometry techniques in female infants and children. *Int Urogynecol J Pelvic Floor Dysfunct* 2000;11(2):103-12.
<http://www.ncbi.nlm.nih.gov/pubmed/10805268>
12. Bradley CS, Smith KE, Kreder KJ. Urodynamic evaluation of the bladder and pelvic floor. *Gastroenterol Clin North Am* 2008;37(3):539-52.
<http://www.ncbi.nlm.nih.gov/pubmed/18793995>
13. Norgaard JP, van Gool JD, Hjalmas K, Djurhuus JC, Hellstrom AL. Standardization and definitions in lower urinary tract dysfunction in children. International Children's Continence Society. *Br J Urol* 1998;81(Suppl 3):1-16.
<http://www.ncbi.nlm.nih.gov/pubmed/9634012>
14. Bauer SB. Pediatric urodynamics: lower tract. In: O'Donnell B, Koff SA, eds. *Pediatric urology*. Oxford: Butterworth-Heinemann, 1998, pp. 125-151.
15. Tanikaze S, Sugita Y. [Cystometric examination for neurogenic bladder of neonates and infants.] *Hinyokika Kyo* 1991;37(11):1403-5. [article in Japanese]
<http://www.ncbi.nlm.nih.gov/pubmed/1767767>
16. Zoller G, Schoner W, Ringert RH. Pre- and postoperative urodynamic findings in children with tethered spinal cord syndrome. *Eur Urol* 1991;19(2):139-41.
<http://www.ncbi.nlm.nih.gov/pubmed/2022217>
17. Ghoniem GM, Roach MB, Lewis VH, Harmon EP. The value of leak pressure and bladder compliance in the urodynamic evaluation of meningomyelocele patients. *J Urol* 1990;144(6):1440-2.
<http://www.ncbi.nlm.nih.gov/pubmed/2231938>
18. Ghoniem GM, Shoukry MS, Hassouna ME. Detrusor properties in myelomeningocele patients: in vitro study. *J Urol* 1998;159(6):2193-6.
<http://www.ncbi.nlm.nih.gov/pubmed/9598568>

19. Palmer LS, Richards I, Kaplan WE. Age related bladder capacity and bladder capacity growth in children with myelomeningocele. *J Urol* 1997;158:1261-4.
<http://www.ncbi.nlm.nih.gov/pubmed/9258190>
20. Agarwal SK, McLorie GA, Grewal D, Joyner BD, Bagli DJ, Khoury AE. Urodynamic correlates of resolution of reflux in meningomyelocele patients. *J Urol* 1997;158 (3 Pt 2):580-2.
<http://www.ncbi.nlm.nih.gov/pubmed/9224367>
21. Zermann DH, Lindner H, Huschke T, Schubert J. Diagnostic value of natural fill cystometry in neurogenic bladder in children. *Eur Urol* 1997;32(2):223-8.
<http://www.ncbi.nlm.nih.gov/pubmed/9286658>
22. Webb RJ, Griffiths CJ, Ramsden PD, Neal DE. Measurement of voiding pressures on ambulatory monitoring: comparison with conventional cystometry. *Br J Urol* 1990;65(2):152-4.
<http://www.ncbi.nlm.nih.gov/pubmed/2317646>
23. McLnerney PD, Vanner TF, Harris SA, Stephenson TP. Ambulatory urodynamics. *Br J Urol* 1991;67(3):272-4.
<http://www.ncbi.nlm.nih.gov/pubmed/2021814>
24. Yeung CK, Godley ML, Duffy PG, Ransley PG. Natural filling cystometry in infants and children. *Br J Urol* 1995;75(4):531-7.
<http://www.ncbi.nlm.nih.gov/pubmed/7788266>
25. Swithinbank LV, James M, Shepherd A, Abrams P. Role of ambulatory urodynamic monitoring in clinical urological practice. *Neurourol Urodyn* 1999;18(3):215-22.
<http://www.ncbi.nlm.nih.gov/pubmed/10338442>
26. McGuire EJ, Woodside JR, Borden TA, Weiss RM. Prognostic value of urodynamic testing in myelodysplastic patients. 1981. *J Urol* 2002;167(2 Pt 2):1049-53.
<http://www.ncbi.nlm.nih.gov/pubmed/11905876>
27. Sillen U, Hansson E, Hermansson G, Hjalmas, Jacobsson B, Jodal U. Development of the urodynamic pattern in infants with myelomeningocele. *Br J Urol* 1996;78(4):596-601.
<http://www.ncbi.nlm.nih.gov/pubmed/8944517>
28. Tarcan T, Bauer S, Olmedo E, Khoshbin S, Kelly M, Darbey M. Long-term follow-up of newborns with myelodysplasia and normal urodynamic findings: is follow-up necessary? *J Urol* 2001;165(2):564-7.
<http://www.ncbi.nlm.nih.gov/pubmed/11176436>
29. Kasabian NG, Bauer SB, Dyro FM, Colodny AH, Mandell J, Retik AB. The prophylactic value of clean intermittent catheterization and anticholinergic medication in newborns and infants with myelodysplasia at risk of developing urinary tract deterioration. *Am J Dis Child* 1992;146(7):840-3.
<http://www.ncbi.nlm.nih.gov/pubmed/1496955>
30. Wang SC, McGuire EJ, Bloom DA. Urethral dilatation in the management of urological complications of myelodysplasia. *J Urol* 1989;142(4):1054-5.
<http://www.ncbi.nlm.nih.gov/pubmed/2795730>
31. Lin-Dyken DC, Wolraich ML, Hawtrey CE, Doja MS. Follow-up of clean intermittent catheterization for children with neurogenic bladders. *Urology* 1992;40(6):525-9.
<http://www.ncbi.nlm.nih.gov/pubmed/1466106>
32. Kaufman AM, Ritchey ML, Roberts AC, Rudy DC, McGuire EJ. Decreased bladder compliance in patients with myelomeningocele treated with radiological observation. *J Urol* 1996;156(6):2031-3.
<http://www.ncbi.nlm.nih.gov/pubmed/8965337>
33. Wu HY, Baskin LS, Kogan BA. Neurogenic bladder dysfunction due to myelomeningocele: neonatal versus childhood treatment. *J Urol* 1997;157(6):2295-7.
<http://www.ncbi.nlm.nih.gov/pubmed/9146656>
34. Kaefer M, Pabby A, Kelly M, Darbey M, Bauer SB. Improved bladder function after prophylactic treatment of the high risk neurogenic bladder in newborns with myelomeningocele. *J Urol* 1999;162 (3 Pt 2):1068-71.
<http://www.ncbi.nlm.nih.gov/pubmed/10458433>
35. van Gool JD, Dik P, de Jong TP. Bladder-sphincter dysfunction in myelomeningocele. *Eur J Pediatr* 2001;160(7):414-20.
<http://www.ncbi.nlm.nih.gov/pubmed/11475578>
36. Bauer SB. The argument for early assessment and treatment of infants with spina bifida. *Dialogues in Pediatric Urology* 2000;23:2-3.
37. Park JM. Early reduction of mechanical load of the bladder improves compliance: experimental and clinical observations. *Dialogues in Pediatric Urology* 2000;23:6-7.
38. Lindehall B, Moller A, Hjalmas K, Jodal U. Long-term intermittent catheterization: the experience of teenagers and young adults with myelomeningocele. *J Urol* 1994;152(1):187-9.
<http://www.ncbi.nlm.nih.gov/pubmed/8201663>

39. Joseph DB, Bauer SB, Colodny AH, Mandell J, Retik AB. Clean intermittent catheterization in infants with neurogenic bladder. *Pediatrics* 1989;84(1):72-82.
<http://www.ncbi.nlm.nih.gov/pubmed/2740179>
40. Baskin LS, Kogan BA, Benard F. Treatment of infants with neurogenic bladder dysfunction using anticholinergic drugs and intermittent catheterization. *Br J Urol* 1990;66(5):532-4.
<http://www.ncbi.nlm.nih.gov/pubmed/2249125>
41. Connor JP, Betrus G, Fleming P, Perlmutter AD, Reitelman C. Early cystometrograms can predict the response to intravesical instillation of oxybutynin chloride in myelomeningocele patients. *J Urol* 1994;151(4):1045-7.
<http://www.ncbi.nlm.nih.gov/pubmed/8126787>
42. Goessel C, Knispel HH, Fiedler U, Harle B, Steffen-Wilke K, Miller K. Urodynamic effects of oral oxybutynin chloride in children with myelomeningocele and detrusor hyperreflexia. *Urology* 1998;51(1):94-8.
<http://www.ncbi.nlm.nih.gov/pubmed/9457296>
43. Haferkamp A, Staehler G, Gerner HJ, Dorsam J. Dosage escalation of intravesical oxybutynin in the treatment of neurogenic bladder patients. *Spinal Cord* 2000;38(4):250-4.
<http://www.ncbi.nlm.nih.gov/pubmed/10822396>
44. Ferrara P, D'Aleo CM, Tarquini E, Salvatore S, Salvaggio E. Side-effects of oral or intravesical oxybutynin chloride in children with spina bifida. *BJU Int* 2001;87(7):674-8.
<http://www.ncbi.nlm.nih.gov/pubmed/11350411>
45. Ellsworth PI, Borgstein NG, Nijman RJ, Reddy PP. Use of tolterodine in children with neurogenic detrusor overactivity: relationship between dose and urodynamic response. *J Urol*. 2005 Oct;174(4Pt2):1647-51.
<http://www.ncbi.nlm.nih.gov/pubmed/16148673>
46. Mahanta K, Medhi B, Kaur B, Narasimhan KL. Comparative efficacy and safety of extended-release and instant-release tolterodine in children with neural tube defects having cystometric abnormalities. *J Pediatr Urol* 2008;4(2):118-23.
<http://www.ncbi.nlm.nih.gov/pubmed/18631906>
47. Franco I. Overactive bladder in children. Part 2: Management. *J Urol* 2007;178(3Pt1):769-74; discussion 774.
<http://www.ncbi.nlm.nih.gov/pubmed/17631332>
48. Austin PF, Homsy YL, Masel JL, Cain MP, Casale AJ, Rink RC. Alpha-adrenergic blockade in children with neuropathic and nonneuropathic voiding dysfunction. *J Urol* 1999;162(3 Pt 2):1064-7.
<http://www.ncbi.nlm.nih.gov/pubmed/10458432>
49. Smith CP, Somogyi GT, Chancellor MB. Emerging role of botulinum toxin in the treatment of neurogenic and non-neurogenic voiding dysfunction. *Curr Urol Rep* 2002;3(5):382-7.
<http://www.ncbi.nlm.nih.gov/pubmed/12354347>
50. Leippold T, Reitz A, Schurch B. Botulinum toxin as a new therapy option for voiding disorders: current state of the art. *Eur Urol* 2003;44(2):165-74.
<http://www.ncbi.nlm.nih.gov/pubmed/12875934>
51. Schulte-Baukloh H, Knispel HH, Michael T. Botulinum-A toxin in the treatment of neurogenic bladder in children. *Paediatrics* 2002;110(2 Pt 1):420-1.
<http://www.ncbi.nlm.nih.gov/pubmed/12165609>
52. Lusuardi L, Nader A, Koen M, Schrey A, Schindler M, Riccabona M. [Minimally invasive, safe treatment of the neurogenic bladder with botulinum-A-toxin in children with myelomeningocele.] *Aktuelle Urol* 2004;35(1):49-53. [article in German]
<http://www.ncbi.nlm.nih.gov/pubmed/14997415>
53. Hoebeke P, De Caestecker K, Vande Walle J, Dehoorne J, Raes A, Verleyen P, Van Laecke E. The effect of botulinum-A toxin in incontinent children with therapy resistant overactive detrusor. *J Urol* 2006;176(1):328-30.
<http://www.ncbi.nlm.nih.gov/pubmed/16753434>
54. Kajbafzadeh AM, Moosavi S, Tajik P, Arshadi H, Payabvash S, Salmasi AH, Akbari HR, Nejat F. Intravesical injection of botulinum toxin type A: management of neuropathic bladder and bowel dysfunction in children with myelomeningocele. *Urology* 2006;68(5):1091-6.
<http://www.ncbi.nlm.nih.gov/pubmed/17113899>
55. Akbar M, Abel R, Seyler TM, Bedke J, Haferkamp A, Gerner HJ, Möhring K. Repeated botulinum-A toxin injections in the treatment of myelodysplastic children and patients with spinal cord injuries with neurogenic bladder dysfunction. *BJU Int* 2007;100(3):639-45. Erratum in: *BJU Int* 2007;100(3):719.
<http://www.ncbi.nlm.nih.gov/pubmed/17532858>

56. Mokhless I, Gaafar S, Fouda K, Shafik M, Assem A. Botulinum A toxin urethral sphincter injection in children with nonneurogenic neurogenic bladder. *J Urol*. 2006 Oct;176(4Pt2):1767-70.
<http://www.ncbi.nlm.nih.gov/pubmed/16945643>
57. Younoszai MK. Stooling problems in patients with myelomeningocele. *South Med J* 1992;85(7)8-24.
<http://www.ncbi.nlm.nih.gov/pubmed/1631686>
58. Squire R, Kiely EM, Carr B, Ransley PG, Duffy PG. The clinical application of the Malone antegrade colonic enema. *J Pediatr Surg* 1993;28(8):1012-5.
<http://www.ncbi.nlm.nih.gov/pubmed/8229586>
59. Whitehead WE, Wald A, Norton NJ. Treatment options for fecal incontinence. *Dis Colon Rectum* 2001;44(1):131-42 ; discussion 142-4.
<http://www.ncbi.nlm.nih.gov/pubmed/11805574>
60. Krogh K, Kvitzau B, Jorgensen TM, Laurberg S. [Treatment of anal incontinence and constipation with transanal irrigation.] *Ugeskr Laeger* 1999;161(3):253-6. [article in Danish]
<http://www.ncbi.nlm.nih.gov/pubmed/10025223>
61. Van Savage JG, Yohannes P. Laparoscopic antegrade continence enema in situ appendix procedure for refractory constipation and overflow fecal incontinence in children with spina bifida. *J Urol* 2000;164(3 Pt 2):1084-7.
<http://www.ncbi.nlm.nih.gov/pubmed/10958747>
62. Aksnes G, Diseth TH, Helseth A, Edwin B, Stange M, Aafos G, Emblem R. Appendicostomy for antegrade enema: effects on somatic and psychosocial functioning in children with myelomeningocele. *Pediatrics* 2002;109(3):484-9.
<http://www.ncbi.nlm.nih.gov/pubmed/11875145>
63. Loening-Baucke V, Desch L, Wolraich M. Biofeedback training for patients with myelomeningocele and fecal incontinence. *Dev Med Child Neurol* 1988;30(6):781-90.
<http://www.ncbi.nlm.nih.gov/pubmed/3234607>
64. Marshall DF, Boston VE. Altered bladder and bowel function following cutaneous electrical field stimulation in children with spina bifida—interim results of a randomized double-blind placebo-controlled trial. *Eur J Pediatr Surg* 1997;7(Suppl 1):41-3.
<http://www.ncbi.nlm.nih.gov/pubmed/9497117>
65. Hansson S, Caugant D, Jodal U, Svanborg-Eden C. Untreated asymptomatic bacteriuria in girls: I - Stability of urinary isolates. *BMJ* 1989;298(6677):853-5.
<http://www.ncbi.nlm.nih.gov/pubmed/2497822>
66. Hansson S, Jodal U, Lincoln K, Svanborg-Eden C. Untreated asymptomatic bacteriuria in girls: II - Effect of phenoxymethylpenicillin and erythromycin given for intercurrent infections. *BMJ* 1989;298(6677):856-9.
<http://www.ncbi.nlm.nih.gov/pubmed/2497823>
67. Hansson S, Jodal U, Noren L, Bjure J. Untreated bacteriuria in asymptomatic girls with renal scarring. *Pediatrics* 1989;84(6):964-8.
<http://www.ncbi.nlm.nih.gov/pubmed/2587151>
68. Johnson HW, Anderson JD, Chambers GK, Arnold WJ, Irwin WJ, Brinton JR. A short-term study of nitrofurantoin prophylaxis in children managed with clean intermittent catheterization. *Pediatrics* 1994;93(5):752-5.
<http://www.ncbi.nlm.nih.gov/pubmed/8165073>
69. Schlager TA, Anderson S, Trudell J, Hendley JO. Nitrofurantoin prophylaxis for bacteriuria and urinary tract infection in children with neurogenic bladder on intermittent catheterization. *J Pediatr* 1998;132(4):704-8.
<http://www.ncbi.nlm.nih.gov/pubmed/9580774>
70. Nguyen DH, Mitchell ME. Gastric bladder reconstruction. *Urol Clin North Am* 1991;18(4):649-57.
<http://www.ncbi.nlm.nih.gov/pubmed/1949398>
71. Duel BP, Gonzalez R, Barthold JS. Alternative techniques for augmentation cystoplasty. *J Urol* 1998;159(3):998-1005.
<http://www.ncbi.nlm.nih.gov/pubmed/9474216>
72. Bandi G, Al-Omar O, McLorie GA. Comparison of traditional enterocystoplasty and seromuscular colocolocystoplasty lined with urothelium. *J Pediatr Urol* 2007;3(6):484-9.
<http://www.ncbi.nlm.nih.gov/pubmed/18947800>
73. Atala A, Bauer SB, Soker S, Yoo JJ, Retik AB. Tissue-engineered autologous bladders for patients needing cystoplasty. *Lancet* 2006;367(9518):1241-6.
<http://www.ncbi.nlm.nih.gov/pubmed/16631879>

74. Naglo AS. Continence training of children with neurogenic bladder and detrusor hyperactivity: effect of atropine. *Scan J Urol Nephrol* 1982;16(3):211-5.
<http://www.ncbi.nlm.nih.gov/pubmed/7163785>
75. Austin PF, Westney OL, Leng WW, McGuire EJ, Ritchey ML. Advantages of rectus fascial slings for urinary incontinence in children with neuropathic bladders. *J Urol* 2001;165(6 Pt 2):2369-71.
<http://www.ncbi.nlm.nih.gov/pubmed/11398778>
76. Guys JM, Fakhro A, Louis-Borrione C, Prost J, Hautier A. Endoscopic treatment of urinary incontinence: long-term evaluation of the results. *J Urol* 2001;165(6 Pt 2):2389-91.
<http://www.ncbi.nlm.nih.gov/pubmed/11371983>
77. Kassouf W, Capolicchio G, Bernardinucci G, Corcos J. Collagen injection for treatment of urinary incontinence in children. *J Urol* 2001;165(5):1666-8.
<http://www.ncbi.nlm.nih.gov/pubmed/11342951>
78. Kryger JV, Leveson G, Gonzalez R. Long-term results of artificial urinary sphincters in children are independent of age at implantation. *J Urol* 2001;165(6 Pt 2):2377-9.
<http://www.ncbi.nlm.nih.gov/pubmed/11371981>
79. Holmes NM, Kogan BA, Baskin LS. Placement of artificial urinary sphincter in children and simultaneous gastrocystoplasty. *J Urol* 2001;165(6 Pt 2):2366-8.
<http://www.ncbi.nlm.nih.gov/pubmed/11371944>
80. Mitchell ME, Piser JA. Intestinocystoplasty and total bladder replacement in children and young adults: follow up in 129 cases. *J Urol* 1987;138(3):579-84.
<http://www.ncbi.nlm.nih.gov/pubmed/3625861>
81. Shekarriz B, Upadhyay J, Demirbilek S, Barthold JS, Gonzalez R. Surgical complications of bladder augmentation: comparison between various enterocystoplasties in 133 patients. *Urology* 2000;55(1):123-8.
<http://www.ncbi.nlm.nih.gov/pubmed/10654908>
82. Medel R, Ruarte AC, Herrera M, Castera R, Podesta ML. Urinary continence outcome after augmentation ileocystoplasty as a single surgical procedure in patients with myelodysplasia. *J Urol* 2002;168(4 Pt 2):1849-52.
<http://www.ncbi.nlm.nih.gov/pubmed/12352374>
83. Metcalfe PD, Rink RC. Bladder augmentation: complications in the pediatric population. *Curr Urol Rep.* 2007 Mar;8(2):152-6.
<http://www.ncbi.nlm.nih.gov/pubmed/17303021>

13. DILATATION OF THE UPPER URINARY TRACT (URETEROPELVIC JUNCTION AND URETEROVESICAL JUNCTION OBSTRUCTION)

13.1 Background

Dilatation of the upper urinary tract still presents a significant clinical challenge in determining which patient may gain benefit by therapy.

Ureteropelvic junction (UPJ) obstruction is defined as impaired urine flow from the pelvis into the proximal ureter with subsequent dilatation of the collecting system and the potential to damage the kidney. It is the most common cause of neonatal hydronephrosis (1). It has an overall incidence of 1:1500 and a ratio of males to females of 2:1 in newborns.

Ureterovesical junction (UVJ) obstruction is an obstructive condition of the distal ureter as it enters the bladder, commonly called a primary obstructive megaureter. Megaureters are ranked as second in the differential diagnosis of neonatal hydronephrosis. They occur more often in males and are more likely to occur on the left side (2).

Much more difficult is the definition of obstruction. Creating a divide between 'obstructed' and 'non-obstructed' urinary tracts, as if entities could be as clearly differentiated as 'black' and 'white', is impossible. Currently, the most popular definition is that obstruction represents any restriction to urinary outflow that, if left untreated, will cause progressive renal deterioration (3).

13.2 Diagnosis

Due to the widespread use of ultrasonography during pregnancy, antenatal hydronephrosis is being detected

with increasing frequency (4). The challenge in the management of dilated upper urinary tracts is to decide which child can be observed, which one should be managed medically, and which one requires surgical intervention. There is no single definitive test able to distinguish obstructive from non-obstructive cases (Figure 1).

13.2.1 Antenatal ultrasound

Usually between the 16th and 18th weeks of pregnancy, the kidneys are visualised routinely, when almost all amniotic fluid consists of urine. The most sensitive time for fetal urinary tract evaluation is the 28th week. If dilatation is detected, ultrasound should focus on the laterality, severity of dilatation, and echogenicity of the kidneys, hydronephrosis or hydro-ureteronephrosis, bladder volume and bladder emptying, sex of the child, and amniotic fluid volume, respectively (5).

13.2.2 Postnatal ultrasound

Since transitory neonatal dehydration lasts about 48 hours, imaging should be performed after this period of postnatal oliguria. In severe cases (bilateral dilatation, solitary kidney, oligohydramnios), immediate postnatal sonography is recommended (6). During ultrasound examination, the anteroposterior diameter of the renal pelvis, calyceal dilatation, kidney size, thickness of the parenchyma, cortical echogenicity, ureters, bladder wall and residual urine are assessed.

13.2.3 Voiding cystourethrogram (VCUG)

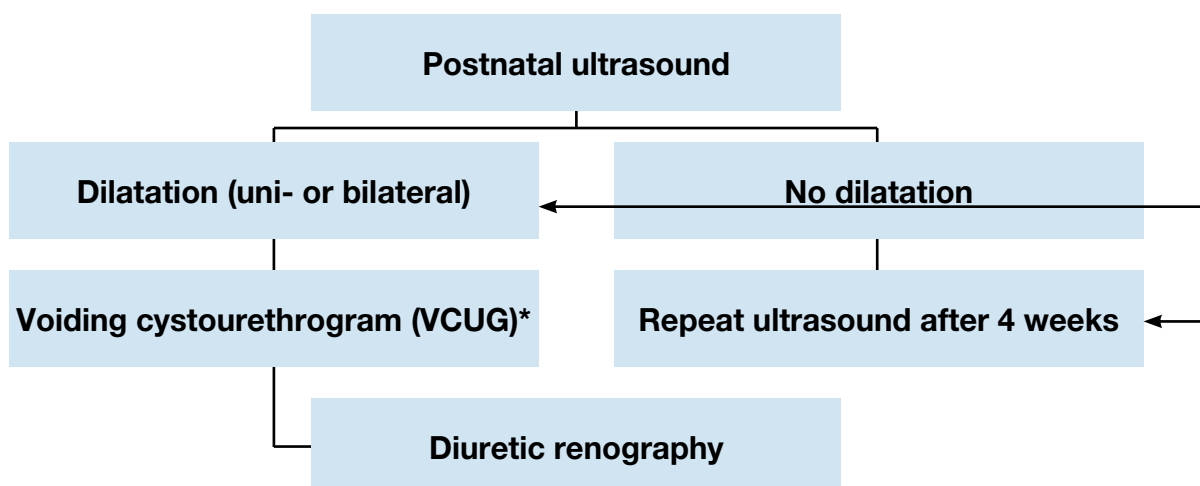
In newborns with identified upper urinary tract dilatation, the presence of primary or important associated factors that must be detected include vesicoureteral reflux in up to 25% of affected children (15), urethral valves, ureteroceles, diverticula and neurogenic bladder. Conventional VCUG is the method of choice for primary diagnostic procedures (7).

13.2.4 Diuretic renography

Diuretic renography is the most commonly used diagnostic tool to detect the severity and functional significance of urine transport problems. ^{99m}Tc-MAG3 is the radionuclide of choice. It is important to perform the study under standardised circumstances (hydration, transurethral catheter) between the fourth and sixth weeks of life (8).

Oral fluid intake is encouraged prior to examination. Fifteen minutes before injection of the radionuclide, it is mandatory to give normal saline intravenous infusion at a rate of 15 ml/kg over 30 minutes and then at a maintenance rate of 4 ml/kg/hour throughout the whole time of the investigation (9). The recommended dose of furosemide is 1 mg/kg for infants during the first year of life, while 0.5 mg/kg should be given to children aged 1 to 16 years up to a maximum dose of 40 mg.

Figure 2. Diagnostic algorithm for dilatation of the upper urinary tract



* A diagnostic work-up including VCUG has to be discussed with the parents since a possibly detected reflux might have absolutely no clinical impact. On the other hand, a reflux rate of up to 25% in cases of prenatally detected and postnatally confirmed hydronephrosis is reported in the literature (15) and might therefore have some forensic impact as well.

13.3 Treatment

13.3.1 Prenatal management

Counselling the parents is one of the most important aspects of care. The prognosis for an hydronephrotic kidney, even if severely affected, is hopeful. An hydronephrotic kidney may still be capable of providing meaningful renal function, whereas a severely hypoplastic and dysplastic kidney has a hopeless outlook. It is important to explain to the parents the timing and accuracy of establishing the definitive diagnosis for their child. In some cases, there is an obvious indication of severity, including massive bilateral dilatation, bilateral evidence of hypoplastic dysplasia, progressive bilateral dilatation with oligohydramnios, and pulmonary hypoplasia.

Intrauterine intervention is rarely indicated and should only be performed in well-experienced centres (10).

13.3.2 UPJ obstruction

It is most important to make the decision on the basis of serial investigations, applying the same technique and performed by the same institution under standardised circumstances. Symptomatic obstruction (recurrent flank pain, urinary tract infection) requires surgical correction using a pyeloplasty, according to the standardised open technique of Hynes and Anderson (11). Recently, increasingly more data have become available supporting the use of a laparoscopic or retroperitoneoscopic approach to achieve a dismembered pyeloplasty. In addition, laparoscopic suturing has been improved by the use of robotics (16). However, these methods lack very long-term data and will require time to be fully proven. In asymptomatic cases, conservative follow-up can be the treatment of choice.

Indications for surgical intervention are an impaired split renal function (< 40%), a decrease of split renal function of more than 10% in subsequent studies, increased anteroposterior diameter on the ultrasound, and grade III and IV dilatation as defined by the Society for Fetal Urology.

13.4 Megaureter

Concerning the treatment options of secondary megaureters (see Chapter 14, reflux and valves).

If a functional study reveals and confirms adequate ureteral drainage, conservative management is the best option. Initially, low-dose prophylactic antibiotics within the first year of life are recommended for prevention of urinary tract infections, although there are no prospective randomised trials to evaluate this regimen (12).

With spontaneous remission rates of up to 85% in primary megaureter cases, surgical management is no longer recommended, except for megaureters with recurrent urinary tract infections, deterioration of split renal function and significant obstruction (13).

The initial approach to the ureter can be either intravesical, extravesical, or combined. Straightening the ureter is necessary without devascularisation. Ureteral tapering should enhance urinary flow into the bladder. The ureter must be tapered to achieve a diameter for an antireflux repair. There are several tailoring techniques, e.g. ureteral imbrication or excisional tapering (14).

13.5 Conclusion

With the use of routine perinatal sonography, hydronephrosis caused by UPJ or UVJ obstruction is now increasingly recognised. Meticulous and repeat postnatal evaluation is mandatory to try to identify any obstructive cases at risk of renal deterioration and requiring surgical reconstruction. Surgical methods are fairly standardised and have a good clinical outcome.

13.6 REFERENCES

1. Lebowitz RL, Griscom NT. Neonatal hydronephrosis: 146 cases. *Radiol Clin North Am* 1977;15(1):49-59.
<http://www.ncbi.nlm.nih.gov/pubmed/139634>
2. Brown T, Mandell J, Lebowitz RL. Neonatal hydronephrosis in the era of sonography. *Am J Roentgenol* 1987;148(5):959-63.
<http://www.ncbi.nlm.nih.gov/pubmed/3034009>
3. Koff SA. Problematic ureteropelvic junction obstruction. *J Urol* 1987;138(2):390.
<http://www.ncbi.nlm.nih.gov/pubmed/3599261>
4. Gunn TR, Mora JD, Pease P. Antenatal diagnosis of urinary tract abnormalities by ultrasonography after 28 weeks' gestation: incidence and outcome. *Am J Obstet Gynecol* 1995;172(2 Pt 1):479-86.
<http://www.ncbi.nlm.nih.gov/pubmed/7856673>
5. Grignon A, Filiatrault D, Homsy Y, Robitaille P, Filion R, Boutin H, Leblond R. Ureteropelvic junction stenosis: antenatal ultrasonographic diagnosis, postnatal investigation, and follow-up. *Radiology* 1986;160:649-51.
<http://www.ncbi.nlm.nih.gov/pubmed/3526403>

6. Flashner SC, King LR. Ureteropelvic junction. In: *Clinical Pediatric Urology*. Philadelphia: WB Saunders, 1976, p. 693.
7. Ebel KD. Uroradiology in the fetus and newborn: diagnosis and follow-up of congenital obstruction of the urinary tract. *Pediatr Radiol* 1998;28(8):630-5.
<http://www.ncbi.nlm.nih.gov/pubmed/9716640>
8. O'Reilly P, Aurell M, Britton K, Kletter K, Rosenthal L, Testa T. Consensus on diuresis renography for investigating the dilated upper urinary tract. Radionuclides in Nephrourology Group. Consensus Committee on Diuresis Renography. *J Nucl Med* 1996;37(11):1872-6.
<http://www.ncbi.nlm.nih.gov/pubmed/8917195>
9. Choong KK, Gruenewald SM, Hodson EM, Antico VF, Farlow DC, Cohen RC. Volume expanded diuretic renography in the postnatal assessment of suspected uretero-pelvic junction obstruction. *J Nucl Med* 1992;33:2094-8.
<http://www.ncbi.nlm.nih.gov/pubmed/1460498>
10. Reddy PP, Mandell J. Prenatal diagnosis. Therapeutic implications. *Urol Clin North Am* 1998;25(2):171-80.
<http://www.ncbi.nlm.nih.gov/pubmed/9633572>
11. Novick AC, Stroom AB. Surgery of the kidney. In: Walsh PC, Retik AB, Vaughan ED, Wein AJ (eds). *Campbell's Urology*. Philadelphia: WB Saunders, 1998, p. 3044.
12. Arena F, Baldari S, Proietto F, Centorrino A, Scalfari G, Romeo G. Conservative treatment in primary neonatal megaureter. *Eur J Pediatr Surg* 1998;8(6):347-351.
<http://www.ncbi.nlm.nih.gov/pubmed/9926303>
13. Peters CA, Mandell J, Lebowitz RL, Colodny AH, Bauer SB, Hendren WH, Retik AB. Congenital obstructed megaureters in early infancy: diagnosis and treatment. *J Urol* 1989;142(2 Pt 2):641-5.
<http://www.ncbi.nlm.nih.gov/pubmed/2746792>
14. Sripathi V, King PA, Thomson MR, Bogle MS. Primary obstructive megaureter. *J Pediatr Surg* 1991;26(7):826-9.
<http://www.ncbi.nlm.nih.gov/pubmed/1895193>
15. Thomas DF. Prenatally detected uropathy: epidemiological considerations. *Br J Urol* 1998;81(Suppl 2):8-12.
<http://www.ncbi.nlm.nih.gov/pubmed/9602790>
16. Olsen LH, Rawashdeh YF, Jorgensen TM. Pediatric robot assisted retroperitoneoscopic pyeloplasty: a 5-year experience. *J Urol* 2007;178(5):2137-41.
<http://www.ncbi.nlm.nih.gov/pubmed/17870122>

14. VESICoureTERIC REFLUX (VUR)

14.1 Background

Vesicoureteric reflux (VUR) is a very common urological anomaly in children and is probably one of the most controversial issues in paediatrics (1). Vesicoureteric reflux is defined as the non-physiological back-flow of urine from the urinary bladder into the ureter or the renal pelvis and the calyces. While primary VUR is a congenital anomaly of the ureterovesical junction with a genetic basis (2), secondary reflux is caused by an anatomical or functional bladder outflow obstruction and subsequently elevated pressures or inflammatory diseases. Primary VUR can be associated with other morphological and/or functional abnormalities of the lower urinary tract.

About 1-2% of all children have VUR, while VUR occurs in 25-40% of children with acute pyelonephritis (1). In newborns, the incidence of reflux is higher in boys than in girls, but in later life, girls are approximately 4-6 times more frequently affected than boys. The incidence of prenatally diagnosed hydronephrosis caused by VUR ranges from 17-37% (3, 4). About 30-50% of children with symptomatic VUR have radiological evidence of renal scarring, resulting from congenital dysplasia and/or acquired post-infectious damage. Intrarenal reflux of infected urine appears to be primarily responsible for the renal damage.

Reflux nephropathy (RN) may be the most common cause of childhood hypertension. Follow-up studies show that about 10-20% of children with RN develop hypertension or end-stage renal disease (5). Older studies have consistently attributed 15-30% of chronic renal failure in children and young adults to chronic pyelonephritis and RN (6). However, an awareness of VUR-related morbidity has led to more widespread diagnosis and treatment, which appears to have resulted in a decrease in the number of affected patients with RN. The diagnosis and treatment of VUR has therefore altered the epidemiology of hypertension and renal failure in children and young adults. In a recent series of renal transplant populations, approximately

2-3% of cases were related to chronic pyelonephritis (7).

Twin and family studies have revealed that VUR has a genetic basis (2). Siblings of patients with known reflux have an approximately 30% prevalence of reflux, with younger siblings being at greatest risk. Offspring of parents with reflux have an almost 70% risk of developing reflux. Since siblings and offspring of sufferers are mostly asymptomatic, it is advised that they should be routinely screened for reflux (8, 9).

The management of affected children has been directed at preventing infection and permanent renal parenchymal damage and its late complications by antibiotic prophylaxis and/or surgical correction of reflux. However, controversy remains regarding the optimal strategies for management of children with primary VUR (10-12).

14.2 Classification

In 1985, the International Reflux Study Committee introduced a uniform system for the classification of VUR (13) (Table 1). The grading system combines two earlier classifications and is based upon the extent of retrograde filling and dilatation of the ureter, the renal pelvis and the calyces on a VCUG. The Committee also described a standardized technique of VCUG to allow comparability of results.

Table 1: Grading system for vesicoureteric reflux, according to the International Reflux Study Committee (13)

Grade I	Reflux does not reach the renal pelvis; varying degrees of ureteral dilatation
Grade II	Reflux reaches the renal pelvis; no dilatation of the collecting system; normal fornices
Grade III	Mild or moderate dilatation of the ureter, with or without kinking; moderate dilatation of the collecting system; normal or minimally deformed fornices
Grade IV	Moderate dilatation of the ureter with or without kinking; moderate dilatation of the collecting system; blunt fornices, but impressions of the papillae still visible
Grade V	Gross dilatation and kinking of the ureter, marked dilatation of the collecting system; papillary impressions no longer visible; intraparenchymal reflux

14.3 Diagnostic work-up

A basic diagnostic work-up comprises a detailed medical history (including family history), physical examination, urinalysis, urine culture and, if renal function needs to be assessed, serum creatinine level. Diagnostic imaging for VUR encompasses both radiological and sonographic modalities (14). Radiological modalities comprise VCUG, the most widespread method for examination of reflux, and radionuclide cystography (RNC).

In RNC, radiation exposure is significantly lower than in VCUG with continuous fluoroscopy, but the anatomical details depicted are much more inferior. With the introduction of pulsed fluoroscopy, the radiation exposure of VCUG could be markedly reduced. The use of VCUG allows the grade of reflux to be determined (in a single or duplicated kidney) and the assessment of bladder and ureteral configuration. Moreover, VCUG is the study of choice for imaging the urethra. The sonographic diagnosis of VUR with intravesical administration of an ultrasound (US) contrast agent (voiding urosonography [VUS]) is mostly used as the primary reflux examination modality in girls and during follow-up.

In complex cases, magnetic resonance urography may be required for evaluation of the upper urinary tract.

Dimercaptosuccinic acid (DMSA) is the best nuclear agent for visualizing cortical tissue, evaluating renal parenchyma, and documenting the presence of renal scars. Children with normal DMSA during an acute UTI have a low risk of renal damage. Children with normal follow-up DMSA and low-grade VUR have more frequent spontaneous resolution of VUR (15).

In the case of incontinence or residual urine, urodynamic studies can be performed to reveal functional abnormalities of the lower urinary tract. Such testing is most important in patients in whom secondary reflux is suspected, such as patients with spina bifida or boys whose VCUG is suggestive of residual posterior urethral valves. Yet, in most cases of non-neurogenic voiding dysfunction, diagnosis and follow-up can be limited to non-invasive tests (voiding charts, US, uroflowmetry). In the few remaining children with inconclusive findings and who are refractory to treatment, urodynamic tests are necessary. Appropriate management of voiding dysfunction will often result in the resolution of reflux (16).

In the past, cystoscopy was considered to be essential for the assessment of VUR. The position and shape of the ureteral orifices were thought to correlate with the grade and prognosis. Subsequent data have demonstrated that cystoscopic observations do not contribute significantly to the outcome of management (17). Cystoscopy may be performed at the time of open surgery to identify additional anatomical abnormalities, such as ureteral duplication and ureteral ectopia.

14.4 Treatment

Early diagnosis and vigilant monitoring are the cornerstones of treatment (Table 2). The ultimate objective of treatment is to allow normal renal growth and to prevent permanent renal parenchymal damage and its late complications (reflux nephropathy, see above). There is no single therapeutic strategy for all clinical settings of VUR.

Therapeutic options comprise conservative (medical) management, including antibiotic prophylaxis, and interventional approaches (i.e. endoscopic subureteral injection, laparoscopic or open surgical correction of reflux), in isolation or combined.

The individual choice of management is based on the presence of renal scars, the clinical course, grade of reflux, ipsilateral renal function, bilaterality, bladder capacity and function, associated anomalies of the urinary tract, age, compliance and parental preference.

Surgical correction is warranted in recurrent febrile infections despite antibiotic prophylaxis (breakthrough infections), medical non-compliance, and new scars and in the presence of associated malformations (e.g. duplex systems, Hutch diverticulum, ectopic ureter).

In secondary VUR, the objective of management is treatment of the underlying condition. If VUR persists after successful therapy of the underlying condition, further management depends on the individual clinical setting.

Table 2: Treatment of reflux

Patient's age	Grade of reflux/Gender	Management
< 1 year		Conservative
1-5 year (s)	Grade I-III	Conservative
	Grade IV-V	Surgical correction
> 5 years	Boys	Indication for surgery is rare
	Girls	Surgical correction

14.4.1 Conservative approach

The rationale for conservative management is the observation that VUR can resolve spontaneously with time, mostly in young patients with low-grade reflux (81% and 48% in VUR grades I-II and III-V, respectively) (18,19). The objective of conservative therapy is prevention of febrile UTI.

Education and consistent follow-up of the patient and parent, high fluid intake, regular and complete emptying of the bladder (if necessary with double micturition) and low-dose antibiotic prophylaxis are key aspects of conservative management. In boys with low-grade VUR, circumcision may be advised.

Conservative management should be dismissed in favour of surgical intervention in all cases of febrile breakthrough infections, as well as in girls in whom VUR has persisted up to an age at which spontaneous resolution can no longer be expected. In boys 5 years and older antibiotic prophylaxis may be stopped, and indications for surgical reflux correction are rare.

14.4.2 Interventional therapy

14.4.2.1 Open surgery

Various intra- and extra-vesical techniques have been described for the surgical correction of reflux. Although different methods have specific advantages and complications, they all share the basic principle of lengthening the intramural part of the ureter by submucosal embedding of the ureter. All techniques have been shown to be safe with a low rate of complications and excellent success rates (92-98%). Currently, the most popular procedures are the Lich-Gregoir, Politano-Leadbetter, Cohen and Psoas-Hitch ureteroneocystostomy (20, 21).

Surgery in early infancy carries a high risk of severely damaging bladder function. If an extravesical procedure is planned, cystoscopy should be performed preoperatively to assess the bladder mucosa and position and configuration of the ureteric orifices. In bilateral reflux, intravesical antireflux procedures may be considered, as simultaneous bilateral extravesical reflux repair carries an increased risk of temporary post-operative urine retention (22).

14.4.2.2 Laparoscopic reflux correction

In a small number of children, VUR has been corrected laparoscopically. Although success rates are similar to open surgery, laparoscopic reflux correction takes significantly longer and therefore has no obvious advantages (23). At present, a laparoscopic approach cannot be recommended as a routine procedure (24).

14.4.2.3 Endoscopic therapy

Although still mainly experimental, endoscopic treatment of VUR offers the advantage of enabling treatment

of the underlying anatomical defect while avoiding the morbidity of open surgery (25). With the availability of biodegradable substances, endoscopic subureteral injection of tissue-augmenting substances (bulking agents) have become an alternative to long-term antibiotic prophylaxis and surgical intervention in the treatment of VUR in children (26). Although there is not yet a prospective trial proving that endoscopic therapy is equally effective as the conservative management, endoscopic therapy is currently being used as the initial treatment of reflux in some centres. A sound clinical validation of its effectiveness is currently hampered by the lack of methodologically appropriate studies. In a recent meta-analysis (27), including 5,527 patients and 8,101 renal units, the reflux resolution rate (by ureter) following one treatment for grades I and II reflux was 78.5%, grade III 72%, grade IV 63% and grade V 51%. If the first injection was unsuccessful, the second treatment had a success rate of 68%, and the third treatment 34%. The aggregate success rate with one or more injections was 85%. The success rate was significantly lower for duplicated (50%) versus single systems (73%), and neuropathic (62%) versus normal bladders (74%).

14.5 Follow-up

Follow-up after surgical correction of VUR is a controversial issue. In a recent update of the International Reflux Study, the authors published the results of urography at 10 years after either medical or surgical treatment of VUR. They concluded that with careful management, only a small proportion of children with severe reflux developed new scars and then rarely after the first 5-year follow-up period, and that there was no difference between children treated medically or surgically (28). Routine radionuclide studies are therefore not recommended.

As post-operative VCUG does not allow identification of children at risk of developing febrile UTI, this investigation is optional. Although VCUG may not be necessary in clinically asymptomatic cases after open surgery (29), it is mandatory following endoscopic treatment.

Obstruction of the upper urinary tract is ruled out by sonography at discharge and 3 months post-operatively. The follow-up protocol should include blood pressure measurement and urinalysis.

14.6 REFERENCES

1. Fanos V, Cataldi L. Antibiotics or surgery for vesicoureteric reflux in children. *Lancet* 2004;364(9446):1720-2.
<http://www.ncbi.nlm.nih.gov/pubmed/15530633>
2. Murawski IJ, Gupta IR. Vesicoureteric reflux and renal malformations: a developmental problem. *Clin Genet* 2006;69(2):105-17.
<http://www.ncbi.nlm.nih.gov/pubmed/16433689>
3. Anderson NG, Wright S, Abbott GD, Wells JE, Mogridge N. Fetal renal pelvic dilatation - poor predictor of familial vesicoureteric reflux. *Pediatr Nephrol* 2003;18(9):902-5.
<http://www.ncbi.nlm.nih.gov/pubmed/12883970>
4. Phan V, Traubici J, Hershenfield B, Stephens D, Rosenblum ND, Geary DF. Vesicoureteral reflux in infants with isolated antenatal hydronephrosis. *Pediatr Nephrol* 2003;18(12):1224-8.
<http://www.ncbi.nlm.nih.gov/pubmed/14586679>
5. Blumenthal I. Vesicoureteric reflux and urinary tract infection in children. *Postgrad Med J* 2006;82(963):31-5.
<http://www.ncbi.nlm.nih.gov/pubmed/16397077>
6. Ardissino G, Avolio L, Dacco V, Testa S, Marra G, Viganò S, Loi S, Caione P, De Castro R, De Pascale S, Marras E, Riccipetroni G, Selvaggio G, Pedotti P, Claris-Appiani A, Ciofani A, Dello Strologo L, Lama G, Montini G, Verrina E; ItalKid Project. Long-term outcome of vesicoureteral reflux associated chronic renal failure in children. Data from the ItalKid Project. *J Urol* 2004;172(1):305-10.
<http://www.ncbi.nlm.nih.gov/pubmed/15201801>
7. Vallee JP, Vallee MP, Greenfield SP, Wan J, Springate J. Contemporary incidence of morbidity related to vesicoureteral reflux. *Urology* 1999;53(4):812-5.
<http://www.ncbi.nlm.nih.gov/pubmed/10197863>
8. Hollowell JG, Greenfield SP. Screening siblings for vesicoureteral reflux. *J Urol* 2002;168(5):2138-41.
<http://www.ncbi.nlm.nih.gov/pubmed/12394743>
9. Giel DW, Noe HN, Williams MA. Ultrasound screening of asymptomatic siblings of children with vesicoureteral reflux: a long-term followup study. *J Urol* 2005;174(4 Pt 2):1602-4.
<http://www.ncbi.nlm.nih.gov/pubmed/16148662>
10. Elder JS, Peters CA, Arant BS Jr, Ewalt DH, Hawtrey CE, Hurwitz RS, Parrott TS, Snyder HM 3rd, Weiss RA, Woolf SH, Hasselblad V. Pediatric Vesicoureteral Reflux Guidelines Panel summary report on the management of primary vesicoureteral reflux in children. *J Urol* 1997;157(5):1846-51.
<http://www.ncbi.nlm.nih.gov/pubmed/9112544>

11. Smellie JM, Barratt TM, Chantler C, Gordon I, Prescod NP, Ransley PG, Woolf AS. Medical versus surgical treatment in children with severe bilateral vesicoureteric reflux and bilateral nephropathy: a randomised trial. *Lancet* 2001;357(9265):1329-33.
<http://www.ncbi.nlm.nih.gov/pubmed/11343739>
12. Wheeler DM, Vimalachandra D, Hodson EM, Roy LP, Smith GH, Craig JC. Interventions for primary vesicoureteric reflux. *Cochrane Database Syst Rev* 2004; (3):CD001532.
<http://www.ncbi.nlm.nih.gov/pubmed/15266449>
13. Lebowitz RL, Olbing H, Parkkulainen KV, Smellie JM, Tamminen-Mobius TE. International Reflux Study in Children: international system of radiographic grading of vesicoureteric reflux. *Pediatr Radiol* 1985;15(2):105-9.
<http://www.ncbi.nlm.nih.gov/pubmed/3975102>
14. Darge K, Riedmiller H. Current status of vesicoureteral reflux diagnosis. *World J Urol* 2004;22:88-95.
<http://www.ncbi.nlm.nih.gov/pubmed/15173954>
15. Camacho V, Estorch M, Fraga G, Mena E, Fuertes J, Hernandez MA, Flotats A, Carrio I. DMSA study performed during febrile urinary tract infection: a predictor of patient outcome? *Eur J Nucl Med Mol Imaging* 2004;31(6):862-6.
<http://www.ncbi.nlm.nih.gov/pubmed/14758509>
16. Koff SA, Wagner TT, Jayanthi VR. The relationship among dysfunctional elimination syndromes, primary vesicoureteral reflux and urinary tract infections in children. *J Urol* 1998;160(3 Pt 2):1019-22.
<http://www.ncbi.nlm.nih.gov/pubmed/9719268>
17. Elder JS. Guidelines for consideration for surgical repair of vesicoureteric reflux. *Curr Opin Urol* 2000;10(6):579-85.
<http://www.ncbi.nlm.nih.gov/pubmed/11148729>
18. Arant BS Jr. Medical management of mild and moderate vesicoureteral reflux: followup studies of infants and young children. A preliminary report of the Southwest Pediatric Nephrology Study Group. *J Urol* 1992;148(5 Pt 2):1683-7.
<http://www.ncbi.nlm.nih.gov/pubmed/1433588>
19. Smellie JM, Jodal U, Lax H, Mobius TT, Hirche H, Olbing H; Writing Committee, International Reflux Study in Children (European Branch). Outcome at 10 years of severe vesicoureteric reflux managed medically: report of the International Reflux Study in Children. *J Pediatr* 2001;139:656-63.
<http://www.ncbi.nlm.nih.gov/pubmed/11713442>
20. Austin JC, Cooper CS. Vesicoureteral reflux: surgical approaches. *Urol Clin North Am* 2004;31(3): 543-57.
<http://www.ncbi.nlm.nih.gov/pubmed/15313064>
21. Heidenreich A, Ozgur E, Becker T, Haupt G. Surgical management of vesicoureteral reflux in pediatric patients. *World J Urol* 2004;22(2):96-106.
<http://www.ncbi.nlm.nih.gov/pubmed/15221260>
22. Lipski BA, Mitchell ME, Burns MW. Voiding dysfunction after bilateral extravesical ureteral reimplantation. *J Urol* 1998;159(3):1019-21.
<http://www.ncbi.nlm.nih.gov/pubmed/9474222>
23. Janetschek G, Radmayr C, Bartsch G. Laparoscopic ureteral anti-reflux plasty reimplantation. First clinical experience. *Ann Urol (Paris)* 1995;29:101-5.
<http://www.ncbi.nlm.nih.gov/pubmed/7645993>
24. El-Ghoneimi A. Paediatric laparoscopic surgery. *Curr Opin Urol* 2003;13(4):329-35.
<http://www.ncbi.nlm.nih.gov/pubmed/12811298>
25. Chertin B, Puri P. Endoscopic management of vesicoureteral reflux: does it stand the test of time? *Eur Urol* 2002;42(6):598-606.
<http://www.ncbi.nlm.nih.gov/pubmed/12477657>
26. Lightner DJ. Review of the available urethral bulking agents. *Curr Opin Urol* 2002;12:333-8.
<http://www.ncbi.nlm.nih.gov/pubmed/12072655>
27. Elder JS, Diaz M, Caldamone AA, Cendron M, Greenfield S, Hurwitz R, Kirsch A, Koyle MA, Pope J, Shapiro E. Endoscopic therapy for vesicoureteral reflux: a meta-analysis. I. Reflux resolution and urinary tract infection. *J Urol* 2006;175(2):716-22.
<http://www.ncbi.nlm.nih.gov/pubmed/16407037>
28. Olbing H, Smellie JM, Jodal U, Lax H. New renal scars in children with severe VUR: a 10-year study of randomized treatment. *Pediatr Nephrol* 2003(11);18:1128-31.
<http://www.ncbi.nlm.nih.gov/pubmed/14523634>

29. Barrieras D, Lapointe S, Reddy PP, Williot P, McLorie GA, Bigli D, Khoury AE, Merguerian PA. Are postoperative studies justified after extravesical ureteral reimplantation? *J Urol* 2000;164(3 Pt 2): 1064-6.
<http://www.ncbi.nlm.nih.gov/pubmed/10958758>

15. URINARY STONE DISEASE

15.1 Background

Paediatric stone disease is an important clinical problem in paediatric urology practice. Because of its recurrent nature, every effort should be made to discover the underlying metabolic abnormality so that it can be treated appropriately. Obtaining a stone-free state with interventional management and close follow-up are of utmost importance.

Paediatric stone disease has its own unique features, which are different in both presentation and treatment compared to stone disease in adults. In contrast to adults with stone disease who are more likely to be male, boys and girls are affected almost equally. Most paediatric stones are located in the upper urinary tract. However, bladder stones are still common in underdeveloped areas of the world and are usually ammonium acid urate and uric acid stones, strongly implicating dietary factors (1).

The incidence and characteristics of stones show a wide geographical variation in children. Although urinary stone disease is generally considered to be a relatively rare disease, it is quite common in some parts of the world. Paediatric stone disease is endemic in Turkey, Pakistan and in some South Asian, African and South American states. In the UK and other European countries, 75% of calculi in children are composed of organic matrix and struvite, with many coinciding with *Proteus* infection and urinary tract anomalies (2).

15.2 Stone formation mechanisms, diagnosis of causative factors and medical treatment for specific stone types

Urinary stone formation is the result of a complex process involving metabolic, anatomical factors and presence of infection.

When supersaturated in urine calcium, oxalate, uric acid and cystine molecules may cause stone formation. A decreased concentration of crystallization inhibitors (citrate, magnesium, pyrophosphate, macromolecules and glycosaminoglycans) may sometimes be the sole factor playing a role in the formation of urinary stones. Urinary pH changes also affect stone formation.

An impaired flow of urine due to abnormal morphology may facilitate stasis and increase the concentration of stone-forming substances.

15.2.1 Calcium stones

Calcium stones are usually made from calcium oxalate or calcium phosphate. Either supersaturation of calcium (hypercalciuria) and oxalate (hyperoxaluria) or decreased concentration of inhibitors like citrate (hypocitraturia) play a major role in calcium oxalate stone formation.

Hypercalciuria. This is defined by a 24-hour urinary calcium excretion of more than 4 mg/kg/day in a child weighing less than 60 kg. In infants younger than 3 months, 5 mg/kg/day is considered to be the upper limit of normal for calcium excretion (3).

Hypercalciuria can be classified as either idiopathic or secondary. Idiopathic hypercalciuria is diagnosed when clinical, laboratory, and radiographic investigations fail to delineate an underlying cause. Secondary hypercalciuria occurs when a known process produces excessive urinary calcium. In secondary (hypercalcaemic) hypercalciuria, a high serum calcium level may be due to increased bone resorption (hyperparathyroidism, hyperthyroidism, immobilization, acidosis, metastatic disease) or gastrointestinal hyperabsorption (hypervitaminosis D) (4).

A good screening test for hypercalciuria compares the ratio of urinary calcium to creatinine. The normal calcium-to-creatinine ratio in children is less than 0.2. If the calculated ratio is higher than 0.2, repeat testing is indicated. Neonates and infants have a higher calcium excretion and lower creatinine excretion than older children (3,4). If the follow-up ratios are normal, then no additional testing for hypercalciuria is needed. However, if the ratio remains elevated, a timed 24-hour urine collection should be obtained and the calcium excretion calculated.

The 24-hour calcium excretion test is the criterion standard for the diagnosis of hypercalciuria. If calcium excretion is higher than 4 mg/kg/day (0.1 mmol/kg/day), the diagnosis of hypercalciuria is confirmed and further evaluation is warranted. Further evaluation includes levels of serum bicarbonate, creatinine, alkaline

phosphatase, calcium, magnesium, pH, and parathyroid hormone. Freshly voided urine should be measured for pH (3-6).

A 24-hour urine collection should also be collected for measurement of calcium, phosphorus, sodium, magnesium, citrate and oxalate. Meanwhile dietary manipulations should be tried to normalize urine calcium (6).

Initial management is always to increase fluid intake and urinary flow. Dietary modification is a mandatory part of effective therapy. The child should be referred to a dietician to assess accurately the daily intake of calcium, animal protein, and sodium. Dietary sodium restriction is recommended as well as maintenance of calcium intake consistent with the daily needs of the child (7).

A brief trial of a low-calcium diet can be carried out to determine if exogenous calcium intake is contributing to a high urinary calcium. However, great caution should be used when trying to restrict calcium intake for long periods (Level of evidence: 3; Grade of recommendation: B).

Hydrochlorothiazide and other thiazide-type diuretics may be used to treat hypercalciuria at a dosage of 1-2 mg/kg/day (2, 8) (Level of evidence: 3; Grade of recommendation: C). Citrate therapy is also useful if citrate levels are low or if hypercalciuria persists, despite other therapies (2, 9) (Level of evidence: 4; Grade of recommendation: C).

Hyperoxaluria. Oxalic acid is a metabolite excreted by the kidneys. Only 10-15% of oxalate comes from diet. Normal school children excrete less than 50 mg (0.57 mmol)/1.73m²/day (2, 10), while infants excrete four times as much. Hyperoxaluria may result from increased dietary intake, enteric hyperabsorption (as in short bowel syndrome) or an inborn error of metabolism.

In primary hyperoxaluria, one of the two liver enzymes that play a role in the metabolism of oxalate may be deficient. In primary hyperoxaluria there is increased deposition of calcium oxalate in the kidney and in urine. With increased deposition of calcium oxalate in the kidneys, renal failure may ensue in resulting deposition of calcium oxalate in other tissues. The diagnosis is made upon laboratory findings of severe hyperoxaluria and clinical symptoms. The definitive diagnosis requires liver biopsy to assay the enzyme activity.

Other forms of hyperoxaluria, as mentioned earlier, may be due to hyperabsorption of oxalate in inflammatory bowel syndrome, pancreatitis and short bowel syndrome. Yet, the majority of children who have high levels of oxalate excretion in urine may not have any documented metabolic problem or any dietary cause. This is known as idiopathic 'mild' hyperoxaluria, with urine oxalate levels elevated only mildly in these cases. The treatment of hyperoxaluria consists of the promotion of high urine flow, restriction of dietary oxalate and regular calcium intake. Pyridoxine may be useful in reducing urine levels, especially in primary hyperoxaluria (2, 10) (Level of evidence: 4; Grade of recommendation: C).

Hypocitraturia. Citrate is a urinary stone inhibitor. Citrate acts by binding to calcium and by directly inhibiting the growth and aggregation of calcium oxalate as well as calcium phosphate crystals. Thus, low urine citrate may be a significant cause of calcium stone disease. In adults, hypocitraturia is the excretion of citrate in urine of less than 320 mg/day (1.5 mmol/day) for adults; this value must be adjusted for children depending on body size (11, 12).

Hypocitraturia usually occurs in the absence of any concurrent symptoms or any known metabolic derangements. It may also occur in association with any metabolic acidosis, distal tubular acidosis or diarrhoeal syndromes.

Environmental factors that lower urinary citrate include a high protein intake and excessive salt intake. Many reports emphasize the significance of hypocitraturia in paediatric calcium stone disease. The presence of hypocitraturia ranges from 30% to 60% in children with calcium stone disease.

Due to the increased stone risk in hypocitraturia, the restoration of normal citrate levels is advocated to reduce stone formation. Although some studies have shown that citrate replacement therapy reduces the risk of stone formation in an adult population, there are few relevant studies in children. Hypocitraturia is treated by potassium citrate at a starting dose of 1 mEq/kg, given in two divided doses (12) (Level of evidence: 3; Grade of recommendation: B).

15.2.2 Uric acid stones

Uric acid stones are responsible for urinary calculi in 4-8% of children. Uric acid is the end product of purine metabolism. Hyperuricosuria is the main cause of uric acid stone formation in children. A daily output of uric acid of more than 10 mg/kg/day is considered to be hyperuricosuria (2).

The formation of uric acid stones is dependent, mainly on the presence of acidic urinary composition.

Uric acid dissociation and solubility is strongly reduced at pH of less than 5.8. As the pH becomes more alkaline, uric acid crystals become more soluble and the risk of uric acid stone formation is reduced.

In the familial or idiopathic form of hyperuricosuria, children usually have normal serum uric acid levels. In other children, it can be caused by uric acid overproduction secondary to inborn errors of metabolism, myeloproliferative disorders or other causes of cell breakdown. Hyperuricosuria is also caused by high purine and protein intake. Although hyperuricosuria is a risk factor for calcium oxalate stone formation in adults, this does not appear to be a significant risk factor in children.

Uric acid stones are non-opaque stones. Plain X-rays are insufficient to show uric acid stones, and renal sonography and spiral CT are used for diagnosis.

Alkalinization of urine is the mainstay of therapy and prevention for uric acid stones. Citrate preparations are useful as alkalinizing agents. Maintaining a urine pH of 6 to 6.5 is sufficient to prevent uric acid stones (2).

15.2.3 Cystine stones

Cystinuria is the cause of cystine stone formation and accounts for 2-6% of all urinary stones in children. Cystinuria is an incompletely recessive autosomal disorder characterized by failure of renal tubules to reabsorb four basic amino acids, cystine, ornithine, lysine and arginine.

Of these four amino acids, only cystine has poor solubility in urine, so that only cystine stones may form in the case of excessive excretion in urine. Cystine solubility is pH-dependent, with cystine precipitation beginning at pH levels < 7.0. Other metabolic conditions, such as hypercalciuria, hypocitraturia and hyperuricosuria, may accompany cystinuria, so leading to the formation of mixed-composition stones.

Cystine stones are faintly radiolucent and may be difficult to show on regular radiograph studies. They are also hard in texture and more difficult to disintegrate by extracorporeal shock-wave lithotripsy (ESWL).

The medical treatment for cystine stones aims to reduce cystine saturation in urine and increase its solubility. The initial treatment consists of maintaining a high urine flow and the use of alkalinizing agents, such as potassium citrate to maintain urine pH at above 7.0. If this treatment fails, the use of α -mercaptopyronil glycine or D-penicillamine may reduce cystine levels in urine and prevent stone formation. Use of these drugs can be associated with severe side effects, such as bone marrow depression and nephrotic syndrome (13) (Level of evidence: 4; Grade of recommendation: C).

15.2.4 Infection stones (struvite stones)

Infection-related stones constitute nearly 5% of urinary stones in children. Bacteria capable of producing urease enzyme (*Proteus*, *Klebsiella*, *Pseudomonas*) are responsible for the formation of such stones.

Urease converts urea into ammonia and bicarbonate, so alkalinizing the urine and further converting bicarbonate into carbonate. In the alkaline environment, triple phosphates form, eventually resulting in a supersaturated environment of magnesium ammonium phosphate and carbonate apatite, which in turn leads to stone formation.

In addition to bacterial elimination, stone elimination is essential for treatment, as stones will harbour infection and antibiotic treatment will not be effective. Consideration should be given to investigating any congenital problem that causes stasis and infection. Genitourinary tract anomalies predispose to formation of such stones.

15.3 Clinical presentation

Presentation tends to be age-dependent, with symptoms such as flank pain and haematuria being more common in older children. Non-specific symptoms (e.g. irritability, vomiting) are common in very young children. Haematuria, usually gross, occurring with or without pain, is less common in children. However, microscopic haematuria may be the sole indicator and is more common in children. In some cases, urinary infection may be the only finding leading to radiological imaging in which a stone is identified (14,15).

15.4 Diagnosis

15.4.1 Imaging

Generally, ultrasonography should be used as a first study. Renal ultrasonography is very effective for identifying stones in the kidney. Many radiolucent stones can be identified with a simple abdominal flat-plate examination.

If no stone is found but symptoms persist, spiral CT scanning is indicated. The most sensitive test for identifying stones in the urinary system is non-contrast helical CT scanning. It is safe and rapid, with 97% sensitivity and 96% specificity (16-18) (Level of evidence: 2; Grade of recommendation: B).

Intravenous pyelography is rarely used in children, but may be needed to delineate the caliceal anatomy prior to percutaneous or open surgery.

15.4.2 Metabolic evaluation

Due to the high incidence of predisposing factors for urolithiasis in children and high stone recurrence rates, every child with urinary stone should be given a complete metabolic evaluation (1, 19, 20).

Metabolic evaluation includes:

- Family and patient history of metabolic problems.
- Analysis of stone composition (following stone analysis, metabolic evaluation can be modified according to the specific stone type).
- Electrolytes, BUN, creatinine, calcium, phosphorus, alkaline phosphatase, uric acid, total protein, carbonate, albumin, and parathyroid hormone (if there is hypercalcaemia).
- Spot urinalysis and culture, including ratio of calcium to creatinine.
- Urine tests, including a 24-hour urine collection for calcium, phosphorus, magnesium, oxalate, uric acid citrate, cystine, protein, and creatinine clearance.

Figure 3 provides an algorithm of how to perform metabolic investigations in urinary stone disease in children and to plan medical treatment accordingly.

15.5 Management

With the advance of technology stone management has changed from open surgical approach to endoscopic techniques that are less invasive. Deciding the form of treatment depends on the number, size, location, composition and anatomy of the urinary tract (19, 21, 22).

Currently, most paediatric stones can easily be managed by ESWL. Endoscopic treatment can be applied easily for ureteric and bladder stones. Percutaneous removal of stones is also possible for kidney stones in children. Only a small portion of children will need an open surgical approach.

15.5.1 Extracorporeal shock-wave lithotripsy (ESWL)

Many reports confirm that shock-wave lithotripsy (SWL) can be performed in children with no suspicion of long-term morbidity of the kidney (23-28).

The mean number of shock waves for each treatment is about 1800 and 2000 (up to 4000 if needed) and the mean power set varies between 14kV and 21 kV. The use of ultrasonography and digital fluoroscopy has significantly decreased the radiation exposure and it has been shown that children are exposed to significantly lower doses of radiation compared to adults (21, 29, 30). Concerns about anaesthesia do not seem to be a problem any more because of advances in technique and medication, even in the infant period. The type of anaesthesia should be general or dissociative for children under 10 years of age, whereas conventional intravenous sedation or patient-controlled analgesia is an option for older children who are able to co-operate (31) (Level of evidence: 2b).

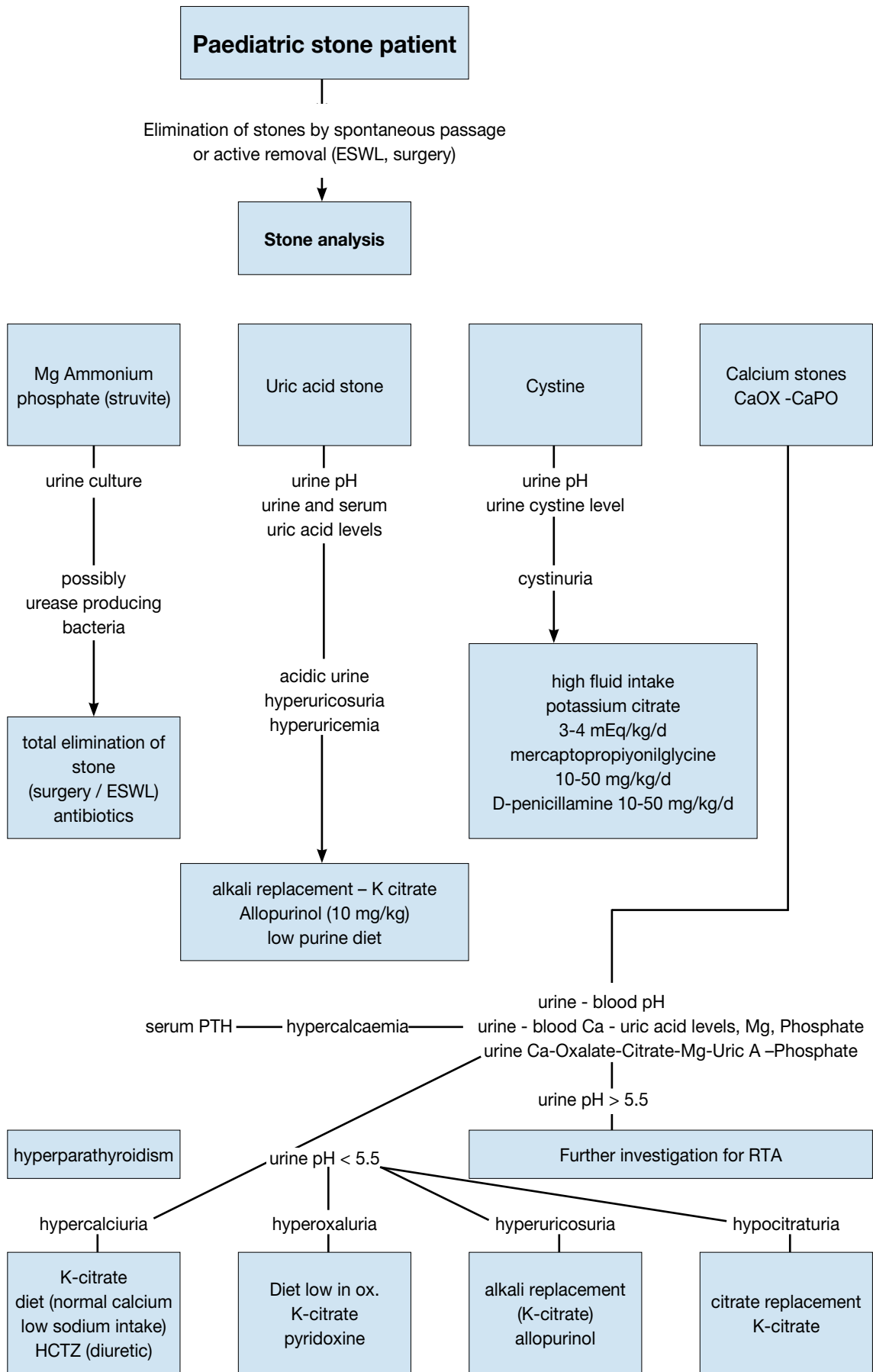
Stone-free rates are significantly affected by various factors. Regardless of the location, as the stone size increases, the stone-free rates decrease and re-treatment rate increases. The stone-free rates for < 1 cm, 1-2 cm, > 2 cm and overall were reported as nearly 90%, 80%, 60% and 80%, respectively. As the stone size increases, the need for additional sessions increases (21, 29, 30, 32-36).

Localization of the calculi has been described as a significant factor affecting the success rates in different studies. Stones in renal pelvis and upper ureter seem to respond better to SWL. In these mentioned sites, the stone clearance rates are nearly 90%. However, SWL was found to be less effective for caliceal stones particularly the lower caliceal stones. Several studies reported stone-free rates for isolated lower caliceal stones varying between 50% and 62% (37-40).

ESWL treatment can also be used to treat ureteral calculi. However, this is a more specific issue and with controversies. The success rates with ESWL are less for distal ureteric stones. There may also be technical problems with localization and focusing of ureteric stones in children (37, 39, 40-42).

The type of machine used has a strong effect on success rates and complications. First-generation machines can deliver more energy to a larger focal zone, resulting in higher fragmentation rates in a single therapy. However, general anaesthesia is usually required due to the intolerable discomfort associated with a first-generation machine. Later-generation machines have a smaller focal zone and deliver less energy, and have a lower risk of pulmonary trauma. However, additional treatments may be needed with later-generation machines. The success rate is higher in younger children (35).

Although stenting does not affect stone clearance, overall complication rates are higher and hospital stay is longer in the unstented patient (34, 35). Stenting is essential in solitary kidneys undergoing ESWL treatment. Children with a large stone burden have a high risk of developing Steinstrasse and urinary obstruction and should be followed more closely for the risk of prolonged urinary tract obstruction after ESWL. Post-ESWL stent or nephrostomy tube placement may be needed in prolonged obstruction (20, 36).



ESWL = extracorporeal shockwave lithotripsy; HCTZ = hydrochlorothiazide; PTH = parathyroid hormone; RTA = renal tubular acidosis

ESWL in children may have complications, but these are often self-limiting and transient. The most frequently observed complications are:

- Renal colic
- Transient hydronephrosis
- Dermal ecchymosis
- Urinary tract infection
- Formation of Steinstrasse
- Sepsis
- Rarely, haemoptysis.

In children with sterile pre-operative urine cultures, antibiotic prophylaxis to decrease the infectious complications is not recommended (43). However, every effort should be made to sterilize the urine before performing ESWL, ureteroscopy (URS), or percutaneous nephrolithotomy.

15.5.2 Percutaneous nephrolithotomy

ESWL is the first choice for treating most renal paediatric stones. However, percutaneous renal surgery can be used for larger and complex stones. Pre-operative evaluation, indication and surgical technique are similar in children compared to adults. PCNL is used as monotherapy in most cases, but is also used as an adjunctive procedure to other therapies.

The use of adult-sized instruments, in association with an increased number of tracts and sheath size, seems to increase the blood loss. However, small-calibre instruments have now been developed and there are some advantages for PCNL in children (particularly smaller children), such as smaller skin incision, single-step dilation and sheath placement, good working access for paediatric instruments, variable length, and lower cost (43, 44). Now that appropriate-size instruments are available, age is no longer a limiting factor for PCNL.

As monotherapy, PCNL is considerably effective and safe. The reported stone-free rates in the recent literature are between 86.9% and 98.5% after a single session. These rates increase with adjunctive measures, such as second-look PCNL, ESWL and URS. Even in complete staghorn cases, a clearance rate of 89% has been achieved following a single session (45-48, 50, 51).

The most frequently reported complications of PCNL in children are bleeding, post-operative fever or infection, and persistent urinary leakage. Bleeding requiring transfusion is reported in 0.4% to 23.9% and is closely associated with stone burden, operative time, sheath size and number of tracts. Post-operative fever and infection has been reported up to 29.3% and 5.5%, respectively; the origin of fever is not thought to be the infection (49-56).

The mean post-operative hospital stay is similar to adults. It is reported as 3 to 4 days in all the previously mentioned studies and is much shorter than open surgery. The less invasive nature of this technique has made it a promising alternative to open surgery for treating renal stones in children (Level of evidence: 2; Grade of recommendation: B).

15.5.3 Ureterorenoscopy

The increasing availability of smaller size endourological equipment has made it possible to manage paediatric ureteral stones using endoscopic techniques.

The technique used in children is similar to the one used in adults. It is strongly recommended that guide wires are used and the procedure is performed using direct vision. Routine balloon dilation of ureterovesical junction and ureteral stenting are controversial. In general, ureteric dilatation is being done less and less and only in selected cases. The general tendency is to use hydrodilatation more as it is shown to be as effective (57-60, 43, 61-63) (Level of evidence: 3; Grade of recommendation: B).

Different lithotripsy techniques, including ultrasonic, pneumatic and laser lithotripsy, have all been shown to be safe and effective. Because of the smaller size of the probes, laser energy is easier to use in smaller instruments and is more useful for paediatric cases (50, 58, 60, 64-70).

All studies reporting the use of endoscopy for ureteric stones in children have clearly demonstrated that there is no significant risk of ureteric strictures or reflux with this mode of therapy (Level of evidence: 1; grade of recommendation: A).

15.5.4 Open stone surgery

Most stones in children can be managed by ESWL and endoscopic techniques. Yet in some situations, open surgery is inevitable. Good candidates for open stone surgery include very young children with large stones and/or a congenitally obstructed system which also requires surgical correction. Severe orthopaedic deformities may limit positioning for endoscopic procedures. Open surgery would also be a necessity for such children.

Bladder stones in children can usually be managed by endoscopic techniques. Open surgery may also be used for very large bladder stones or for bladder stones caused by an anatomical problem.

Recommendations for interventional management are given in Table 3.

Table 3: Recommendations for interventional management in paediatric stones

Stone size and localization*	Primary treatment option	LE	Secondary treatment options	
Staghorn stones	PCNL	2b	Open/SWL	Multiple sessions and accesses with PCNL may be needed Combination with SWL may be useful
Pelvis < 10 mm	SWL	1a	RIRS/PCNL	
Pelvis 10-20 mm	SWL	2b	PCNL/Open	Multiple sessions with SWL may be needed PCNL has similar recommendation grade
Pelvis > 20 mm	PCNL	2b	SWL/Open	Multiple sessions with SWL may be needed
Lower pole calix < 10 mm	SWL	2c	RIRS/PCNL	Anatomical variations are important for complete clearance after SWL
Lower pole calix > 10 mm	PCNL	2b	SWL	Anatomical variations are important for complete clearance after SWL
Upper ureteric stones	SWL	2b	PCNL/URS/ Open	
Lower ureteric stones	URS	1a	SWL/Open	Additional intervention need is high with SWL
Bladder stones	Endoscopic	2b	Open	Open is easier and with less operative time with large stones

* Cystine and uric acid stones excluded.

LE = level of evidence; PCNL = percutaneous nephrolithostomy; SWL = shock-wave lithotripsy; RIRS = retrograde intrarenal surgery; URS = ureteroscopy.

15.6 REFERENCES

1. Straub M, Strohmaier WL, Berg W, Beck B, Hoppe B, Laube N, Lahme S, Schmidt M, Hesse A, Koehrmann KU. Diagnosis and metaphylaxis of stone disease. Consensus concept of the National Working Committee on Stone Disease for the Upcoming German Urolithiasis Guideline. *World J Urol* 2005;23(5):309-23.
<http://www.ncbi.nlm.nih.gov/pubmed/16315051>
2. Bartosh SM. Medical management of pediatric stone disease. *Urol Clin North Am* 2004;31(3):575-87, x-xi.
<http://www.ncbi.nlm.nih.gov/pubmed/15313066>
3. Kruse K, Kracht U, Kruse U. Reference values for urinary calcium excretion and screening for hypercalciuria in children and adolescents. *Eur J Pediatr* 1984;143(1):23-31.
<http://www.ncbi.nlm.nih.gov/pubmed/6510426>
4. Sargent JD, Stukel TA, Kresel J, Klein RZ. Normal values for random urinary calcium to creatinine ratios in infancy. *J Pediatr* 1993;123(3):393-7.
<http://www.ncbi.nlm.nih.gov/pubmed/8355114>
5. Stapleton FB, Noe HN, Roy S 3rd, Jerkins GR. Hypercalciuria in children with urolithiasis. *Am J Dis Child* 1982;136(8):675-8.
<http://www.ncbi.nlm.nih.gov/pubmed/7102617>
6. Stapleton FB, Noe HN, Roy S 3rd, Jerkins GR. Urinary excretion of calcium following an oral calcium loading test in healthy children. *Pediatrics* 1982;69(5):594-7.
<http://www.ncbi.nlm.nih.gov/pubmed/7079015>
7. Borghi L, Schianchi T, Meschi T, Guerra A, Allegri F, Maggiore U, Novarini A. Comparison of two diets for the prevention of recurrent stones in idiopathic hypercalciuria. *N Engl J Med* 2002;346(2):77-84.
<http://www.ncbi.nlm.nih.gov/pubmed/11784873>
8. Preminger GM, Pak CY. Eventual attenuation of hypocalciuric response to hydrochlorothiazide in absorptive hypercalciuria. *J Urol* 1987;137(6):1104-8.
<http://www.ncbi.nlm.nih.gov/pubmed/3586136>
9. Tekin A, Tekgul S, Atsu N, Bakkaloglu M, Kendi S. Oral potassium citrate treatment for idiopathic hypocitruria in children with calcium urolithiasis. *J Urol* 2002;168(6):2572-4.
<http://www.ncbi.nlm.nih.gov/pubmed/12441986>

10. Morgenstern BZ, Milliner DS, Murphy ME, Simmons PS, Moyer TP, Wilson DM, Smith LH. Urinary oxalate and glycolate excretion patterns in the first year of life: a longitudinal study. *J Pediatr* 1993;123(2):248-51.
<http://www.ncbi.nlm.nih.gov/pubmed/8345420>
11. Defoor W, Asplin J, Jackson E, Jackson C, Reddy P, Sheldon C, Minevich E. Results of a prospective trial to compare normal urine supersaturation in children and adults. *J Urol* 2005;174(4 Pt 2):1708-10.
<http://www.ncbi.nlm.nih.gov/pubmed/16148687>
12. Tekin A, Tekgul S, Atsu N, Sahin A, Ozen H, Bakkaloglu M. A study of the etiology of idiopathic calcium urolithiasis in children: hypocitruria is the most important risk factor. *J Urol* 2000;164(1):162-5.
<http://www.ncbi.nlm.nih.gov/pubmed/10840454>
13. Tekin A, Tekgul S, Atsu N, Sahin A, Bakkaloglu M. Cystine calculi in children: the results of a metabolic evaluation and response to medical therapy. *J Urol* 2001;165(6 Pt 2):2328-30.
<http://www.ncbi.nlm.nih.gov/pubmed/11371943>
14. Bove P, Kaplan D, Dalrymple N, Rosenfield AT, Verga M, Anderson K, Smith RC. Reexamining the value of hematuria testing in patients with acute flank pain. *J Urol* 1999;162(3 Pt 1):685-7.
<http://www.ncbi.nlm.nih.gov/pubmed/10458342>
15. Sternberg K, Greenfield SP, Williot P, Wan J. Pediatric stone disease: an evolving experience. *J Urol* 2005;174(4 Pt 2):1711-4.
<http://www.ncbi.nlm.nih.gov/pubmed/16148688>
16. Oner S, Oto A, Tekgul S, Koroglu M, Hascicek M, Sahin A, Akhan O. Comparison of spiral CT and US in the evaluation of paediatric urolithiasis. *JBR-BTR* 2004;87(5):219-23.
<http://www.ncbi.nlm.nih.gov/pubmed/15587558>
17. Memarsadeghi M, Heinz-Peer G, Helbich TH, Schaefer-Prokop C, Kramer G, Scharitzer M, Prokop M. Unenhanced multi-detector row CT in patients suspected of having urinary stone disease: effect of section width on diagnosis. *Radiology* 2005;235(2):530-6.
<http://www.ncbi.nlm.nih.gov/pubmed/15758192>
18. Strouse PJ, Bates DG, Bloom DA, Goodsitt MM. Non-contrast thin-section helical CT of urinary tract calculi in children. *Pediatr Radiol* 2002;32(5):326-32.
<http://www.ncbi.nlm.nih.gov/pubmed/11956719>
19. Tiselius HG, Ackermann D, Alken P, Buck C, Conort P, Gallucci M; Working Party on Lithiasis, European Association of Urology. Guidelines on urolithiasis. *Eur Urol* 2001;40(4):362-71.
<http://www.ncbi.nlm.nih.gov/pubmed/11713390>
20. Tekin A, Tekgul S, Atsu N, Ergen A, Kendi S. Ureteropelvic junction obstruction and coexisting renal calculi in children: role of metabolic abnormalities. *Urology* 2001;5(3)7:542-5.
<http://www.ncbi.nlm.nih.gov/pubmed/11248635>
21. Raza A, Turna B, Smith G, Moussa S, Tolley DA. Paediatric urolithiasis: 15 years of local experience with minimally invasive endourological management of paediatric calculi. *J Urol* 2005;174(2):682-5.
<http://www.ncbi.nlm.nih.gov/pubmed/16006948>
22. Rizvi SA, Naqvi SA, Hussain Z, Hashmi A, Hussain M, Zafar MN, Sultan S, Mehdi H. Paediatric urolithiasis: developing nation perspectives. *J Urol* 2002;168(4 Pt 1):1522-5.
<http://www.ncbi.nlm.nih.gov/pubmed/12352448>
23. Willis LR, Evan AP, Connors BA, Blomgren P, Fineberg NS, Lingeman JE. Relationship between kidney size, renal injury, and renal impairment induced by shock wave lithotripsy. *J Am Soc Nephrol* 1999;10(8):1753-62.
<http://www.ncbi.nlm.nih.gov/pubmed/10446943>
24. Villanyi KK, Szekely JG, Farkas LM, Javor E, Pusztai C. Short-term changes in renal function after extracorporeal shock wave lithotripsy in children. *J Urol* 2001;166(1):222-4.
<http://www.ncbi.nlm.nih.gov/pubmed/11435873>
25. Aldridge RD, Aldridge RC, Aldridge LM. Anesthesia for pediatric lithotripsy. *Paediatr Anaesth* 2006;16(3):236-41.
<http://www.ncbi.nlm.nih.gov/pubmed/16490086>
26. McLorie GA, Pugach J, Pode D, Denstedt J, Bagli D, Meretyk S, D'A Honey RJ, Merguerian PA, Shapiro A, Khoury AE, Landau EH. Safety and efficacy of extracorporeal shock wave lithotripsy in infants. *Can J Urol* 2003;10(6):2051-5.
<http://www.ncbi.nlm.nih.gov/pubmed/14704109>
27. Aksoy Y, Ozbey I, Atmaca AF, Polat O. Extracorporeal shock wave lithotripsy in children: experience using a mpl-9000 lithotripter. *World J Urol* 2004;22(2):115-9.
<http://www.ncbi.nlm.nih.gov/pubmed/14740160>

28. Vljakovic M, Slavkovic A, Radovanovic M, Siric Z, Stefanovic V, Perovic S. Long-term functional outcome of kidneys in children with urolithiasis after ESWL treatment. *Eur J Pediatr Surg* 2002;12(2):118-23.
<http://www.ncbi.nlm.nih.gov/pubmed/12015657>
29. Muslumanoglu AY, Tefekli A, Sarilar O, Binbay M, Altunrende F, Ozkuvanci U. Extracorporeal shock wave lithotripsy as first line treatment alternative for urinary tract stones in children: a large scale retrospective analysis. *J Urol* 2003;170(6 Pt 1):2405-8.
<http://www.ncbi.nlm.nih.gov/pubmed/14634438>
30. Ather MH, Noor MA. Does size and site matter for renal stones up to 30-mm in size in children treated by extracorporeal lithotripsy? *Urology* 2003;61(1):212-5; discussion 215.
<http://www.ncbi.nlm.nih.gov/pubmed/12559298>
31. Ugur G, Erhan E, Kocabas S, Ozyar B. Anaesthetic/analgesic management of extracorporeal shock wave lithotripsy in paediatric patients. *Paediatr Anaesth* 2003;13(1):85-7.
<http://www.ncbi.nlm.nih.gov/pubmed/12535048>
32. Rodrigues Netto N Jr, Longo JA, Ikonomidis JA, Rodrigues Netto M. Extracorporeal shock wave lithotripsy in children. *J Urol* 2002;167(5):2164-6.
<http://www.ncbi.nlm.nih.gov/pubmed/11956471>
33. Afshar K, McLorie G, Papanikolaou F, Malek R, Harvey E, Pippi-Salle JL, Bagli DJ, Khoury AE, Farhat W. Outcome of small residual stone fragments following shock wave lithotripsy in children. *J Urol* 2004;172(4 Pt 2):1600-3.
<http://www.ncbi.nlm.nih.gov/pubmed/15371769>
34. Tan AH, Al-Omar M, Watterson JD, Nott L, Denstedt JD, Razvi H. Results of shockwave lithotripsy for pediatric urolithiasis. *J Endourol* 2004;18(6):527-30.
<http://www.ncbi.nlm.nih.gov/pubmed/15333214>
35. Lottmann HB, Traxer O, Archambaud F, Mercier-Pageyral B. Monotherapy extracorporeal shock wave lithotripsy for the treatment of staghorn calculi in children. *J Urol* 2001;165(6 Pt 2):2324-7.
<http://www.ncbi.nlm.nih.gov/pubmed/11371942>
36. Al-Busaidy SS, Prem AR, Medhat M. Pediatric staghorn calculi: the role of extracorporeal shock wave lithotripsy monotherapy with special reference to ureteral stenting. *J Urol* 2003;169(2):629-33.
<http://www.ncbi.nlm.nih.gov/pubmed/12544330>
37. Ozgur Tan M, Karaoglan U, Sozen S, Bozkirli I. Extracorporeal shock-wave lithotripsy for treatment of ureteral calculi in paediatric patients. *Pediatr Surg Int* 2003;19(6):471-4.
<http://www.ncbi.nlm.nih.gov/pubmed/12736749>
38. Demirkesen O, Onal B, Tansu N, Altinta , s R, Yalçin V, Oner A. Efficacy of extracorporeal shock wave lithotripsy for isolated lower caliceal stones in children compared with stones in other renal locations. *Urology* 2006;67(1):170-174; discussion 174-5.
<http://www.ncbi.nlm.nih.gov/pubmed/16413356>
39. Ozgur Tan M, Karaoglan U, Sen I, Deniz N, Bozkirli I. The impact of radiological anatomy in clearance of lower calyceal stones after shock wave lithotripsy in paediatric patients. *Eur Urol* 2003;43(2):188-93.
<http://www.ncbi.nlm.nih.gov/pubmed/12565778>
40. Onal B, Demirkesen O, Tansu N, Kalkan M, Altinta R, Yalçin V. The impact of caliceal pelvic anatomy on stone clearance after shock wave lithotripsy for pediatric lower pole stones. *J Urol* 2004;172(3):1082-6.
<http://www.ncbi.nlm.nih.gov/pubmed/15311043>
41. Landau EH, Gofrit ON, Shapiro A, Meretyk S, Katz G, Shenfeld OZ, Golijanin D, Pode D. Extracorporeal shock wave lithotripsy is highly effective for ureteral calculi in children. *J Urol* 2001;165(6 Pt 2):2316-9.
<http://www.ncbi.nlm.nih.gov/pubmed/11371970>
42. Hochreiter WW, Danuser H, Perrig M, Studer UE. Extracorporeal shock wave lithotripsy for distal ureteral calculi: what a powerful machine can achieve. *J Urol* 2003;169(3):878-80.
<http://www.ncbi.nlm.nih.gov/pubmed/12576804>
43. Wu HY, Docimo SG. Surgical management of children with urolithiasis. *Urol Clin North Am* 2004;31(3):589-94.
<http://www.ncbi.nlm.nih.gov/pubmed/15313067>
44. Jackman SV, Hedican SP, Peters CA, Docimo SG. Percutaneous nephrolithotomy in infants and preschool age children: experience with a new technique. *Urology* 1998;52(4):697-701.
<http://www.ncbi.nlm.nih.gov/pubmed/9763096>
45. Sahin A, Tekgul S, Erdem E, Ekici S, Hascicek M, Kendi S. Percutaneous nephrolithotomy in older children. *J Pediatr Surg* 2000;35(9):1336-8.
<http://www.ncbi.nlm.nih.gov/pubmed/10999692>

46. Shokeir AA, El-Nahas AR, Shoma AM, Eraky I, El-Kenawy M, Mokhtar A, El-Kappany H. Percutaneous nephrolithotomy in treatment of large stones within horseshoe kidneys. *Urology* 2004;64(3):426-9.
<http://www.ncbi.nlm.nih.gov/pubmed/15351557>
47. Boormans JL, Scheepe JR, Verkoelen CF, Verhagen PC. Percutaneous nephrolithotomy for treating renal calculi in children. *BJU Int* 2005;95(4):631-4.
<http://www.ncbi.nlm.nih.gov/pubmed/15705093>
48. Dawaba MS, Shokeir AA, Hafez AT, Shoma AM, El-Sherbiny MT, Mokhtar A, Eraky I, El-Kenawy M, El-Kappany HA. Percutaneous nephrolithotomy in children: early and late anatomical and functional results. *J Urol* 2004;172(3):1078-81.
<http://www.ncbi.nlm.nih.gov/pubmed/15311042>
49. Zeren S, Satar N, Bayazit Y, Bayazit AK, Payasli K, Ozkeceli R. Percutaneous nephrolithotomy in the management of pediatric renal calculi. *J Endourol* 2002;16(2):75-8.
<http://www.ncbi.nlm.nih.gov/pubmed/11962558>
50. Desai MR, Kukreja RA, Patel SH, Bapat SD. Percutaneous nephrolithotomy for complex paediatric renal calculus disease. *J Endourol* 2004;18(1):23-7.
<http://www.ncbi.nlm.nih.gov/pubmed/15006048>
51. Badawy H, Salama A, Eissa M, Kotb E, Moro H, Shoukri I. Percutaneous management of renal calculi: experience with percutaneous nephrolithotomy in 60 children. *J Urol* 1999;162(5):1710-3.
<http://www.ncbi.nlm.nih.gov/pubmed/10524919>
52. Holman E, Khan AM, Flasko T, Toth C, Salah MA. Endoscopic management of pediatric urolithiasis in a developing country. *Urology* 2004;63(1):159-62; discussion 162.
<http://www.ncbi.nlm.nih.gov/pubmed/14751372>
53. Aron M, Yadav R, Goel R, Hemal AK, Gupta NP. Percutaneous nephrolithotomy for complete staghorn calculi in preschool children. *J Endourol* 2005;19(8):968-72.
<http://www.ncbi.nlm.nih.gov/pubmed/16253060>
54. Salah MA, Tallai B, Holman E, Khan MA, Toth G, Toth C. Simultaneous bilateral percutaneous nephrolithotomy in children. *BJU Int* 2005;95(1):137-9.
<http://www.ncbi.nlm.nih.gov/pubmed/15638911>
55. Samad L, Aquil S, Zaidi Z. Paediatric percutaneous nephrolithotomy: setting new frontiers. *BJU Int* 2006;97(2):359-63.
<http://www.ncbi.nlm.nih.gov/pubmed/15638911>
56. Salah MA, Toth C, Khan AM, Holman E. Percutaneous nephrolithotomy in children: experience with 138 cases in a developing country. *World J Urol* 2004;22(4):277-80.
<http://www.ncbi.nlm.nih.gov/pubmed/15448997>
57. Hill DE, Segura JW, Patterson DE, Kramer SA. Ureteroscopy in children. *J Urol* 1990;144(2 Pt 2):481-3; discussion 492-3.
<http://www.ncbi.nlm.nih.gov/pubmed/2374224>
58. Caione P, De Gennaro M, Capozza N, Zaccara A, Appetito C, Lais A, Gallucci M, di Silverio F. Endoscopic manipulation of ureteral calculi in children by rigid operative ureterorenoscopy. *J Urol* 1990;144(2 Pt 2):484-5; discussion 492-3.
<http://www.ncbi.nlm.nih.gov/pubmed/2374225>
59. Minevich E, Defoor W, Reddy P, Nishinaka K, Wacksman J, Sheldon C, Erhard M. Ureteroscopy is safe and effective in prepubertal children. *J Urol* 2005;174(1):276-9.
<http://www.ncbi.nlm.nih.gov/pubmed/15947666>
60. Soygur T, Zumrutbas AE, Gulpinar O, Suer E, Arikan N. Hydrodilation of the ureteral orifice in children renders ureteroscopic access possible without any further active dilation. *J Urol* 2006 ;176(1):285-7; discussion 287.
<http://www.ncbi.nlm.nih.gov/pubmed/16753421>
61. Al Busaidy SS, Prem AR, Medhat M. Paediatric ureteroscopy for ureteric calculi: a 4-year experience. *Br J Urol* 1997;80(5):797-801.
<http://www.ncbi.nlm.nih.gov/pubmed/9393306>
62. Schuster TG, Russell KY, Bloom DA, Koo HP, Faerber GJ. Ureteroscopy for the treatment of urolithiasis in children. *J Urol* 2002;167(4):1813-5; discussion 1815-6.
<http://www.ncbi.nlm.nih.gov/pubmed/11912438>
63. Richter S, Shalev M, Lobik L, Buchumensky V, Nissenkorn I. Early postoperative vesicoureteral refluxa temporary and infrequent complication: prospective study. *J Endourol* 1999;13(5):365-6.
<http://www.ncbi.nlm.nih.gov/pubmed/10446797>

64. Van Savage JG, Palanca LG, Andersen RD, Rao GS, Slaughenhaupt BL. Treatment of distal ureteral stones in children: similarities to the American Urological Association guidelines in adults. *J Urol* 2000;164 (3 Pt 2):1089-93.
<http://www.ncbi.nlm.nih.gov/pubmed/10958749>
65. Bassiri A, Ahmadnia H, Darabi MR, Yonessi M. Transureteral lithotripsy in pediatric practice. *J Endourol* 2002;16(4):257-60.
<http://www.ncbi.nlm.nih.gov/pubmed/12042111>
66. Raza A, Smith G, Moussa S, Tolley D. Ureteroscopy in the management of pediatric urinary tract calculi. *J Endourol* 2005 ;19(2):151-8.
<http://www.ncbi.nlm.nih.gov/pubmed/15798409>
67. Satar N, Zeren S, Bayazit Y, Aridogan IA, Soyupak B, Tansug Z. Rigid ureteroscopy for the treatment of ureteral calculi in children. *J Urol* 2004;172(1):298-300.
<http://www.ncbi.nlm.nih.gov/pubmed/15201799>
68. De Dominicis M, Matarazzo E, Capozza N, Collura G, Caione P. Retrograde ureteroscopy for distal ureteric stone removal in children. *BJU Int* 2005;95(7):1049-52.
<http://www.ncbi.nlm.nih.gov/pubmed/15839930>
69. Dogan HS, Tekgul S, Akdogan B, Keskin MS, Sahin A. Use of the holmium:YAG laser for ureterolithotripsy in children. *BJU Int* 2004;94(1):131-3.
<http://www.ncbi.nlm.nih.gov/pubmed/15217447>
70. Thomas JC, DeMarco RT, Donohoe JM, Adams MC, Brock JW 3rd, Pope JC 4th. Paediatric ureteroscopic stone management. *J Urol* 2005;174(3):1072-4.
<http://www.ncbi.nlm.nih.gov/pubmed/16094060>

16. OBSTRUCTIVE PATHOLOGY OF RENAL DUPLICATION: URETEROCELE AND ECTOPIC URETER

16.1 Background

Ureterocele and ectopic ureter are the two main anomalies associated with a complete renal duplication. At present, antenatal ultrasonography detects both conditions in the majority of cases and diagnosis is confirmed after birth by further examination. Later on in life, these anomalies are revealed by clinical symptoms: UTI, pain, disturbances of micturition and urinary incontinence.

16.1.1 Ureterocele

Ureterocele is a cystic dilatation developed on the intravesical part of the ureter corresponding to the upper pole of a renal duplication. It is more frequent in females than in males, the overall prevalence being 1 in 4,000 births.

16.1.2 Ectopic ureter

Ectopic ureter is less frequent than ureterocele (1 in 40,000 births), but is again more common in females (male to female ratio, 1:5). Eighty per cent of ectopic ureters are associated with a complete renal duplication.

In females, the ureteral orifice may be located:

- in the urethra, from bladder neck to meatus (35%)
- in the vaginal vestibule (30%)
- in the vagina (25%)
- in the uterus and Fallopian tube (rarely).

In males, the ureteral orifice may be located:

- in the posterior urethra above the verumontanum and never below the external sphincter (60%)
- in the seminal tract (vas deferens, ejaculatory ducts, seminal vesicles) (40%).

16.2 Classification

Ureteroceles are usually obstructive for the upper pole moiety, but the degree of obstruction and functional impairment is variable according to the type of ureterocele and upper pole dysplasia. In the orthotopic

form, there is often no, or only mild, obstruction and frequently the function of the moiety is normal or slightly impaired; the corresponding ureter may be dilated. In the ectopic form, the upper pole is altered, frequently dysplastic and hypofunctional or non-functional. The corresponding ureter is a megaureter. In the caecoureterocele (see definition below), the upper pole of the renal duplication is always dysplastic and non-functional.

16.2.1 Ectopic ureterocele

Ectopic ureterocele is the most common form of ureterocele (> 80%) and occurs bilaterally in about 40% of cases. It is voluminous, dissociating the trigone and slipping into the urethra, and can rarely prolapse through the urethral meatus. The ureterocele orifice is tight, rarely large, and located near the bladder neck, either in the bladder itself or in the urethra below the bladder neck. The ureter corresponding to the lower pole moiety is raised by the ureterocele and is frequently refluxing or compressed by the ureterocele, leading to an obstructive megaureter. A contralateral renal duplication is associated in 50% of cases. Occasionally, very large ureteroceles are responsible for reflux or obstruction of the contralateral upper tract.

16.2.2 Orthotopic ureterocele

Orthotopic ureterocele accounts for 15% of cases. It is exclusively observed in females, and is small and located strictly intravesically. Orthotopic ureteroceles are mostly combined with a single kidney system.

16.2.3 Caecoureterocele

Caecoureterocele is very rare, occurring in less than 5% of cases. It is associated with an ectopic ureter and located in the urethra below the bladder neck.

16.3 Diagnosis

16.3.1 Ureterocele

Prenatal ultrasound reveals easily voluminous obstructive ureteroceles. In cases of a very small upper pole or a slightly obstructive ureterocele, prenatal diagnosis will be difficult. If prenatal diagnosis has been impossible, the following clinical symptoms - beside incidental findings - can reveal the congenital anomaly at birth or later:

- at birth, a prolapsed and sometimes strangulated ureterocele may be observed in front of the urethral orifice. In a newborn boy, it might cause acute urinary retention, simulating urethral valves
- the early symptom of pyelonephritis in either sex may lead to the diagnosis
- later symptoms can include dysuria, recurrent cystitis and urgency.

In cases of prenatal diagnosis at birth, ultrasonography confirms the ureteral dilatation ending at the upper pole of a renal duplication. It also demonstrates the presence of an ureterocele in the bladder, with a dilated ureter behind the bladder.

At this point, it is important to assess the function of the upper pole using nuclear renography in the region of interest. Magnetic resonance urography may visualize the morphological status of the upper pole and lower moieties and of the contralateral kidney. A VCUG is mandatory in identifying an ipsilateral or contralateral reflux and to assess the degree of intraurethral prolapse of the ureterocele.

Urethrocystoscopy may reveal the pathology in cases where it is difficult to make the differential diagnosis between ureterocele and ectopic megaureter.

16.3.2 Ectopic ureter

Most of the ectopic megaureters are diagnosed primarily by ultrasound. In some cases, clinical symptoms can lead to diagnosis:

- in neonates: dribbling of urine, pyuria and acute pyelonephritis
- an ectopic orifice may be found in the meatal region. Significant vaginal discharge may be the equivalent of incontinence in little girls
- in pre-adolescent males: epididymitis is the usual clinical presentation and a palpable seminal vesicle may be found on digital rectal examination.

Ultrasonography, nuclear studies, VCUG, MR urography and cystoscopy are the diagnostic tools to assess function, to detect reflux and to rule out ipsilateral compression of the lower pole and urethral obstruction. In the clarification of incontinence in girls, a methylene blue filling of the bladder can be helpful: in the case of loss of uncoloured urine, an ectopic ureter must be present.

16.4 Treatment

16.4.1 Ureterocele

The management is controversial with the choice between endoscopic decompression, partial nephro-ureterectomy or complete primary reconstruction. The choice of a therapeutic modality depends on the

following criteria: clinical status of the patient (e.g. urosepsis), age of the patient, renal function of the upper pole, presence or absence of reflux, obstruction of the ipsilateral ureter, pathology of the contralateral ureter, and parents' and surgeon's preferences.

16.4.1.1 Early diagnosis

- in a clinically asymptomatic child with an ureterocele and non- or hypo-functional upper pole, without significant obstruction of the lower pole and without bladder outlet obstruction, prophylactic antibiotic treatment is given until follow-up procedures are instigated
- in the presence of severe obstruction and infection, an immediate endoscopic incision or puncture is recommended.

16.4.1.2 Re-evaluation

If decompression is effective and there is no reflux (approximately 25% of cases), the patient is followed-up conservatively. Secondary surgery is necessary if decompression is not effective, significant reflux is present or there is obstruction of the ipsi- or contra-lateral ureters and/or bladder neck obstruction. Surgery may vary from partial nephrectomy to complete unilateral reconstruction.

16.4.2 Ectopic ureter

In the majority of cases, the upper pole is dysplastic and heminephro-ureterectomy should be considered. Ureteral reconstruction is a therapeutic option in cases in which the upper pole has function worth preserving.

16.5 REFERENCES

Ureterocele

1. Austin PF, Cain MP, Casale AJ, Hiatt AK, Rink RC. Prenatal bladder outlet obstruction secondary to ureterocele. *Urology* 1998;52(6):1132-5.
<http://www.ncbi.nlm.nih.gov/pubmed/9836570>
2. Borer JG, Cisek LJ, Atala A, Diamond DA, Retik AB, Peters CA. Pediatric retroperitoneoscopic nephrectomy using 2 mm instrumentation. *J Urol* 1999;162(5):1725-9; discussion 1730.
<http://www.ncbi.nlm.nih.gov/pubmed/10524923>
3. Cain MP, Pope JC, Casale AJ, Adams MC, Keating MA, Rink RC. Natural history of refluxing distal ureteral stumps after nephrectomy and partial ureterectomy for vesicoureteral reflux. *J Urol* 1998;160(3 Pt 2):1026-7.
<http://www.ncbi.nlm.nih.gov/pubmed/9719270>
4. Cendron J, Melin Y, Valayer J. [Simplified treatment of ureterocele with pyeloureteric duplication. A propos of 35 cases.] *Chir Pediatr* 1980;21(2):121-4. [article in French]
<http://www.ncbi.nlm.nih.gov/pubmed/7448978>
5. Decter RM, Roth DR, Gonzales ET. Individualized treatment of ureteroceles. *J Urol* 1989;142 (2 Pt 2):535-7.
<http://www.ncbi.nlm.nih.gov/pubmed/2746775>
6. Di Benedetto V, Montfort G. How prenatal ultrasound can change the treatment of ectopic ureterocele in neonates? *Eur J Pediatr Surg* 1997;7(6):338-40.
<http://www.ncbi.nlm.nih.gov/pubmed/9493984>
7. el Ghoneimi A, Lottmann H, Odet E, Bonnain F, Aigrain Y. [Ureteropyelostomy for obstructed duplicated ureter an easy and reliable operation in infants.] *Ann Urol (Paris)* 1998;32(4):241-6. [article in French]
<http://www.ncbi.nlm.nih.gov/pubmed/9791553>
8. Husmann D, Strand B, Ewalt D, Clement M, Kramer S, Allen T. Management of ectopic ureterocele associated with renal duplication: a comparison of partial nephrectomy and endoscopic decompression. *J Urol* 1999;162(4):1406-9.
<http://www.ncbi.nlm.nih.gov/pubmed/10492225>
9. Janetschek G, Seibold J, Radmayr C, Bartsch G. Laparoscopic heminephroureterectomy in pediatric patients. *J Urol* 1997;158(5):1928-30.
<http://www.ncbi.nlm.nih.gov/pubmed/9334640>
10. Jayanthi VR, Koff SA. Long-term outcome of transurethral puncture of ectopic ureteroceles: initial success and late problems. *J Urol* 1999;162(3 Pt 2):1077-80.
<http://www.ncbi.nlm.nih.gov/pubmed/10458435>
11. Moscovici J, Galinier P, Berrogain N, Juricic M. [Management of ureteroceles with pyelo-ureteral duplication in children. Report of 64 cases.] *Ann Urol (Paris)* 1999;33(5):369-76. [article in French]
<http://www.ncbi.nlm.nih.gov/pubmed/10544742>

12. Monfort G, Guys JM, Coquet M, Roth K, Louis C, Bocciardi A. Surgical management of duplex ureteroceles. *J Ped Surg* 1992;27(5):634-8.
<http://www.ncbi.nlm.nih.gov/pubmed/1625138>
13. Pfister C, Ravasse P, Barret E, Petit T, Mitrofanoff P. The value of endoscopic treatment for ureteroceles during the neonatal period. *J Urol* 1998;159(3):1006-9.
<http://www.ncbi.nlm.nih.gov/pubmed/9474217>
14. Rickwood AMK, Reiner I, Jones M, Pournaras C. Current management of duplex system ureteroceles: experience with 41 patients. *Br J Urol* 1992;70(2):196-200.
<http://www.ncbi.nlm.nih.gov/pubmed/1393443>
15. Roy GT, Desai S, Cohen RC. Ureteroceles in children: an ongoing challenge. *Pediatr Surg Int* 1997; 12(1):448.
<http://www.ncbi.nlm.nih.gov/pubmed/9035209>
16. Sherz HC, Kaplan GW, Packer MG, Brock WA. Ectopic ureteroceles: surgical management with preservation of continence - review of 60 cases. *J Urol* 1989;142(2 Pt 3):538-41.
<http://www.ncbi.nlm.nih.gov/pubmed/2746776>
17. Stephens D. Caecoureterocele and concepts on the embryology and aetiology of ureteroceles. *Aust N Z J Surg* 1971;40(3):239-48.
<http://www.ncbi.nlm.nih.gov/pubmed/5279434>

Ectopic ureter

1. Carrico C, Lebowitz RL. Incontinence due to an infraspincteric ectopic ureter: why the delay in diagnosis and what the radiologist can do about it. *Pediatr Radiol* 1998;28(12):942-9.
<http://www.ncbi.nlm.nih.gov/pubmed/9880638>
2. Cendron J, Schulman CC. [Ectopic ureter.] In: *Paediatric urology*. Paris: Flammarion Médecine Sciences, 1985, pp. 147-53. [article in French]
3. el Ghoneimi A, Miranda J, Truong T, Montfort G. Ectopic ureter with complete ureteric duplication: conservative surgical management. *J Pediatr Surg* 1996;31(4):467-72.
<http://www.ncbi.nlm.nih.gov/pubmed/8801293>
4. Komatsu K, Niikura S, Maeda Y, Ishiura Y, Yokoyama O, Namiki M. Single ectopic vaginal ureter diagnosed by computed tomography. *Urol Int* 1999;63(2):147-50.
<http://www.ncbi.nlm.nih.gov/pubmed/10592508>
5. Plaire JC, Pope JC 4th, Kropp BP, Adams MC, Keating MA, Rink RC, Casale AJ. Management of ectopic ureters: experience with the upper tract approach. *J Urol* 1997;158(3 Pt 2):1245-7.
<http://www.ncbi.nlm.nih.gov/pubmed/9258185>
6. Robert M, Ennouchi JM, Chevallier P, Guiter J, Averous M. [Diagnosis of ectopic ureteral openings in the seminal tract. Value of modern imaging.] *Progr Urol* 1993;3(6):1028-33. [article in French]
<http://www.ncbi.nlm.nih.gov/pubmed/8305932>
7. Smith FL, Ritchie EL, Maizels M, Zaontz MR, Hsueh W, Kaplan WE, Firlit CF. Surgery for duplex kidneys with ectopic ureters: ipsilateral ureteroureterectomy versus polar nephrectomy. *J Urol* 1989;142:532-4.
<http://www.ncbi.nlm.nih.gov/pubmed/2746774>
8. Sumfest JM, Burns MW, Mitchell ME. Pseudoureterocele: potential for misdiagnosis of an ectopic ureter as a ureterocele. *Br J Urol* 1995;75:401-5.
<http://www.ncbi.nlm.nih.gov/pubmed/7735809>

17. DISORDERS OF SEX DEVELOPMENT

17.1 Background

The formerly called 'intersex disorders' were recently the subject of a consensus document in which it was decided that the term 'intersex' should be changed to 'disorders of sex development' (DSD) (1, 2).

The new classification has arisen because of advances in knowledge of the molecular genetic causes of abnormal sexual development, controversies inherent to clinical management and ethical issues. Controversial and pejorative terminology, e.g. 'pseudohermaphroditism' and 'hermaphroditism', have been renamed according to the new pathophysiological insights. Furthermore, some conditions presenting with severe male genital malformation, such as penile agenesis, cloacal exstrophy, which could not be categorized, have also been included. The term 'disorders of sex development' is proposed to indicate congenital conditions with atypical development of chromosomal, gonadal or anatomical sex.

We refer to the consensus document as a general guideline, while this chapter will focus on what is

relevant for the practising paediatric urologist. As the urologist is likely to be involved in both surgical and non-surgical neonatal work, this chapter will discuss the neonatal emergency and the diagnostic and therapeutic role of the paediatric urologist.

Overall, there is a low evidence base for the published literature on DSD. There are no randomized controlled trials and most studies are based on retrospective clinical descriptive studies (grade 4 level of evidence) or are expert opinion. An exception is the risk of gonadal cancer, for which the level of evidence is higher.

Disorders of sex development require a multidisciplinary approach to diagnosis and treatment, which should include geneticists, neonatologists, paediatric and adult endocrinologists, gynaecologists, psychologists, ethicists and social workers. Each team member should be specialised in DSD and a team should have enough new patients to ensure experience.

17.2 The neonatal emergency

The first step is to recognize the possibility of DSD (Table 4) and to refer the newborn baby immediately to a tertiary paediatric centre, fully equipped with neonatal, genetics, endocrinology and paediatric urology units. At the paediatric centre, the situation should be explained to the parents fully and kindly. Registering and naming the newborn should be delayed as long as necessary.

17.2.1 Family history and clinical examination

A careful family history must be taken followed by a thorough clinical examination (Table 5).

Table 4: Findings in a newborn suggesting the possibility of DSD (adapted from the American Academy of Pediatrics)

- **Apparent male**
 - Severe hypospadias associated with bifid scrotum
 - Undescended testis/testes with hypospadias
 - Bilateral non-palpable testes in a full-term apparently male infant
- **Apparent female**
 - Clitoral hypertrophy of any degree, non-palpable gonads
 - Vulva with single opening
- **Indeterminate**
 - Ambiguous genitalia

Table 5: Diagnostic work-up of neonates with ambiguous genitalia

- History (family, maternal, neonatal)**
- Parental consanguinity
 - Previous DSD or genital anomalies
 - Previous neonatal deaths
 - Primary amenorrhoea or infertility in other family members
 - Maternal exposure to androgens
 - Failure to thrive, vomiting, diarrhoea of the neonate
- Physical examination**
- Pigmentation of genital and areolar area
 - Hypospadias or urogenital sinus
 - Size of phallus
 - Palpable and/or symmetrical gonads
 - Blood pressure
- Investigations**
- Blood analysis: 17-hydroxyprogesterone, electrolytes, LH, FSH, TST, cortisol, ACTH
 - Urine: adrenal steroids
 - Karyotype
 - Ultrasound
 - Genitogram
 - hCG stimulation test
 - Androgen-binding studies
 - Endoscopy

LH = luteinizing hormone; FSH = follicle stimulating hormone; TST = testosterone; ACTH = adrenocorticotropic hormone; hCG = human chorionic gonadotrophin.

17.2.2 Choice of laboratory investigations

The following laboratory investigations are mandatory:

- Karyotype
- Plasma 17-hydroxyprogesterone assay
- Plasma electrolytes
- Ultrasonography to evaluate the presence of Müllerian duct structures.

These investigations will provide evidence of congenital adrenal hyperplasia (CAH), which is the most frequently occurring DSD. If this evidence is found, no further investigation is needed. If not, then the laboratory work-up should proceed further.

The hCG stimulation test is particularly helpful in differentiating the main syndromes of 46XYDSD by evaluating Leydig cell potential. When testosterone metabolism is evaluated, the presence or absence of metabolites will help to define the problem. An extended stimulation can help to define phallic growth potential and to induce testicular descent in some cases of associated cryptorchidism.

17.3 Gender assignment

This is a very complicated task. It should take place after a definitive diagnosis has been made. The idea that an individual is sex-neutral at birth and that rearing determines gender development is no longer the standard approach. Instead, gender assignment decisions should be based upon:

- Age at presentation
- Fertility potential
- Size of the penis
- Presence of a functional vagina
- Endocrine function
- Malignancy potential
- Antenatal testosterone exposure
- General appearance
- Psychosocial well-being and a stable gender identity.

Each patient presenting with DSD should be assigned a gender as quickly as a thorough diagnostic evaluation permits.

17.4 Role of the paediatric urologist

The role of the paediatric urologist can be divided into a diagnostic role and a therapeutic role (Table 6). Each of these roles will be discussed briefly.

Table 6: Role of the paediatric urologist

<i>Diagnostic role</i>
<ul style="list-style-type: none">• Clinical examination• Ultrasound• Genitography• Cystoscopy• Diagnostic laparoscopy
<i>Therapeutic role</i>
<ul style="list-style-type: none">• Masculinizing surgery• Feminizing surgery• Gonadectomy

17.4.1 Diagnosis

17.4.1.1 Clinical examination

A good clinical examination in a neonate presenting with ambiguous genitalia is important. As well as a good description of the ambiguous genitalia, some detailed information should be given on palpability and localization of the gonads. Information gathered by the various examinations described below should help the team to come to a final diagnosis.

Palpable gonad. It must be remembered that if it is possible to feel a gonad, it is almost certainly a testis; this clinical finding therefore virtually excludes 46XXDSD.

Medical photography can be useful but requires sensitivity and consent (3).

Phallus. The phallus should be measured. A cotton bud placed at the suprapubic base of the implant of the

stretched phallus allows for a good measurement of phallic length.

Urogenital sinus opening. The opening of the urogenital sinus must be well evaluated. Is there only one opening visible? Can a hymenal ring be seen? What does the fusion of the labioscrotal folds look like; do the folds show rugae or some discolouration?

17.4.1.2 Investigations

Ultrasound can help to describe the palpated gonads or to detect non-palpated gonads. However, the sensitivity and specificity are not high. On ultrasound, the Müllerian structures can be evaluated. Is there a vagina? Are there some abdominal gonads? Is there a vaginal or utricular structure visible? (4,5).

Genitography can provide some more information on the urogenital sinus. How low or how high is the confluence? Is there any duplication of the vagina? How does the urethra relate to the vagina?

General anaesthesia. In some cases, further examinations under general anaesthesia can be helpful. On cystoscopy, the urogenital sinus can be evaluated and the level of confluence between the bladder neck and the bladder. Cystoscopy can also be used to evaluate the vagina or utriculus, e.g. the presence of a cervix at the top of the vagina can be important information.

Laparoscopy is necessary to obtain a final diagnosis on the presence of impalpable gonads and on the presence of Müllerian structures. If indicated, a gonadal biopsy can be performed (6,7).

17.5 Management

Referring to the consensus document (1, 2), it is clear that the timing of surgery is much more controversial than it used to be.

The rationale for early surgery includes:

- Beneficial effects of oestrogen on infant tissue
- Avoiding complications from anatomical anomalies
- Minimizing family distress
- Mitigating the risks of stigmatization and gender-identity confusion (8).

However, adverse outcomes have led to recommendations to delay unnecessary surgery to an age when the patient can give informed consent. Surgery that alters appearance is not urgent. Early surgery should be reserved for those patients with high confluent urogenital tracts, girls with severely masculinized genitalia and boys with undervirilized genitals. Vaginoplasty should be delayed until puberty and milder forms of masculinization should not be treated surgically.

17.5.1 Feminizing surgery

Clitororeduction. Reduction of an enlarged clitoris should be done with preservation of the neurovascular bundle. Clitoral surgery has been reported to have an adverse outcome on sexual function and clitoral surgery should therefore be limited to severely enlarged clitorises (9,10). Informed parental consent should be obtained. Although some techniques that conserve erectile tissue have been described, the long-term outcome is unknown (11).

Separation of the vagina and the urethra is preserved for high confluence anomalies. Many techniques for urogenital sinus repair have been described, but their outcome has not been evaluated prospectively (12, 13).

Vaginoplasty should be performed during the teenage years. Every technique (self dilatation, skin or bowel substitution) has its specific advantages and disadvantages (14). All carry a potential for scarring that would require further surgery before sexual function was possible.

Aesthetic refinements. The goals of genital surgery are to maximize anatomy to allow sexual function and romantic partnering. Aesthetics are important in this perspective. The reconstruction of minor labiae from an enlarged clitoral hood is an example of aesthetic refinement.

17.5.2 Masculinizing surgery

Hormone therapy early in life is advocated by many doctors. The level of evidence is low for restoration of normal penile size.

Hypospadias surgery. See section on hypospadias (Chapter 6).

Excision of Mullerian structures. In the DSD patient assigned a male gender, Müllerian structures should be excised. There is no evidence about whether utricular cysts need to be excised.

Orchiopexy. See section on orchidopexy (Chapter 3).

Phalloplasty. The increasing experience of phalloplasty in the treatment of female to male transsexual patients has led to reports about the reliability and feasibility of this technique. It has therefore become available to treat severe penile inadequacy in DSD patients.

Aesthetic refinements. These include correction of penoscrotal transposition, scrotoplasty and insertion of testicular prostheses.

Gonadectomy. Germ cell malignancy only occurs in patients with DSD who have Y-chromosomal material. The highest risk is seen in patients with gonadal dysgenesis and in patients with partial androgen insensitivity with intra-abdominal gonads (Level of evidence: 2). Intra-abdominal gonads of high-risk patients should be removed at the time of diagnosis (Grade of recommendation: A) (15).

17.6 REFERENCES

1. Lee PA, Houk CP, Ahmed SF, Hughes IA; International Consensus Conference on Intersex organized by the Lawson Wilkins Pediatric Endocrine Society and the European Society for Paediatric Endocrinology. Consensus statement on management of intersex disorders. *International Consensus Conference on Intersex. Pediatrics* 2006;118(2):e488-e500.
<http://www.ncbi.nlm.nih.gov/pubmed/16882788>
2. Houk CP, Hughes IA, Ahmed SF, Lee PA; Writing Committee for the International Intersex Consensus Conference Participants. Summary of consensus statement on intersex disorders and their management. *International Intersex Consensus Conference. Pediatrics* 2006;118(2):753-7.
<http://www.ncbi.nlm.nih.gov/pubmed/16882833>
3. Creighton S, Alderson J, Brown S, Minto CL. Medical photography: ethics, consent and the intersex patient. *BJU Int* 2002;89(1):67-1; discussion 71-2.
<http://www.ncbi.nlm.nih.gov/pubmed/11849163>
4. Biswas K, Kapoor A, Karak AK, Kriplani A, Gupta DK, Kucheria K, Ammini A. Imaging in intersex disorders. *J Pediatr Endocrinol Metab* 2004;17(6):841-5.
<http://www.ncbi.nlm.nih.gov/pubmed/15270401>
5. Wright NB, Smith C, Rickwood AM, Carty HM. Imaging children with ambiguous genitalia and intersex states. *Clin Radiol* 1995;50(12): 823-9.
<http://www.ncbi.nlm.nih.gov/pubmed/8536391>
6. Chertin B, Koulikov D, Alberton J, Hadas-Halpern I, Reissman P, Farkas A. The use of laparoscopy in intersex patients. *Pediatr Surg Int* 2006;22(5):405-8.
<http://www.ncbi.nlm.nih.gov/pubmed/16521001>
7. Denes FT, Mendonca BB, Arap S. Laparoscopic management of intersexual states. *Urol Clin North Am* 2001;28(1):31-42.
<http://www.ncbi.nlm.nih.gov/pubmed/11277066>
8. [No authors listed] Timing of elective surgery on the genitalia of male children with particular reference to the risks, benefits, and psychological effects of surgery and anesthesia. *American Academy of Pediatrics. Pediatrics* 1996;97(4):590-4.
<http://www.ncbi.nlm.nih.gov/pubmed/8632952>
9. Creighton SM. Adult female outcomes of feminising surgery for ambiguous genitalia. *Pediatr Endocrinol Rev* 2004;2(2):199-202.
<http://www.ncbi.nlm.nih.gov/pubmed/16429106>
10. Minto CL, Liao LM, Woodhouse CR, Ransley PG, Creighton SM. The effect of clitoral surgery on sexual outcome in individuals who have intersex conditions with ambiguous genitalia: a cross-sectional study. *Lancet* 2003;361(9365):1252-7.
<http://www.ncbi.nlm.nih.gov/pubmed/12699952>
11. Crouch NS, Creighton SM. Minimal surgical intervention in the management of intersex conditions. *J Pediatr Endocrinol Metab* 2004;17(12):1591-6.
<http://www.ncbi.nlm.nih.gov/pubmed/15645692>
12. Jenak R, Ludwikowski B, Gonzalez R. Total urogenital sinus mobilization: a modified perineal approach for feminizing genitoplasty and urogenital sinus repair. *J Urol* 2001;165(6 Pt 2):2347-9.
<http://www.ncbi.nlm.nih.gov/pubmed/11371975>

13. Leclair MD, Gundetti M, Kiely EM, Wilcox DT. The surgical outcome of total urogenital mobilization for cloacal repair. *J Urol* 2007;177(4):1492-5.
<http://www.ncbi.nlm.nih.gov/pubmed/17382761>
14. Schober JM. Feminizing genitoplasty: a synopsis of issues relating to genital surgery in intersex individuals. *J Pediatr Endocrinol Metab* 2004;17(5):697-703.
<http://www.ncbi.nlm.nih.gov/pubmed/15237702>
15. Cools M, Drop SL, Wolffenbuttel KP, Oosterhuis JW, Looijenga LH. Germ cell tumors in the intersex gonad: old paths, new directions, moving frontiers. *Endocr Rev* 2006;27(5):468-84.
<http://www.ncbi.nlm.nih.gov/pubmed/16735607>

18. POSTERIOR URETHRAL VALVES

18.1 Background

Posterior urethral valves (PUV) are one of the few life-threatening congenital anomalies of the urinary tract found during the neonatal period. Despite optimal treatment, PUV in children may result in renal insufficiency in nearly 35% of cases. PUV are found in 1 in 1,250 in a population undergoing fetal ultrasound screening (1). An incidence of PUV of 1 in 5,000-12,500 live-births has been estimated (2, 3). In one report, up to 46% of fetuses with a PUV diagnosis were terminated (4), indicating a possible decrease in incidence.

18.2 Classification

18.2.1 Urethral valve

Despite recent attempts to introduce new classification terms, such as 'congenital obstructive posterior urethral membrane (COPUM)' (5), the original classification by Hugh Hampton Young remains the most commonly used (6).

Hampton Young described three categories: type I, type II and type III. However, today, only type I and type III are found to be obstructive. As type II seems to be more like a fold and not obstructive, it is no longer referred to as a valve. Hampton Young's descriptions of type I and II are as follows:

Type I (90-95%). 'In the most common type there is a ridge lying on the floor of the urethra, continuous with the verumontanum, which takes an anterior course and divides into two fork-like processes in the region of the bulbo-membranous junction. These processes are continued as thin membranous sheets, direct upward and forward which may be attached to the urethra throughout its entire circumference. It is generally supposed that the valves have complete fusion anteriorly, leaving only an open channel at the posterior urethral wall. Yet the fusion of the valves anteriorly may not be complete in all cases, and at this point a slight separation of the folds exist.' (6)

Type III. 'There is a third type of which has been found at different levels of the posterior urethra and which apparently bears no such relation to the verumontanum. This obstruction was attached to the entire circumference of the urethra, with a small opening in the centre.' (6).

The transverse membrane described has been attributed to incomplete dissolution from the urogenital portion of the cloacal membrane (7). The embryology of the urethral valves is poorly understood. The membrane may be an abnormal insertion of the mesonephric ducts into the fetal cloaca (8).

18.3 Diagnosis

An obstruction above the level of the urethra affects the whole urinary tract in varying degrees.

- The prostatic urethra is distended and the ejaculatory ducts may be dilated due to urinary reflux. The bladder neck is hypertrophied and rigid.
 - The hypertrophied bladder occasionally has multiple diverticula.
 - Nearly all valve patients have dilatation of both upper urinary tracts. This may be due to the valve itself and the high pressure in the bladder, or due to obstruction of the ureterovesical junction by the hypertrophied bladder.
 - If there is secondary reflux, the affected kidney functions poorly in most cases.
- During prenatal ultrasonography screening, bilateral hydronephrosis and a distended bladder are suspicious signs of a urethral valve. If a dilated posterior urethra and a thick-walled bladder ('keyhole' sign) are seen, a PUV is likely. In the presence of increased echogenicity of the kidney, dilatation of the urinary tract and oligohydramnion, the diagnosis of a PUV should strongly be considered.

A voiding cysturethrography (VCUG) confirms a PUV diagnosis. This study is essential whenever there is a question of an infravesical obstruction, as the urethral anatomy is well outlined during voiding. A secondary reflux is observed in at least 50% of patients with PUV (9). Reflux is consistently associated with renal dysplasia in patients with PUV. It is generally accepted that reflux in the renal units acts as a 'pressure pop-off valve', which would protect the other kidney, leading to a better prognosis (10). Other types of pop-off mechanism include bladder diverticula and urinary extravasation, with or without urinary ascites (11). However, in the long-term, a supposed protective effect did not show a significant difference compared to other patients with PUV (12, 13).

Nuclear renography with split renal function is important to assess kidney function. Creatinine, blood urea nitrogen and electrolytes should be monitored closely during the first few days. A nadir creatinine of 80 $\mu\text{mol/L}$ is correlated with a better prognosis (14).

18.4 Treatment

18.4.1 Antenatal treatment

About 40-60% of PUV are discovered before birth (15). The intrauterine obstruction leads to a decreased urine output, which could result in an oligohydramnios. Amnion fluid is necessary for normal development of the lung and its absence may lead to pulmonary hypoplasia, causing a life-threatening problem. Intrauterine attempts have been made to treat a fetus with PUV.

As renal dysplasia is not reversible, it is important to identify those fetuses with good renal function. A sodium level below 100 mmol/L, a chloride value of < 90mmol/L and an osmolarity below 200 mOsm/L found in three fetal urine samples gained on three different days are associated with a better prognosis (16).

The placing of a vesicoamniotic shunt has a complication rate of 21-59%, dislocation of the shunt occurs in up to 44%, mortality lies between 33% and 43%, and renal insufficiency is above 50% (16-18). Although shunting is effective in reversing oligohydramnios, it makes no difference to the outcome and long-term results of patients with PUV (17, 18).

18.4.2 Postnatal treatment

Bladder drainage. If a boy is born with suspected PUV, drainage of the bladder and, if possible, an immediate VCUG is necessary. A neonate can be catheterized with a 3.5-5 F catheter. A VCUG is performed to see if the diagnosis is correct and whether the catheter is within the bladder and not in the posterior urethra. An alternative option is to place a suprapubic catheter, perform a VCUG and leave the tube until the neonate is stable enough to perform an endoscopic incision or resection of the valve.

Valve ablation. When the medical situation of the neonate has stabilized and the creatinine level decreased, the next step is to remove the intravesical obstruction. Small paediatric cystoscopes and resectoscopes are now available either to incise or to resect the valve at the 4-5, 7-8 or 12 o'clock position, or at all three positions, depending on the surgeon's preference. It is important to avoid extensive electrocoagulation as the most common complication of this procedure is stricture formation.

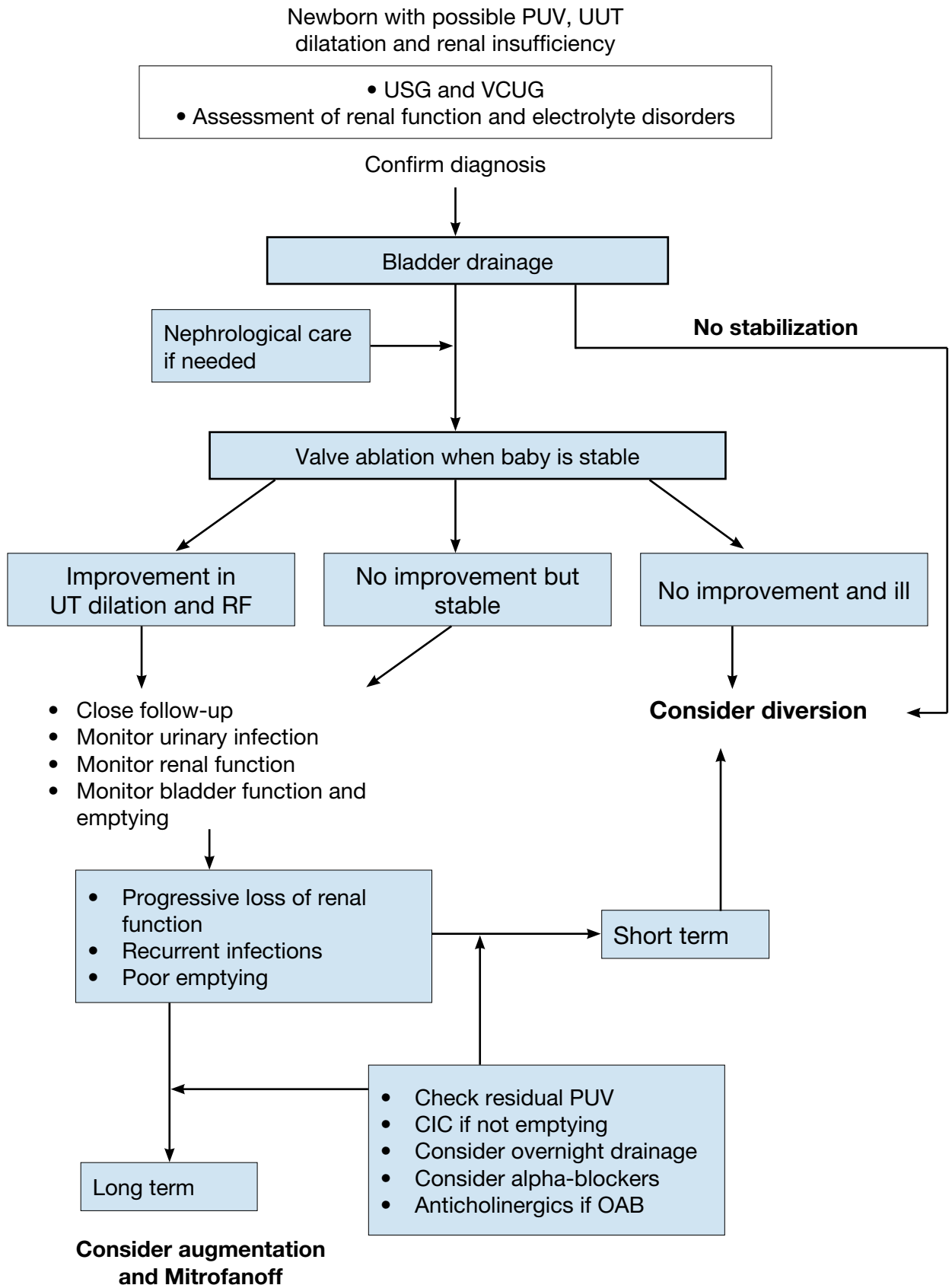
Vesicostomy. If the child is too small and/or too ill to undergo endoscopic surgery, a vesicostomy is used to drain the bladder temporarily. If initially a suprapubic tube has been inserted, this can be left in place for 6-12 weeks. Otherwise, a cutaneous vesicostomy provides an improvement or stabilization of upper urinary tracts in over 90% of cases (19). Although there has been concern that a vesicostomy could decrease bladder compliance or capacity, so far there are no valid data to support these expectations (20-22).

High diversion. If bladder drainage is insufficient to drain the upper urinary tract, high urinary diversion should be considered. Diversion may be suitable if there are recurrent infections of the upper tract, no improvement in renal function and/or an increase in upper tract dilatation, despite adequate bladder drainage. The choice of urinary diversion depends on the surgeon's preference for high loop ureterostomy, ring ureterostomy, end ureterostomy or pyelostomy, with each technique having advantages and disadvantages (23-25). Reconstructive surgery should be delayed until the upper urinary tract has improved as much as can be expected.

Reflux is very common in PUV patients (up to 72%) and it is described bilaterally in up to 32% (26). High-grade reflux is mostly associated with a poor functioning kidney. However, early removal of the renal unit seems to be unnecessary, as long as it causes no problems. It may be necessary to augment the bladder and in this case the ureter may be used (27).

Life-long monitoring of these patients is mandatory, as bladder dysfunction is not uncommon and the delay in day- and night-time continence is a major problem (9, 14). Poor bladder sensation and compliance, detrusor instability and polyuria (especially at night) and their combination are responsible for bladder dysfunction. Between 10% and 47% of patients may develop end-stage renal failure (14, 28). Renal

Figure 4. An algorithm providing information on assessment, treatment and follow up of newborns with possible PUV



PUV = posterior urethral valve; UUT = upper urinary tract; USG = urinary specific gravity; VCUG = voiding cystourethrogram; UT = urinary tract; RF = renal function; CIC = clean intermittent catheterization; OAB = overactive bladder.

transplantation in these patients can be performed safely and effectively. Deterioration of the graft function is mainly related to lower urinary tract dysfunction (29, 30).

18.5 References

1. Gunn TR, Mora JD, Pease P. Antenatal diagnosis of urinary tract abnormalities by ultrasonography after 28 weeks' gestation: incidence and outcome. *Am J Obstet Gynecol* 1995;172(2 Pt 1):479-86. <http://www.ncbi.nlm.nih.gov/pubmed/7856673>
2. Atwell JD. Posterior urethral valves in the British Isles: a multicenter BAPS review. *J Pediatr Surg* 1983;18(1):70-4. <http://www.ncbi.nlm.nih.gov/pubmed/6834230>
3. Casale AJ. Early ureteral surgery for posterior urethral valves. *Urol Clin North Am* 1990;17(2):361-72. <http://www.ncbi.nlm.nih.gov/pubmed/2186541>
4. Cromie WJ, Lee K, Houde K, Holmes L. Implications of prenatal ultrasound screening in the incidence of major genitourinary malformations. *J Urol* 2001;165(5):1677-80. <http://www.ncbi.nlm.nih.gov/pubmed/11342955>
5. Dewan PA, Zappala SM, Ransley PG, Duffy PG. Endoscopic reappraisal of the morphology of congenital obstruction of the posterior urethra. *Br J Urol* 1992;70(4):439-44. <http://www.ncbi.nlm.nih.gov/pubmed/1450856>
6. Young HH, Frontz WA, Baldwin JC. Congenital obstruction of the posterior urethra. *J Urol* 1919;3: 289-365. <http://www.ncbi.nlm.nih.gov/pubmed/11743334>
7. Rosenfeld B, Greenfield SP, Springate JE, Feld LG. Type III posterior urethral valves: presentation and management. *J Pediatr Surg* 1994;29(1):81-5. <http://www.ncbi.nlm.nih.gov/pubmed/8120770>
8. Stephens FD, Gupta D. Pathogenesis of the prune belly syndrome. *J Urol* 1994;152(6 Pt 2):2328-31. <http://www.ncbi.nlm.nih.gov/pubmed/8120770>
9. Churchill BM, McLorie GA, Khoury AE, Merguerian PA, Houle AM. Emergency treatment and long-term follow-up of posterior urethral valves. *Urol Clin North Am* 1990;17(2):343-60. <http://www.ncbi.nlm.nih.gov/pubmed/2186540>
10. Hoover DL, Duckett JW Jr. Posterior urethral valves, unilateral reflux and renal dysplasia: a syndrome. *J Urol* 1982;128(5):994-7. <http://www.ncbi.nlm.nih.gov/pubmed/7176067>
11. Rittenberg MH, Hulbert WC, Snyder HM 3rd, Duckett JW. Protective factors in posterior urethral valves. *J Urol* 1988;140(5):993-6. <http://www.ncbi.nlm.nih.gov/pubmed/3139895>
12. Cuckow PM, Dinneen MD, Risdon RA, Ransley PG, Duffy PG. Long-term renal function in the posterior urethral valves, unilateral reflux and renal dysplasia syndrome. *J Urol* 1997;158(3 Pt 2): 1004-7. <http://www.ncbi.nlm.nih.gov/pubmed/9258130>
13. Kleppe S, Schmitt J, Geipel A, Gembruch U, Hansmann M, Bartmann P, Franke I, Heep A. Impact of prenatal urinomas in patients with posterior urethral valves and postnatal renal function. *J Perinat Med* 2006;34(5):425-8. <http://www.ncbi.nlm.nih.gov/pubmed/16965232>
14. Smith GH, Canning DA, Schulman SL, Snyder HM 3rd, Duckett JW. The long-term outcome of posterior urethral valves treated with primary valve ablation and observation. *J Urol* 1996;155(5): 1730-4. <http://www.ncbi.nlm.nih.gov/pubmed/8627873>
15. Dinneen MD, Dhillon HK, Ward HC, Duffy PG, Ransley PG. Antenatal diagnosis of posterior urethral valves. *Br J Urol* 1993;72(3):364-9. <http://www.ncbi.nlm.nih.gov/pubmed/8220998>
16. Freedman AL, Johnson MP, Gonzalez R. Fetal therapy for obstructive uropathy: past, present, future? *Pediatr Nephrol* 2000;14(2):167-76. <http://www.ncbi.nlm.nih.gov/pubmed/10684370>
17. McLorie G, Farhat W, Khoury A, Geary D, Ryan G. Outcome analysis of vesicoamniotic shunting in a comprehensive population. *J Urol* 2001;166(3):1036-40. <http://www.ncbi.nlm.nih.gov/pubmed/11490292>
18. Salam MA. Posterior urethral valve: outcome of antenatal intervention. *Int J Urol* 2006;13(10):1317-22. <http://www.ncbi.nlm.nih.gov/pubmed/17010011>

19. Krahn CG, Johnson HW. Cutaneous vesicostomy in the young child: indications and results. *Urology* 1993;41(6):558-63.
<http://www.ncbi.nlm.nih.gov/pubmed/8516992>
20. Kim YH, Horowitz M, Combs A, Nitti VW, Libretti D, Glassberg KI. Comparative urodynamic findings after primary valve ablation, vesicostomy or proximal diversion. *J Urol* 1996;156(2 Pt 2):673-6.
<http://www.ncbi.nlm.nih.gov/pubmed/8683757>
21. Podesta M, Ruarte AC, Gargiulo C, Medel R, Castera R, Herrera M, Levitt SB, Weiser A. Bladder function associated with posterior urethral valves after primary valve ablation or proximal urinary diversion in children and adolescents. *J Urol* 2002;168(4 Pt 2):1830-5; discussion 1835.
<http://www.ncbi.nlm.nih.gov/pubmed/12352370>
22. Jayanthi VR, McLorie GA, Khoury AE, Churchill BM. The effect of temporary cutaneous diversion on ultimate bladder function. *J Urol* 1995;154(2 Pt 2):889-92.
<http://www.ncbi.nlm.nih.gov/pubmed/7609206>
23. Novak ME, Gonzales ET Jr. Single-stage reconstruction of urinary tract after loop cutaneous ureterostomy. *Urology* 1978;11(2):134-8.
<http://www.ncbi.nlm.nih.gov/pubmed/628990>
24. Sober I. Pelvioureterostomy-en-Y. *J Urol* 1972;107(3):473-5.
<http://www.ncbi.nlm.nih.gov/pubmed/5010719>
25. Williams DI, Cromie WJ. Ring ureterostomy. *Br J Urol* 1975;47(7):789-92.
<http://www.ncbi.nlm.nih.gov/pubmed/1222345>
26. Scott JE. Management of congenital posterior urethral valves. *Br J Urol* 1985;57(1):71-7.
<http://www.ncbi.nlm.nih.gov/pubmed/3971107>
27. Bellinger MF. Ureterocystoplasty: a unique method for vesical augmentation in children. *J Urol* 1993;149(4):811-3.
<http://www.ncbi.nlm.nih.gov/pubmed/8455246>
28. Reinberg Y, de Castano I, Gonzalez R. Influence of initial therapy on progression of renal failure and body growth in children with posterior urethral valves. *J Urol* 1992;148(2 Pt 2):532-3.
<http://www.ncbi.nlm.nih.gov/pubmed/1640516>
29. DeFoor W, Tackett L, Minevich E, McEnery P, Kitchens D, Reeves D, Sheldon C. Successful renal transplantation in children with posterior urethral valves. *J Urol* 2003;170(6 Pt 1):2402-4.
<http://www.ncbi.nlm.nih.gov/pubmed/14634437>
30. Salomon L, Fontaine E, Guest G, Gagnadoux MF, Broyer M, Beurton D. Role of the bladder in delayed failure of kidney transplants in boys with posterior urethral valves. *J Urol* 2000;163(4):1282-5.
<http://www.ncbi.nlm.nih.gov/pubmed/10737529>

19. ABBREVIATIONS USED IN THE TEXT

This list is not comprehensive for the most common abbreviations

AGS	adrenogenital syndrome
ACTH	adrenocorticotrophic hormone
AMH	anti-Müllerian hormone
ARM	anorectal malformation
CAH	congenital adrenal hyperplasia
CIC	clean self-intermittent catheterization
CNS	central nervous system
COPUM	congenital obstructive posterior urethral membrane
CRP	C-reactive protein
DDAVP	desmopressine
CT	computed tomography
DHTST	dihydrotestosterone
DMSA	dimercaptosuccinic acid
EMG	electromyography
ESR	erythrocyte sedimentation rate
ESWL	extracorporeal shockwave lithotripsy
FSH	follicle stimulating hormone
GnRH	gonadotrophin-releasing hormone
hCG	human chorionic gonadotrophin
IC	intermittent catheterisation
ICCS	International Children's Continence Society
IVU	intravenous urogram
LH	luteinizing hormone
LHRH	luteinizing hormone releasing hormone
LUT(S)	lower urinary tract (symptoms)
MRI	magnetic resonance imaging
NDS	neurogenic detrusor-sphincter dysfunction
OAB	overactive bladder
PNL	percutaneous litholapaxy
RCT	randomized controlled treatment trials
RN	reflux nephropathy
RNC	radionuclide cystography
RTA	renal tubular acidosis
Tc-MAG3 (99m)	technetium-99m mercaptoacetyltriglycine (MAG3)
TIP	tubularized incised urethral plate
TST	testosterone
UPJ	ureteropelvic junction
URS	ureterorenoscopy
US	ultrasound
UTIs	urinary tract infections
VCUG	voiding cystourethrography
VRR	vesicorenal reflux
VUR	vesicoureteral reflux
VUS	voiding urosonography

Conflict of interest

All members of the Paediatric Urology Guidelines writing panel have provided disclosure statements on all relationships that they have and that might be perceived to be a potential source of conflict of interest. This information is kept on file in the European Association of Urology Central Office database. This guidelines document was developed with the financial support of the European Association of Urology. No external sources of funding and support have been involved. The EAU is a non-profit organisation and funding is limited to administrative assistance and travel and meeting expenses. No honoraria or other reimbursements have been provided.